

# Opportunistic Infections: Treatment

This is a PDF version of the following document:

Module 4: [Co-Occurring Conditions](#)

Lesson 3: [Opportunistic Infections: Treatment](#)

You can always find the most up-to-date version of this document at

<https://www.hiv.uw.edu/go/co-occurring-conditions/opportunistic-infections-treatment/core-concept/all>.

---

## Background

The introduction of effective antiretroviral therapy in the mid-1990s played a major role in the dramatic reduction in opportunistic infection-related morbidity and mortality.[1,2,3] Despite the widespread availability and use of potent antiretroviral therapy, individuals with HIV continue to suffer significant morbidity and mortality from opportunistic infections, defined as infections that are more frequent or severe due to immunosuppression. Most opportunistic infections now occur in people with undiagnosed HIV or in persons diagnosed with HIV who are not engaged in care. Because opportunistic infections continue to occur with potentially devastating consequences, clinicians should have a core understanding of the diagnosis, prevention, and treatment of opportunistic infections. This topic review provides an overview of treatment for the most common opportunistic infections based on the Adult and Adolescent OI Guidelines.[4]

## Immune Reconstitution Syndrome

After initiation of effective antiretroviral therapy and during the early phases of immune reconstitution, a paradoxical worsening of certain clinical conditions can occur; this has been termed immune reconstitution inflammatory syndrome (IRIS).[5,6] Similarly, some patients with profound immunosuppression may have undiagnosed opportunistic infections that may be exposed as a result of an immune upregulation after starting antiretroviral therapy. This has been referred to as “unmasking” IRIS, a process whereby the immune system regains the capacity to recognize antigens and pathogens that previously it was too suppressed to confront. Although IRIS may develop in the context of various infections and/or AIDS-associated malignancies in patients with advanced HIV disease, the most commonly observed IRIS events involve disseminated *Mycobacterium avium* complex disease, cryptococcal meningitis, tuberculosis, progressive multifocal leukoencephalopathy, and cytomegalovirus retinitis.[7,8,9]

## ***Pneumocystis* Pneumonia**

*Pneumocystis* pneumonia (PCP) is a leading cause of morbidity and mortality in people with HIV. The causative organism, *Pneumocystis jirovecii*, is classified as a fungus and was previously known as *P. carinii*.[\[10\]](#) Despite the organism name change, the acronym PCP is still widely used to denote *Pneumocystis* pneumonia. Individuals with HIV most often acquire *P. jirovecii* via the airborne route, and disease may occur either through a newly acquired infection or by reactivation of latent infection.[\[10\]](#) The risk of developing *Pneumocystis* pneumonia increases markedly when the CD4 count drops below 200 cells/mm<sup>3</sup>.[\[11,12,13\]](#) After the use of effective antiretroviral therapy became widespread, the incidence of *Pneumocystis* pneumonia dropped substantially.[\[1,2\]](#)

### **Clinical Manifestations**

The most common clinical manifestations in patients with *Pneumocystis* pneumonia are a subacute nonproductive cough, progressive dyspnea (particularly dyspnea on exertion), and fever.[\[13,14\]](#) The pulmonary physical examination is usually normal, but in more advanced disease, rales may be present on auscultation. If untreated, individuals with *Pneumocystis* pneumonia may have progression of clinical disease with worsening dyspnea and hypoxemic respiratory failure.

### **Diagnosis**

All persons with suspected *Pneumocystis* pneumonia should undergo evaluation to confirm the diagnosis. Nondefinitive tests can be used to support the diagnosis, but all persons with suspected *Pneumocystis* pneumonia should have a definitive diagnosis made.[\[14,15\]](#)

#### **Nondefinitive Diagnostic Tests**

The diagnosis of *Pneumocystis* pneumonia can be supported by several nonspecific tests.

- **Chest Radiography and Chest Computed Tomography:** In patients with suspected *Pneumocystis* pneumonia, chest imaging is almost always performed ([Figure 1](#)). In patients with *Pneumocystis* pneumonia, chest radiograph typically shows diffuse bilateral perihilar infiltrates; the appearance of these infiltrates is often described as ground glass and butterfly-shaped.[\[16,17\]](#) Approximately 15 to 20% of persons with *Pneumocystis* pneumonia have a normal chest radiograph, particularly those in the earlier phase of *Pneumocystis* pneumonia.[\[13,17,18\]](#) In some individuals with *Pneumocystis* pneumonia, pneumatoceles or cystic lesions develop; these may result in pneumothorax.[\[19,20\]](#) High-resolution chest computed tomography is more sensitive than chest radiography in detecting interstitial abnormalities.[\[16,21\]](#)
- **Exercise Pulse Oximetry:** Oxygen desaturation with exercise, as documented with continuous pulse oximetry, has been shown to be a feature of most persons with *Pneumocystis* pneumonia.[\[22\]](#)
- **Laboratory Studies:** Nonspecific laboratory findings that may support the diagnosis of *Pneumocystis* pneumonia include lactate dehydrogenase (LDH) greater than 500 mg/dL and a 1,3-beta-D-glucan level of 80 pg/mL or greater; the 1,3-beta-D-glucan is used for testing because it is a major component of the *P. jirovecii* cell wall.[\[23,24,25\]](#) Although the sensitivity of the beta-D-glucan test is high, the specificity is low because persons with HIV who have advanced immunosuppression are at risk for multiple other fungal pathogens that can also cause elevated beta-D-glucan levels.[\[25\]](#)

#### **Definitive Diagnostic Tests**

A definitive diagnosis of *Pneumocystis* pneumonia requires detection of organisms in respiratory secretions or tissue.[\[13,26\]](#) Several tests play a role in the definitive diagnosis of *Pneumocystis* pneumonia.

- **Induced Sputum:** An induced sputum sample using an ultrasonic saline nebulizer has a sensitivity for

diagnosing *Pneumocystis* pneumonia that ranges from 50 to 90%, assuming the medical facility has experience with performing this test.[13,26] Expecterated sputum should not be submitted for diagnosis of *Pneumocystis* pneumonia due to low sensitivity.

- **Bronchoscopy:** A patient with a negative induced sputum should undergo bronchoscopy with bronchoalveolar lavage (BAL), which has a sensitivity of approximately 95%; some centers go directly to BAL as the initial test.[27]
- **Transbronchial or Open-Lung Biopsy:** A transbronchial biopsy or open-lung biopsy can further increase the yield but is rarely required because of the high yield with bronchoalveolar lavage.
- **Detection of *P. jirovecii* Organisms in Sample:** Many laboratories now consider the direct immunofluorescent stain as the procedure of choice for identifying *P. jirovecii* organisms; this test has higher sensitivity than other stains that can detect *P. jirovecii* (methenamine silver, Giemsa silver, and toluidine blue-O).[13,26,28,29] Although polymerase chain reaction (PCR) is a highly sensitive test for detecting *P. jirovecii* organisms, it does not accurately distinguish acute infection from colonization.[26,28,30,31]

## Treatment of *Pneumocystis* Pneumonia

The prompt and appropriate treatment of *Pneumocystis* pneumonia is essential for having a good outcome for this potentially fatal opportunistic infection. If the diagnosis of *Pneumocystis* pneumonia is suspected, empiric treatment for *Pneumocystis* pneumonia should be started without delay while the diagnostic evaluation is underway.[15] Nontoxic-appearing individuals with suspected or diagnosed *Pneumocystis* pneumonia can receive treatment as an outpatient provided they have a documented PaO<sub>2</sub> of 70 mm Hg or greater and a calculated alveolar-arterial gradient (A-a) gradient less than 35 mm Hg.[15] All the regimens used to treat *Pneumocystis* pneumonia require a duration of antimicrobial therapy for 21 days, assuming clinical improvement, although the recovery of functional status can often lag behind based on the degree of pulmonary scarring, immunosuppression, comorbidities, and/or development of IRIS.[15] Following the 21-course of therapy, patients should receive secondary prophylaxis.[15] The treatments for *Pneumocystis* pneumonia outlined below are based on recommendations in the Adult and Adolescent OI Guidelines.[15]

### Treatment of Mild-to-Moderate *Pneumocystis* Pneumonia

Mild-to-moderate *Pneumocystis* pneumonia is defined as having a PaO<sub>2</sub> of 70 mm Hg or greater and a calculated (A-a) gradient less than 35 (Table 1).[15] Individuals who are being considered for treatment as an outpatient should appear nontoxic and meet the criteria for mild-to-moderate *Pneumocystis* pneumonia. The preferred therapy for mild-to-moderate *Pneumocystis* pneumonia is oral trimethoprim-sulfamethoxazole, given in three divided daily doses.[15] If dapsone is used as an alternative therapy, it is advisable to check a glucose-6-phosphate dehydrogenase (G6PD) level prior to starting dapsone.

### Treatment of Moderate-to-Severe PCP

Moderate-to-severe *Pneumocystis* pneumonia is defined by room air PaO<sub>2</sub> less than 70 mm Hg or A-a gradient greater than or equal to 35 mm Hg (Table 2).[15] The preferred therapy is trimethoprim-sulfamethoxazole, but therapy for moderate-to-severe is usually started intravenously and then switched to oral therapy after clinical improvement.[15]

### Use of Adjunctive Corticosteroids

For moderate-to-severe *Pneumocystis* pneumonia, defined as PaO<sub>2</sub> of 70 mm Hg or greater and a calculated A-a gradient less than 35, adjunctive corticosteroids improve survival and should ideally be started as soon as antimicrobial treatment is started for *Pneumocystis* pneumonia (and no later than 72 hours after starting antimicrobial therapy).[13,15,32] The recommended corticosteroid regimen is prednisone 40 mg twice daily for days 1 to 5, prednisone 40 mg once daily for days 6 to 10, and prednisone 20 mg once daily for days 11 to 21. If parenteral therapy is needed, the dose of intravenous methylprednisolone is 80% of the oral prednisone dosage (i.e., 32 mg methylprednisolone = 40 mg prednisone).

## Treatment in Pregnant Women

Trimethoprim-sulfamethoxazole is the preferred treatment for *Pneumocystis* pneumonia in pregnancy, as its benefits outweigh potential fetal risks, including a small first-trimester teratogenic risk.[15] For mild to moderate PCP, alternative options include atovaquone suspension, or dapsons plus trimethoprim if atovaquone is unavailable or not tolerated.[15] Due to the risk of hemolytic anemia in G6PD-deficient fetuses, primaquine or dapsons should only be used during pregnancy if no safer alternatives are available and the benefits outweigh the risks. Since trimethoprim is a folate antagonist, pregnant women who are taking trimethoprim-sulfamethoxazole or trimethoprim plus dapsons should also receive 4 mg/day of folic acid during the first trimester, then reduce to 0.4 mg after 12 weeks until 4–6 weeks postpartum or after breastfeeding ends.[15] An ultrasound at 18–20 weeks' gestation is recommended to assess fetal anatomy, with possible follow-up imaging. During pregnancy, adjunctive corticosteroids should be used when indicated for HIV-related treatment, with close monitoring of maternal glucose, blood pressure, and fetal growth.[15]

## Timing of Starting Antiretroviral Therapy

Individuals not on antiretroviral therapy who develop *Pneumocystis* pneumonia should start antiretroviral therapy within 2 weeks of the diagnosis of *Pneumocystis* pneumonia, if possible.[15] The recommendation to start antiretroviral therapy early is primarily based on data from a randomized, controlled trial that early initiation of antiretroviral therapy (median 12 days after start of acute opportunistic infection treatment) resulted in a lower incidence of progression to AIDS or death, as compared to deferred initiation (median 45 days after start of acute opportunistic infection treatment).[33]

## Preventing Recurrence (Secondary Prophylaxis)

All persons with HIV who are diagnosed with *Pneumocystis* pneumonia should receive secondary prophylaxis beginning immediately after completion of the 21-day treatment course.[15] Individuals who do not receive secondary prophylaxis have a high risk for developing another episode of *Pneumocystis* pneumonia. The following table addresses the preferred and alternative regimens for secondary prophylaxis, criteria for discontinuing secondary prophylaxis, and indications for restarting secondary prophylaxis (Table 3).[15]

## ***Toxoplasma gondii* Encephalitis**

*Toxoplasma gondii* is a protozoan parasite that can infect humans and cause focal encephalitis, and more rarely, retinitis, pneumonitis, and disseminated disease. Most *Toxoplasma* disease in persons with HIV occurs from reactivation of latent organisms in the brain of patients who have a CD4 count less than 100 cells/mm<sup>3</sup>.[\[34,35\]](#) In the United States, the incidence of *Toxoplasma* encephalitis has decreased significantly with widespread use of antiretroviral therapy and prophylaxis with trimethoprim-sulfamethoxazole.[\[1,2\]](#) All individuals diagnosed with HIV should be tested for IgG antibody to *T. gondii* at their initial medical visit if their CD4 count is less than 200 cells/mm<sup>3</sup>.[\[36\]](#)

### **Clinical Manifestations**

The central nervous system is by far the most common site for the development of toxoplasmosis. Extracerebral disease, such as pulmonary or ocular involvement, occurs in about 1 to 2% of individuals with AIDS and toxoplasmosis.[\[37\]](#) Individuals with AIDS and *Toxoplasma* encephalitis characteristically present with headache, confusion, fever, and/or focal neurologic deficits ([Figure 2](#)).[\[35,36\]](#) Approximately 30% of persons with HIV and *Toxoplasma* encephalitis develop seizures, and those with severe disease may present with more profound changes in mental status.[\[35,36\]](#) Abnormal findings on physical examination may include fever, hemiparesis, ataxia, altered consciousness, and cranial nerve palsies.

### **Diagnosis**

*Toxoplasma* encephalitis is usually a presumptive diagnosis based on a combination of clinical manifestations, a positive serum anti-*Toxoplasma* antibody, and characteristic neuroradiographic findings.

- **Anti-*Toxoplasma* Antibody:** Among persons with acute *Toxoplasma* encephalitis, approximately 95% have detectable anti-*Toxoplasma* IgG antibodies using an enzyme-linked immunosorbent assay (ELISA), and approximately 85% have detectable antibodies using an indirect immunofluorescence assay (IFA) with a cutoff of greater than or equal to 1:16.[\[35\]](#)
- **Brain Imaging:** Contrast brain computed tomography (CT) scan shows enhancing lesions in approximately 90% of adults with HIV who have acute *Toxoplasma* encephalitis.[\[35\]](#) Individuals with AIDS and *Toxoplasma* encephalitis generally have multiple ring-enhancing lesions that often involve the basal ganglia ([Figure 3](#)).[\[35\]](#) Magnetic resonance imaging (MRI) is more sensitive than computed tomography (CT) for identifying *Toxoplasma* brain lesions and often shows multiple lesions when a CT scan has demonstrated only a solitary lesion. Since MRI is the more sensitive test, it is ideal to perform an MRI at the time the initial diagnosis is made and use this test to follow response to therapy.
- **Analysis of Cerebrospinal Fluid:** Ideally, a lumbar puncture should also be performed for *T. gondii* PCR testing on the cerebrospinal fluid (CSF) sample to help support the diagnosis; PCR for *T. gondii* in this setting has high specificity but low sensitivity, particularly once anti-*toxoplasma* therapy has been initiated.[\[38,39\]](#) In addition, CSF studies can help to investigate other conditions in the differential diagnosis.[\[40,41\]](#)
- **Brain Biopsy:** In some circumstances, such as an acute life-threatening presentation or failure to respond to therapy for toxoplasmosis, a definitive diagnosis is needed; this requires detection of *T. gondii* organism in a clinical sample usually obtained via a stereotactic CT-guided brain biopsy (with hematoxylin and eosin staining, or ideally immunoperoxidase staining).

## **Treatment of *Toxoplasma* Encephalitis**

### **Initial Therapy for *Toxoplasma* Encephalitis**

Individuals with suspected *Toxoplasma* encephalitis should immediately receive intensive high-dose anti-*Toxoplasma* therapy. The Adult and Adolescent OI Guidelines provide recommendations for preferred and

alternative regimens for the initial treatment ([Table 4](#)).[\[36\]](#) The preferred first-line therapies for *Toxoplasma* encephalitis are pyrimethamine plus sulfadiazine plus leucovorin (using weight-based dosing) or trimethoprim-sulfamethoxazole.[\[34,42,43\]](#) Leucovorin is used in this regimen to prevent hematologic toxicity secondary to pyrimethamine. More recently, trimethoprim-sulfamethoxazole has increasingly been used as the preferred agent for treatment due to the extremely high cost of pyrimethamine (and difficulty accessing this medication).[\[44\]](#) The initial treatment is for at least 6 weeks. Longer duration for acute treatment may be required with severe disease, or if the response to treatment is incomplete at 6 weeks. Following the initial treatment course, persons with HIV and toxoplasmosis should transition to chronic maintenance therapy.

### **Treatment During Pregnancy**

For pregnant women with suspected or confirmed *Toxoplasma* encephalitis during pregnancy, the treatment should be the same as that recommended for other adults with HIV.[\[36\]](#) For pregnant women with primary infection or symptomatic reactivation, treatment depends on the gestational age at the time of the acquisition or reactivation, and the treatment must consider prevention of congenital transmission. Given the complexity of managing toxoplasmosis in pregnancy, expert consultation with a specialist is recommended.[\[36\]](#)

### **Timing of Starting Antiretroviral Therapy**

For persons with HIV who develop *Toxoplasma* encephalitis while not taking antiretroviral therapy, the optimal timing for initiating antiretroviral therapy remains unknown. Based on available data, most experts recommend starting antiretroviral therapy within 2 to 3 weeks of the diagnosis of *Toxoplasma* encephalitis.[\[36\]](#) This recommendation is primarily based on extrapolation of findings that showed early initiation of antiretroviral therapy reduces HIV progression and death in individuals with acute opportunistic infections.[\[33\]](#)

### **Response to Initial Therapy**

More than 70% of individuals with HIV and *Toxoplasma* encephalitis have clinical and radiographic improvement within 14 days of receiving appropriate therapy for *Toxoplasma* encephalitis.[\[34,35,45\]](#) In one retrospective study, among patients with *Toxoplasma* encephalitis who eventually responded to anti-*Toxoplasma* therapy, 86% had improvement by day 7, and 91% had improvement (with respect to at least half of baseline abnormalities) by day 14 ([Figure 4](#)).[\[45\]](#) Thus, if by day 14, the person has not responded to therapy, the clinician should strongly consider a diagnosis other than *Toxoplasma* encephalitis and obtain further studies, typically including a brain biopsy, in an attempt to make a definitive or alternative diagnosis.[\[45\]](#)

### **Preventing Recurrence (Chronic Maintenance Therapy)**

In the absence of chronic maintenance therapy for *Toxoplasma* encephalitis in persons not taking antiretroviral therapy, the rate of relapse after an initial episode of *Toxoplasma* encephalitis is high, with an incidence of 50 to 80% among persons surviving more than 6 to 12 months.[\[46\]](#) Thus, patients with *Toxoplasma* encephalitis who have successfully completed at least 6 weeks of acute therapy should transition to chronic maintenance therapy.[\[36\]](#) The preferred chronic maintenance regimens are the same as those used for initial therapy for *Toxoplasma* encephalitis but are administered at a lower dose.[\[36\]](#) Both of the preferred regimens are adequate for *Pneumocystis* pneumonia prophylaxis. The following table addresses chronic maintenance therapy ([Table 5](#)).[\[36\]](#)

## Disseminated *Mycobacterium avium* Complex

In the era prior to effective antiretroviral therapy, *Mycobacterium avium* complex (MAC) infection was a common complication of advanced HIV disease.[47] *Mycobacterium avium* complex represents a group of nontuberculous mycobacteria that are ubiquitous in the environment; the mode of transmission for these organisms is thought to occur via the lungs or gastrointestinal tract, but preventing environmental exposure is not realistic.[48] Most persons who develop disseminated MAC have a CD4 count of less than 50 cells/mm<sup>3</sup>. [49] The incidence of disseminated MAC infection has declined dramatically since the early 1990s.[1,2,50] When cases of disseminated MAC occur, they usually involve individuals with HIV who have advanced immunosuppression and are unaware of their HIV diagnosis, or persons with HIV who are aware of their HIV diagnosis but not engaged in medical care.

### Clinical Manifestations

The MAC-related clinical manifestations result from the huge burden of organisms, which interfere with tissue function and alter cytokine production.[51] Persons with disseminated MAC typically present with nonspecific symptoms, including fatigue, fever, weight loss, diarrhea, and abdominal pain (Figure 5).[52] Physical examination findings may reveal hepatomegaly, splenomegaly, or lymphadenopathy. Common abnormal laboratory studies include anemia, increased alkaline phosphatase (often with normal bilirubin and hepatic aminotransferase levels), and an increased serum lactate dehydrogenase level.[51,52,53] Abdominal CT scan abnormalities may include multiple large retroperitoneal and mesenteric lymph nodes, hepatomegaly, splenomegaly, and a thickened small bowel wall.[54]

### Diagnosis

The definitive diagnosis of disseminated MAC is usually made by isolating the organism from a normally sterile body site.[48] Use of mycobacterial blood cultures to isolate MAC has become the preferred method of diagnosis: among persons with untreated disseminated MAC, obtaining two sets of blood cultures has a sensitivity of greater than 90%.[55,56] Growth from MAC blood cultures is slow, but usually occurs by day 14, at which point the exact *Mycobacterium* species can be identified using DNA probes. The diagnosis of disseminated MAC is sometimes made from a lymph node biopsy or a bone marrow biopsy.

### Treatment of Disseminated MAC

#### Initial Therapy for Disseminated MAC

The Adult and Adolescent OI Guidelines recommend initial treatment for disseminated MAC with at least two active drugs, typically with a macrolide (clarithromycin or azithromycin) plus ethambutol.[48,57,58,59] Persons taking ethambutol require regular ophthalmologic examinations due to the risk of optic neuritis. Some experts would add a third or fourth medication in selected circumstances, such as with more severe MAC disease or when effective antiretroviral therapy is absent.[48] In most situations, the treatment regimen for disseminated MAC should be continued for a minimum of 12 months.[48] The following table outlines preferred therapy, considerations for adding rifabutin as a third medication, and considerations for adding a fourth drug (Table 6).[48]

#### Timing of Initiating Antiretroviral Therapy

Individuals newly diagnosed with disseminated MAC who are not on antiretroviral therapy should promptly start treatment for disseminated MAC and preferably start antiretroviral therapy at the same time that treatment for MAC is initiated.[48] Starting antiretroviral therapy at the same time as starting MAC treatment is recommended for two reasons: (1) to improve the treatment response to antimycobacterial therapy and (2) to lower the risk of developing other serious opportunistic infections. The antiretroviral regimens should be adjusted to minimize the risk of adverse drug interactions with the antimycobacterial medications.

## **MAC and Immune Reconstitution Inflammatory Syndrome (IRIS)**

*Mycobacterium avium* complex IRIS is a potential complication following initiation of antiretroviral therapy in patients with disseminated MAC.[60] Persons with MAC-related IRIS usually present with intraabdominal lymphadenopathy or pulmonary-thoracic disease; the risk of death from MAC IRIS appears to be low, and the long-term prognosis is favorable.[60] The management of moderate-to-severe MAC IRIS-related symptoms should start with a nonsteroidal, antiinflammatory drug. If, however, there is no clinical improvement or initial symptoms are severe, then more aggressive treatment of IRIS is warranted, using systemic corticosteroid therapy with oral prednisone 20 to 40 mg daily for 4 to 8 weeks.[48] Severe MAC IRIS may require use of repeated or longer courses of corticosteroids. Antiretroviral therapy should typically be continued if MAC IRIS develops.

### **Preventing Recurrence (Chronic Maintenance Therapy)**

The regimens for chronic maintenance therapy (secondary prophylaxis) in patients with MAC are exactly the same as those used for initial therapy.[48]

### **Discontinuing Chronic Maintenance Therapy**

Discontinuing secondary MAC prophylaxis (chronic maintenance therapy) requires meeting all the following criteria:[48]

- Successful completion of at least 12 months of MAC therapy, *and*
- No signs or symptoms of MAC disease, *and*
- Sustained (at least 6 months) increase in CD4 count to greater than 100 cells/mm<sup>3</sup> in response to antiretroviral therapy.

### **Restarting Chronic Maintenance Therapy**

Secondary MAC prophylaxis should be restarted if a fully suppressive antiretroviral therapy regimen is not possible and the CD4 count is consistently less than 100 cells/mm<sup>3</sup>. [48]

## Cryptococcosis

Cryptococcosis is an opportunistic fungal infection that causes significant morbidity and mortality in persons with HIV who have advanced immunosuppression. In the United States, the incidence of cryptococcal antigenemia is 2.9% in adults with a CD4 count less than 100 cells/mm<sup>3</sup> and 4.3% in those with less than 50 cells/mm<sup>3</sup>.[\[61\]](#) Most cryptococcal infections in persons with HIV are caused by *Cryptococcus neoformans*.[\[62\]](#) As with other opportunistic infections, the widespread use of highly active antiretroviral therapy has led to a decrease in the incidence of cryptococcal meningitis. Most cases are identified in persons with recently diagnosed HIV who have advanced immunosuppression, or in persons with established HIV who are not taking antiretroviral therapy.[\[63\]](#)

### Clinical Manifestations

Cryptococcal meningitis occurs as a result of disseminated infection and typically manifests with a more indolent presentation than acute bacterial meningitis.[\[62\]](#) Most patients with early cryptococcal meningitis develop nonspecific symptoms consisting of fever and headache, and approximately 65 to 75% do not have classic signs of meningeal irritation early in their course of meningitis.[\[62\]](#) As the disease progresses, more neurologic-specific manifestations typically develop, including altered mental status, neck stiffness, or cranial nerve abnormalities ([Figure 6](#)).[\[64\]](#) Approximately 10% of individuals with disseminated cryptococcal disease have cutaneous manifestations that may resemble molluscum contagiosum.[\[65\]](#) Individuals with HIV can develop pulmonary cryptococcal disease, with or without central nervous system involvement.

### Diagnosis

The diagnosis of cryptococcal meningitis is usually made by obtaining a positive cryptococcal antigen test on a cerebrospinal fluid (CSF) sample. Among persons with HIV who have cryptococcal meningitis, the cerebrospinal fluid and serum cryptococcal antigen test are positive in more than 95% of cases, often with a very high titer.[\[66,67,68\]](#) When there is strong clinical suspicion for cryptococcal meningitis but the CSF cryptococcal antigen test is negative, a prozone effect should be considered, and the sample should be diluted and retested to rule out a false-negative result caused by very high antigen levels. A positive serum cryptococcal antigen is not sufficient to diagnose central nervous system disease. Most experts would recommend performing a brain CT prior to lumbar puncture to evaluate for a brain mass lesion that could result in brain herniation during the procedure. Tests done on CSF should include cryptococcal antigen, fungal culture, glucose, protein, cell count with differential, Gram's stain, bacterial culture, and other studies as indicated. More than 50% of individuals with cryptococcal meningitis have fewer than 20 leukocytes/mm<sup>3</sup> on the CSF cell count. Opening pressure should be measured at the time of lumbar puncture in all persons with suspected cryptococcal meningitis, since a significant proportion will have an elevated CSF pressure.[\[69\]](#)

### Treatment of Cryptococcal Meningitis

The recommended treatment of cryptococcal meningitis involves three phases: induction therapy, consolidation therapy, and chronic maintenance therapy.[\[62\]](#) Serial monitoring of cryptococcal antigen (blood or CSF) to determine response to therapy has shown minimal benefit and is not recommended.[\[70\]](#)

#### Induction Therapy for Cryptococcal Meningitis

The recommended initial induction therapy for cryptococcal meningitis consists of either intravenous liposomal amphotericin B plus oral flucytosine or intravenous amphotericin B deoxycholate plus oral flucytosine ([Table 7](#)).[\[62\]](#) Liposomal amphotericin B has similar efficacy as amphotericin B deoxycholate but is associated with a lower risk of renal toxicity.[\[62,71,72\]](#) Flucytosine, when added to either liposomal amphotericin B or amphotericin B deoxycholate, results in more rapid CSF sterilization.[\[73\]](#) If flucytosine is used, it is ideal to check a flucytosine level after administering 3 to 5 doses of flucytosine, approximately 2 hours after taking the dose. The target serum flucytosine level is 25 to 100 mg/L. The flucytosine dose must

be adjusted in persons with renal impairment.[62]

## Management of Increased Intracranial Pressure

At the time induction therapy is started, cryptococcal meningitis is often associated with increased intracranial pressure (opening pressure greater than 20 cm H<sub>2</sub>O). Appropriate management of increased intracranial pressure can improve survival and neurologic outcomes. In a retrospective study performed in the United States, investigators showed that patient outcomes strongly correlated with the use of serial lumbar punctures to manage increased intracranial pressure during the first 2 weeks of therapy for cryptococcal meningitis (Figure 7).[69] A more recent study of patients with acute cryptococcal meningitis in Africa also showed a marked survival benefit if therapeutic lumbar punctures were performed in persons with high opening pressure.[74] The following summarizes recommendations from the Adult and Adolescent OI Guidelines for managing elevation in intracranial pressure in persons with cryptococcal meningitis.[62]

- **Lowering Opening Pressure at Initial Lumbar Puncture:** If the opening pressure is elevated, the recommended approach is to remove ample cerebrospinal fluid (20 to 30 mL) to reduce the opening pressure to normal (less than 20 cm H<sub>2</sub>O), or at least by 50% if not able to achieve a normal pressure with the removal of 20 to 30 mL.[62]
- **Serial Lumbar Punctures:** For persons with ongoing symptoms, such as headache or confusion, serial lumbar punctures with cerebrospinal fluid drainage may be required on a daily basis to maintain opening pressure less than 20 cm H<sub>2</sub>O; daily lumbar punctures should be continued until the opening pressure normalizes and symptoms resolve.[62]
- **Use of Lumbar Drains or Ventriculostomy:** If the person initially has focal neurologic deficits, or serial lumbar punctures with the removal of cerebrospinal fluid fails to control increased intracranial pressures, a lumbar drain or ventriculostomy may be required.[62,75]
- **Medical Therapy for Reducing Intracranial Pressure:** For persons with acute cryptococcal meningitis, attempts to treat increased intracranial pressure with medical therapy, such as mannitol, acetazolamide, or corticosteroids, is not effective and is not recommended.[62,76]

## Evaluation After Course of Induction Therapy

If there is substantial clinical improvement after completing the 2-week induction course, lumbar puncture should be performed (at or near the end of the induction therapy) to obtain cerebrospinal fluid fungal cultures.[62] If the patient does not improve clinically, then induction therapy should be continued until the cerebrospinal fluid cultures are negative.[62]

## Consolidation Therapy for Cryptococcal Meningitis

After at least 2 weeks of successful initial induction therapy, patients who are clinically stable can start induction therapy with oral fluconazole 800 mg once daily while cerebrospinal fluid fungal cultures are pending (Table 8).[62] The consolidation regimen should be adjusted based on CSF fungal culture results.[62] The duration of consolidation therapy is 8 weeks from the time of negative cerebrospinal fluid culture.[62] Monitoring serum and/or cerebrospinal cryptococcal antigen titers is not recommended.[62]

## Cryptococcal Meningitis and IRIS

A paradoxical worsening of cryptococcal meningitis occurs in up to 30% of persons with HIV who start antiretroviral therapy at the same time (or soon after) they start treatment for cryptococcal meningitis.[77] If cryptococcal meningitis-associated IRIS develops, it is often life-threatening. Baseline factors associated with an increased risk of developing cryptococcal meningitis-associated IRIS include lack of prior antiretroviral therapy, high baseline HIV RNA, low white blood cell count in cerebrospinal fluid, and a high cerebrospinal fluid fungal burden.[7] The challenge of such cases is differentiating between cryptococcal meningitis treatment failure, a new central nervous system disorder, or IRIS. Persons with IRIS typically have negative cerebrospinal fluid fungal cultures, whereas those with treatment failure will have positive cultures. If a new

central nervous system problem and treatment failure are ruled out, and IRIS is the most likely diagnosis, antiretroviral therapy and antifungal therapy should be continued in conjunction with careful lowering of intracranial pressure, if indicated. Mild cases can be managed with nonsteroidal antiinflammatory medications, and most experts would use oral corticosteroids in severe cases.

### Timing of Initiating Antiretroviral Therapy

To reduce the risk of IRIS in patients with cryptococcal meningitis, the Adult and Adolescent OI Guidelines recommend delaying initiation of antiretroviral therapy for 4 to 6 weeks after starting treatment for cryptococcal meningitis, ideally after negative CSF cryptococcal cultures have been obtained.[62] A 2014 study from Uganda and South Africa demonstrated that deferral of antiretroviral therapy for 5 weeks was associated with a significant improvement in survival, as compared with initiating antiretroviral therapy at 1 to 2 weeks, especially among patients with a low white blood cell count in the cerebrospinal fluid.[78] Several additional studies support the approach of deferring antiretroviral therapy for at least several weeks.[79,80]

### Maintenance Therapy for Cryptococcal Meningitis

Maintenance therapy with fluconazole 200 mg once daily is required for at least 1 year after successful induction and consolidation treatment of cryptococcal meningitis.[62] Separate studies have shown that fluconazole is superior to intravenous amphotericin B and to oral itraconazole for chronic maintenance therapy, so the latter two are not recommended.[81,82] The following table addresses the preferred regimen for maintenance therapy, criteria for stopping maintenance therapy, and indications for restarting maintenance therapy (Table 9).[62]

### Additional Treatment Considerations

The following summarizes the recommended treatment approach for: (1) cryptococcal infection that does not involve the lungs or central nervous system (CNS), (2) diffuse cryptococcal pulmonary disease, and (3) asymptomatic persons with isolated cryptococcal antigenemia.[62] Note that all asymptomatic persons with HIV who have cryptococcal antigenemia should have their CSF evaluated for occult cryptococcal meningitis.[62]

- **Treating Non-CNS Extrapulmonary, Diffuse Pulmonary Disease, or Asymptomatic Patients with Isolated Cryptococcal Antigenemia (Serum LFA titer  $\geq 1:640$ ) Without Evidence of CNS Disease:** The recommendation is to use the same treatment as recommended for cryptococcal meningitis, but without the need for follow-up lumbar puncture and CSF analysis.[62]
- **Treating Non-CNS Focal Pulmonary Disease or Asymptomatic Patients with Isolated Cryptococcal Antigenemia (Serum LFA titer  $\leq 1:320$ ), Without Evidence of CNS Disease:** The recommended treatment is fluconazole 400 to 800 mg PO daily for 10 weeks, followed by fluconazole 200 mg daily, with a total duration of therapy of 6 months.[62]

## Cytomegalovirus Disease

Cytomegalovirus (CMV) is a double-stranded DNA virus in the herpes family that can cause invasive disease, including retinitis, colitis, and central nervous system disease, in persons with HIV who have advanced immunosuppression (CD4 count less than 50 cells/mm<sup>3</sup>).[\[83,84\]](#) Among people with HIV, retinitis is the most common form of CMV end-organ disease. Typically, CMV disease in people with HIV occurs due to reactivation of latent CMV infection. Among men with HIV who have sex with men, CMV-positive antibody rates are greater than 90%. Following the widespread availability and use of effective antiretroviral therapy, the incidence of CMV retinitis has declined by more than 90%.[\[85,86,87\]](#)

### Clinical Manifestations

#### Retinitis

Individuals with CMV retinitis most often develop one or more ocular manifestations commonly referred to as the four “F’s”: floaters, flashes, field deficits, or failing vision.[\[88\]](#) These manifestations can represent loss of peripheral and/or central vision. Individuals with CMV retinitis do not have pain related to the lesions. Although only one eye is usually involved at the initial presentation, CMV disease can progress to affect the contralateral eye, particularly in individuals who are not on antiretroviral therapy.[\[89\]](#) On dilated fundusoscopic examination, the CMV-associated retinal lesions typically appear as yellow or white patches caused by retinal necrosis, with or without hemorrhage, usually following a vascular distribution; the findings of CMV retinitis should not be confused with findings caused by HIV retinopathy ([Figure 8](#)).[\[84\]](#)

#### Gastrointestinal

Odynophagia is usually the most prominent symptom associated with CMV esophagitis.[\[90\]](#) In addition, individuals with HIV and CMV colitis typically have weight loss, malaise, anorexia, abdominal pain, debilitating diarrhea (sometimes bloody), and potentially develop gastrointestinal perforation as a life-threatening complication.[\[91,92\]](#)

#### Neurologic

Less frequently, individuals with HIV and CMV infection can have neurologic manifestations, including myelitis, polyradiculomyelopathy, encephalitis, and ventriculitis.[\[93\]](#)

#### Pneumonia

Cytomegalovirus pneumonitis is rarely seen in individuals with HIV, in contrast to the high frequency seen among patients with other forms of profound immunosuppression, such as bone marrow transplantation. Cytomegalovirus pneumonitis, when present, usually manifests with fever, cough, and/or dyspnea.

### Diagnosis

Most individuals with HIV and CMV retinitis, colitis, or other end-organ disease have CMV viremia that can be detected by PCR, antigen assays, or culture, but testing for CMV viremia is not recommended for the diagnosis of CMV-related end-organ disease.[\[84,86\]](#)

#### Retinitis

The diagnosis of CMV retinitis is a clinical diagnosis based on characteristic findings observed during a dilated fundusoscopic examination by an ophthalmologist.[\[84,86\]](#) With a handheld monocular direct ophthalmoscope, a clinician can visualize all of zone 1 (including the optic nerve head and the macula), less than half of zone 2, and none of zone 3 ([Figure 9](#)). Thus, all patients suspected of having CMV retinitis should see an

ophthalmologist for a full retinal examination. Obtaining PCR of aqueous or vitreous specimens can be helpful but is not practical in most situations.

## **Gastrointestinal**

The diagnosis of CMV esophagitis or colitis is suggested by observing mucosal ulcerations on endoscopy, but a definitive diagnosis requires characteristic biopsy findings showing intranuclear and intracytoplasmic inclusions.[92] Abdominal computed tomographic scans may show colonic thickening, but this finding is nonspecific.

## **Neurologic**

The diagnosis of CMV central nervous system disease is usually made based on compatible clinical findings in conjunction with a positive cerebrospinal fluid PCR test for CMV.[94]

## **Pneumonia**

Although CMV is commonly identified in bronchoalveolar lavage (BAL) fluid via nucleic acid testing in patients with HIV and low CD4 cell count, it has low diagnostic value.[86] In such cases, clinicians should consider alternative pathogens. The diagnosis requires radiologic findings (diffuse infiltrates) combined with histologic evidence of multiple CMV inclusion bodies in lung tissue.[86] In addition, a confirmed diagnosis of CMV pneumonitis requires exclusion of more common respiratory pathogens.[86]

## **Treatment**

The Adult and Adolescent OI Guidelines recommendations for the treatment of CMV disease vary based on the organ system affected.[86]

### **Initial Treatment of CMV Retinitis**

The treatment of CMV retinitis depends on whether the individual has sight-threatening retinitis or peripheral lesions; lesions are considered sight-threatening if they are within 1,500 microns of the fovea.[86] The preferred initial treatment for CMV retinitis consists of induction therapy with oral valganciclovir or intravenous ganciclovir.[86] If there is an immediate site-threatening lesion, many clinicians prefer induction with intravenous ganciclovir. In addition, with immediate site-threatening lesions, systemic therapy should be supplemented with repeated intravitreal injections of either ganciclovir or foscarnet, given every 7 days until lesion inactivity is achieved.[86] For small peripheral lesions that are not vision threatening, providing induction therapy with oral valganciclovir is usually sufficient.[86] Even if the ocular clinical manifestations are unilateral, systemic therapy helps to prevent disease in the contralateral eye. The following table summarizes preferred and alternative treatments for CMV retinitis, including treatment for sight-threatening and peripheral lesions ([Table 10](#)).[86]

### **Cytomegalovirus Retinitis and IRIS**

The ocular form of CMV-associated IRIS, typically referred to as immune reconstitution uveitis, is characterized by inflammation in the anterior chamber or vitreous; vision loss from macular edema, cataracts, or epiretinal membranes can occur.[95,96,97,98] Immune reconstitution uveitis tends to occur in the first 3 months after starting antiretroviral therapy but can occur even years after treatment of acute CMV retinitis.[86] The risk of developing CMV-associated IRIS is highest when the CMV disease involves more than 30% of the retina.[99] The treatment of immune reconstitution uveitis typically consists of continued CMV treatment with the addition of corticosteroids (intravitreal or oral).[86,100]

### **Maintenance Therapy for CMV Retinitis**

After completion of 14 to 21 days of induction therapy for CMV retinitis, persons should transition to chronic maintenance therapy.

- **Preferred Therapy:** The initial intravenous ganciclovir induction therapy should be followed by maintenance therapy with either oral valganciclovir 900 mg once daily or intravenous ganciclovir 5mg/kg once daily. If oral therapy was used for the initial therapy, it should be followed by maintenance therapy with oral valganciclovir 900 mg once daily.
- **Alternative Therapy:** If foscarnet or cidofovir is required for initial therapy, either can be continued for maintenance therapy, but expert consultation is advised since these agents are likely to cause significant toxicity if continued for prolonged periods of time.

### **Discontinuing Maintenance Therapy for CMV Retinitis**

Chronic maintenance therapy for CMV retinitis can be discontinued when the following criteria are met:

- At least 3 to 6 months of CMV treatment has been completed, *and*
- No retinal lesions are active, *and*
- The CD4 count is above 100 cells/mm<sup>3</sup> for 3 to 6 months in response to antiretroviral therapy, *and*
- An ophthalmologist has been consulted.

Note: After stopping maintenance therapy, ophthalmologic monitoring for early detection of CMV relapse should ideally be performed every 3 months to evaluate for early relapse of retinitis and to detect immune reconstitution uveitis. After sustained immune reconstitution has occurred, periodic ophthalmologic examinations should be performed as indicated and feasible. Monitoring CMV viral load in blood is not recommended as it has poor positive predictive value for retinitis relapse.

### **Restarting Chronic Maintenance Therapy**

Chronic maintenance therapy should be restarted if the CD4 count decreases to less than 100 cells/mm<sup>3</sup>.

### **Treatment of CMV Esophagitis or Colitis**

The following summarizes the Adult and Adolescent OI Guidelines recommendations for the preferred and alternative therapies for CMV esophagitis or colitis.[86] The preferred therapy is intravenous ganciclovir and the duration of therapy is 21 to 42 days or until clinical symptoms resolve (Table 11).[86]

### **Treatment of CMV Pneumonia and CMV Encephalitis**

There are limited, mostly anecdotal, data for the treatment of CMV pneumonia and CMV neurological disease. The recommended treatment for CMV pneumonia consists of either intravenous ganciclovir or intravenous foscarnet.[86] For neurological disease, many clinical experts would initiate a combined antiviral intravenous regimen of ganciclovir and foscarnet, despite the toxicities associated with using these drugs simultaneously.[86] The duration of therapy for either of these disease entities is at least 21 days and should only occur after clinical improvement.

### **Adverse Effects Associated with CMV Therapy**

Cytopenias (anemia, thrombocytopenia, neutropenia) are the most important toxicity associated with ganciclovir and valganciclovir use, but it can be managed by using granulocyte colony-stimulating factor (G-CSF).[86,101] During induction with ganciclovir or valganciclovir, a complete blood count and serum creatinine should be monitored at least twice weekly and then once weekly during maintenance. Foscarnet use can be associated with nephrotoxicity and electrolyte derangements. Toxicity monitoring during foscarnet therapy should include serum electrolytes and serum creatinine at least twice weekly during induction and once weekly while on maintenance treatment. Intravenous cidofovir use can lead to nephrotoxicity, ocular

hypotony, and neutropenia. Aggressive intravenous fluid hydration and oral probenecid administration immediately prior to cidofovir dosing can help to attenuate renal issues.[86]

### **Timing of Initiating Antiretroviral Therapy**

Among persons with HIV who develop CMV retinitis, the risk of developing CMV-associated IRIS is greater when antiretroviral therapy is immediately started versus deferring antiretroviral therapy until the CMV retinitis is initially controlled.[102] Individuals with newly diagnosed CMV who are not on antiretroviral therapy should promptly start treatment for CMV retinitis or CMV end-organ disease and then start antiretroviral therapy no more than 2 weeks later.[86] There is also a significant concern for the development of CMV-related IRIS in persons who have CMV neurologic disease.

## Progressive Multifocal Leukoencephalopathy

Progressive multifocal leukoencephalopathy (PML) is a focal demyelinating disease of the central nervous system caused by reactivation of the John Cunningham (JC) virus in persons who have impaired immunity, most often in the setting of HIV-associated immunosuppression.[103] Infection with JC virus is common, and antibodies to JC virus are detected in more than 80% of humans worldwide.[104] Although the incidence of PML has decreased with the widespread use of effective antiretroviral therapy, mortality remains high for those persons with HIV who develop PML.[105,106]

### Clinical Manifestations

Persons with HIV who develop PML typically present with subacute, progressive focal neuropsychiatric signs and symptoms, including cognitive disturbances, visual changes, limb paresis, hemisensory deficits, dysmetria, and ataxia.[104,107,108] The clinical presentation with PML may be difficult to distinguish from severe HIV-associated dementia or a slowly evolving stroke.[103,109] Approximately 15 to 20% of persons with PML will have at least one seizure.[110,111] Headache, fever, acute encephalopathy, and spinal cord manifestations are rare. In persons with AIDS, if immunosuppression is not reversed with antiretroviral therapy, PML will have a relentless progression and will lead to death within 6 months.[103]

### Diagnosis

Brain biopsy is the gold standard for diagnosis, but it is not usually performed since a presumptive diagnosis can be made based on brain magnetic resonance imaging (MRI) findings. Brain MRI usually shows focal white matter lesions that correlate anatomically to the patient's neurological deficits; these multiple high-signal intensity lesions are best seen on T2-weighted and FLAIR sequences (Figure 10).[103] In addition, 70 to 90% of persons with PML who are not taking antiretroviral therapy have a positive JC virus DNA PCR in the cerebrospinal fluid (this number drops to about 60% among persons who are taking antiretroviral therapy).[112] Detection of JC virus in the cerebrospinal fluid is not necessary to confirm the diagnosis of PML if the clinical picture and brain MRI findings are consistent with the diagnosis, but may support the diagnosis of PML in atypical cases. Plasma PCR detection of JC virus DNA can be a useful adjunct test, especially when CSF is not readily available, with the test having high specificity but relatively low sensitivity.[112,113]

### Treatment

There is no specific antiviral therapy for JC virus.[103] The cornerstone for the treatment of PML in persons with HIV is antiretroviral therapy, with resultant immune restoration.[112] Antiretroviral therapy should promptly be initiated or optimized in all persons with HIV who are diagnosed with PML. Among those with HIV and PML who receive effective antiretroviral therapy, the 1-year survival rate is only 55 to 60%, and survivors often have some permanent neurologic deficits.[103,114] Multiple therapies have been attempted for treatment of PML in persons with HIV, but none (except for antiretroviral therapy-related immune reconstitution) has been shown to be effective (Table 12).[112] The following therapies should not be used to treat PML in persons with HIV: intravenous cytarabine, intrathecal cytarabine, cidofovir, mefloquine, mirtazapine, olanzapine, ziprasidone, cyproheptadine, risperidone, interferon-alfa, and check-point inhibitors, such as pembrolizumab.[112]

### Timing of Initiating Antiretroviral Therapy

Individuals with HIV newly diagnosed with PML who are not on HIV antiretroviral therapy should immediately start on a fully suppressive antiretroviral therapy.[112] There is no rationale to delay therapy since there is no known effective antiviral therapy specific for PML that could be used to reduce the JC virus load prior to starting HIV antiretroviral therapy. Individuals diagnosed with PML who are taking antiretroviral therapy but do not have optimal suppression of HIV should receive a fully suppressive antiretroviral regimen.

## Management of Immune Reconstitution Syndrome

Persons with HIV may develop PML immune reconstitution syndrome in the first weeks to months after starting antiretroviral therapy. The increased inflammation in the central nervous system may potentially cause mass effect and herniation. For individuals with a contrast-enhanced imaging that shows significant inflammation, use of corticosteroids can be considered.[\[112\]](#) There is no consensus on the dosage or duration of corticosteroids for PML IRIS; the Adult and Adolescent OI Guidelines suggest one approach modeled on treating flares of multiple sclerosis, which is to start with a 3- to 5-day course of intravenous methylprednisolone (1 gram per day) and then transition to oral prednisone 60 mg once daily and taper over 1 to 6 weeks.[\[112\]](#) Some experts recommend obtaining a brain MRI at 2 to 6 weeks after starting corticosteroid therapy to reevaluate edema and inflammation, which can inform the corticosteroid dosing schedule and establish a new radiographic baseline. Antiretroviral therapy should not be discontinued in this setting.[\[112\]](#)

## Managing Treatment Failure

Clinical and radiographic improvement with PML typically takes at least several weeks. Treatment failure should be considered if there is continued clinical worsening despite at least 3 months of antiretroviral therapy, especially if HIV RNA levels are suppressed and CD4 counts improve.[\[112\]](#) If the person has not had a good HIV RNA response with antiretroviral therapy, it is very important to promptly address virologic failure and achieve virologic suppression as soon as possible.[\[112\]](#) If PML worsens despite fully suppressive antiretroviral therapy, unproven therapies may be considered with expert consultation, weighing potential toxicity against uncertain benefit.[\[112\]](#)

## Esophageal Candidiasis

Esophageal candidiasis remains a significant cause of morbidity in persons with HIV, but the incidence has declined markedly since the widespread use of highly effective antiretroviral therapy.[85] When esophageal candidiasis occurs, it usually involves individuals with a CD4 cell count less than 100 cells/mm<sup>3</sup>.[\[115\]](#) *Candida albicans* is the most common species involved, but non-*albicans* species (*C. dubliniensis*, *C. glabrata*, *C. tropicalis*) can also cause disease.[\[116\]](#) In addition, *Candida glabrata* is associated with azole resistance among patients with advanced immunosuppression, particularly those who have received repeated or prolonged courses of oral fluconazole.[\[117,118,119\]](#)

### Clinical Manifestations

Esophageal candidiasis usually causes retrosternal burning pain and odynophagia.[\[120,121\]](#) Persons with HIV and esophageal candidiasis often also have oropharyngeal candidiasis, which typically presents with painless, creamy white plaques or patches on the tongue, buccal mucosa, or pharynx that can be easily scraped off with a tongue blade.

### Diagnosis

A presumptive diagnosis of esophageal candidiasis is based on typical clinical symptoms and response to empiric antifungal treatment.[\[120\]](#) A definitive diagnosis can be made with endoscopic evaluation with visualization and obtaining fungal culture (with speciation), but this approach is generally reserved for patients who do not respond within 7 days after starting antifungal therapy.[\[120,122\]](#) If endoscopy is performed, it should evaluate for other potential causes of esophagitis.

### Treatment

#### Initial Therapy

For initial treatment of esophageal candidiasis, the preferred therapy should be oral or intravenous fluconazole.[\[120,123,124\]](#) The recommended initial course of treatment for esophageal candidiasis is 14 to 21 days.[\[120\]](#) Multiple alternative options are available ([Table 13](#)).[\[120\]](#)

#### Therapy During Pregnancy

During the first trimester of pregnancy, intravenous amphotericin B is recommended for the treatment of esophageal candidiasis.[\[120\]](#) Data derived from women with vulvovaginal candidiasis suggest that fluconazole should not be used in the first trimester due to the risk of spontaneous abortion and, with doses greater than 150 mg per day, the risk of cardiac septal closure defects.[\[125,126,127\]](#) Use of agents other than amphotericin B to treat esophageal candidiasis in pregnancy is not recommended, either due to inadequate data in pregnancy or known teratogenic effects.[\[120\]](#)

#### Timing of Starting Antiretroviral Therapy

Antiretroviral therapy should be initiated without delay in patients with *Candida* esophagitis.[\[120\]](#)

#### Chronic Suppressive Therapy

Chronic suppressive therapy for *Candida* is not recommended for persons with isolated episodes of esophageal candidiasis because therapy for acute episodes of disease is effective, mortality from candidiasis is low, drug interactions can occur, and suppressive therapy may increase drug-resistant species.[\[120\]](#) The use of chronic suppressive therapy for persons with esophageal candidiasis is usually limited to situations when individuals with a CD4 count less than 200 cells/mm<sup>3</sup> have severe bouts of esophageal candidiasis or

frequent recurrences.[\[120\]](#) If the decision is made to administer chronic suppressive therapy for patients with esophageal candidiasis, the recommended options are:

- Fluconazole 100 to 200 mg PO daily, *or*
- Posaconazole oral solution 400 mg PO twice daily, *or*
- Posaconazole tablet 300 mg PO daily

## Histoplasmosis

Histoplasmosis is a fungal infection caused by *Histoplasma capsulatum*, which is endemic to the Central and South-Central United States (especially the Mississippi and Ohio River Valley areas), as well as to many regions of Latin America.[128,129] *Histoplasma* infections are acquired through inhalation, and asymptomatic extrapulmonary infection is common. Individuals with HIV who have a CD4 count below 150 cells/mm<sup>3</sup> have an increased risk of developing symptomatic illness following acute infection, and most cases in nonendemic areas are attributed to reactivation of latent infection.[130,131] The incidence of symptomatic histoplasmosis declined after the introduction of potent antiretroviral therapy.[1]

### Clinical Manifestations

*Histoplasma* infection can be asymptomatic or symptomatic, acute or chronic, and focal or disseminated. Disseminated disease often develops in persons with HIV, particularly in those who have a CD4 count of less than 150 cells/mm<sup>3</sup>. [129,130] Symptoms of disseminated histoplasmosis may include fever, fatigue, weight loss, hepatosplenomegaly, cough, chest pain, and dyspnea.[132] Approximately 50% of cases include respiratory complaints; chest radiography often shows diffuse or patchy opacities that can mimic *Pneumocystis* pneumonia (Figure 11). Less often, the chest radiograph shows focal infiltrates, nodules, or cavities. Persons with HIV and histoplasmosis may also have hepatosplenomegaly (25%), lymphadenopathy (25%), sepsis (10 to 20%), central nervous system involvement (10 to 20%), or gastrointestinal involvement (10 to 20%).[129] Some with disseminated disease may have oral lesions.[133] In rare situations, individuals with disseminated histoplasmosis may develop hemophagocytic syndrome, also known as hemophagocytic lymphohistiocytosis (HLH), which is a dysregulated immune response to infection that causes a multisystem illness characterized by fever, hepatosplenomegaly, and cytopenias.[134,135]

### Diagnosis

The following summarizes the main laboratory tests used in diagnosing histoplasmosis.

- **Histoplasma Antigen:** Disseminated histoplasmosis in persons with HIV is usually diagnosed by detecting *Histoplasma* antigen in blood or urine (Figure 12).[129,136,137] Results with the *Histoplasma* antigen assay (on urine or serum samples) are typically available in 1 to 2 days. Evaluation of tests for the diagnosis of disseminated histoplasmosis in adults with HIV has shown that sensitivity was 100% with urinary antigen and 92% with serum antigen.[138]
- **Serologic Testing:** Testing for antibodies to *H. capsulatum* is not very useful for the diagnosis of disseminated histoplasmosis in persons with HIV.[136,137,139]
- **Peripheral Blood Smear:** In some cases, peripheral blood smears and biopsy samples of involved tissues may show budding yeasts (Figure 13).[140]
- **Culture:** Although more than 85% of adults with HIV and disseminated histoplasmosis will have a positive culture for *H. capsulatum* from a body source (blood, bone marrow, respiratory secretion, or skin lesions), obtaining a culture has limited clinical diagnostic utility since the organism usually takes several weeks to grow.[137]
- **Bronchoalveolar Lavage Fluid:** The detection of *Histoplasma* antigen in bronchoalveolar lavage fluid may be helpful for the diagnosis of acute pulmonary histoplasmosis infections.[136,141]
- **Cerebrospinal Fluid:** Typical cerebrospinal fluid findings among individuals with *Histoplasma* meningitis include lymphocytic pleocytosis, elevated protein, and low glucose. Confirming a diagnosis of *Histoplasma* meningitis can be challenging due to poor sensitivity of most diagnostic tests—fungal stains are usually negative, and cerebrospinal fungal cultures are positive in less than 40% of individuals. Cerebrospinal fluid testing for *Histoplasma* antibodies and antigen can aid with diagnosing *Histoplasma* meningitis, as detection of either *Histoplasma* antibodies or antigen in the cerebrospinal fluid confirms active central nervous system *Histoplasma* infection.[136,142] Often, a presumptive diagnosis of *Histoplasma* meningitis is made when an individual with CNS infection has evidence of disseminated histoplasmosis at another site and no other obvious etiology for their neurological

symptoms.[136]

## Treatment

The treatment of disseminated histoplasmosis in persons with HIV is based on the severity and type of disease, and level of immunosuppression.[136] Treatment consists of induction therapy, maintenance therapy, and long-term suppressive therapy. The duration of the induction period is at least 2 weeks for treatment of disseminated disease and 6 weeks for treatment of meningitis.[136] Liposomal amphotericin B is the preferred treatment for induction therapy for moderately severe to severe disease and meningitis, whereas itraconazole is preferred for treatment of less severe disseminated disease.[136] Acute pulmonary histoplasmosis in individuals with HIV and a CD4 count greater than 300 cells/mm<sup>3</sup> should be managed the same as immunocompetent individuals.[136,143] The following table summarizes the Adult and Adolescent OI Guidelines recommendations for the treatment of severe disseminated histoplasmosis, less severe histoplasmosis or acute pulmonary histoplasmosis in individuals with a CD4 count less than 300 cells/mm<sup>3</sup>, and *Histoplasma* meningitis (Table 14).[136]

## Monitoring Drug Levels

- **Itraconazole:** Serum itraconazole levels should be checked after 2 weeks of therapy, with a target itraconazole serum level of 1-2 µg/mL.[136] The risk of side effects and toxicities with itraconazole increases with serum levels greater than or equal to 5 µg/mL.[136,144] In general, oral itraconazole liquid formulation (administered on an empty stomach) is better absorbed, albeit less well tolerated, than the oral capsules.
- **Voriconazole:** For persons intolerant of itraconazole, alternative agents include posaconazole, voriconazole, or fluconazole.[145] If voriconazole is used, serum trough levels should be measured 5 days after treatment initiation. The therapeutic level is between 1 and 5 µg/mL; levels higher than 5 µg/mL can lead to drug toxicities, including neurotoxicity and hepatotoxicity.
- **Posaconazole:** Posaconazole serum levels should be measured 5 days after treatment initiation—the therapeutic level is greater than 1 µg/mL.

## Timing of Initiating Antiretroviral Therapy

Individuals diagnosed with histoplasmosis should start on antiretroviral therapy as soon as possible after starting antifungal treatment for histoplasmosis. Available data suggest that IRIS infrequently occurs in persons with HIV who have disseminated histoplasmosis.[136,146]

## Long-Term Suppressive Therapy

For individuals with severe disseminated disease or central nervous system infection, after at least 12 months of maintenance itraconazole therapy, the oral itraconazole dose should be reduced from 200 mg twice daily to 200 mg once daily for long-term suppressive therapy. The alternative for long-term suppressive therapy is oral posaconazole 300 mg daily, oral voriconazole 200 mg twice daily, or oral fluconazole 400 mg daily. The following table addresses the use of long-term suppressive therapy, criteria for discontinuing long-term suppressive therapy, and indications for restarting long-term suppressive therapy (Table 15).[136]

## Coccidiomycosis

Coccidioidomycosis is caused by a soil-dwelling fungus, *Coccidioides immitis*, and may cause a wide spectrum of clinical diseases among individuals with HIV. The risk of developing symptomatic coccidioidomycosis in persons with HIV is significantly increased in persons with a CD4 count less than 250 cells/mm<sup>3</sup> who live (or previously lived) in a region endemic for coccidioidomycosis. In persons with HIV, rates of coccidioidomycosis have been higher in Black individuals than in White persons.[147] The incidence of coccidioidomycosis has decreased in the era of potent antiretroviral therapy.[148]

### Clinical Manifestations

In adults with a CD4 cell count greater than 250 cells/mm<sup>3</sup>, coccidioidomycosis typically presents as an acute or subacute localized pulmonary infection that mimics community-acquired pneumonia. Persons with lower CD4 counts may develop diffuse pneumonia with reticulonodular infiltrates (that may resemble *Pneumocystis* pneumonia) or disseminated extrapulmonary infection that may cause skin lesions, meningitis, or involve lymph nodes or the liver.[149,150,151] Cutaneous findings in acute coccidioidomycosis infection may include erythema multiforme or erythema nodosum, whereas cutaneous findings in disseminated disease may include papules, pustules, nodules, and ulcerated lesions.

### Diagnosis

The initial evaluation of a person with suspected coccidioidomycosis should be guided by the clinical manifestations. The diagnosis is made based on the clinical presentation combined with laboratory testing that may include serologic tests, antigen testing, histologic staining, and fungal cultures.[150,152,153] A definitive diagnosis can be established with a positive culture of the organism from a clinical sample or by detecting spherules on histopathological examination of tissue.[150]

- **Serologic Testing:** For individuals with HIV who have symptoms consistent with coccidioidomycosis, serologic testing is the most frequently used test to make a presumptive diagnosis. A negative serologic test, however, does not exclude the diagnosis, since the formation of antibodies takes several weeks after initial infection.[150] As such, repeat serological testing should be performed every 1 to 2 weeks in individuals without a diagnosis who exhibit a clinical syndrome compatible with coccidioides disease.[150] For persons with HIV who have suspected coccidioidomycosis, the enzyme immunoassay (EIA) for IgG and IgM is the recommended initial diagnostic test, but the sensitivity of this test is significantly reduced in those with a low CD4 count.[150,154] Accordingly, serologic testing should not be considered reliable for ruling out coccidioidomycosis in persons with HIV who have advanced immunosuppression.[149,155] In addition, problems have been reported with false-positive IgM EIA *Coccidioides* serologic tests.[156] If the EIA test is positive (for either IgG or IgM), the result should be confirmed using immunodiffusion or complement fixation tests.[150]
- **Antigen Testing:** A *Coccidioides* antigen test is commercially available and can be performed on urine, serum, or other body fluids of individuals with active disease. This antigen test is most useful for the diagnosis of extra-thoracic disseminated coccidioidomycosis, especially coccidioidal meningitis.[150,155,157,158]
- **Real-Time Polymerase Chain Reaction:** To help establish a diagnosis of coccidioides, real-time PCR (RT-PCR) can be performed on formalin-fixed tissue or unfixed clinical specimens. Although there is a commercially available *Coccidioides* RT-PCR assay, it has not been approved by the FDA for use in people with HIV due to a lack of data in this population.[150,159]
- **Fungal Culture:** The diagnosis of coccidioidomycosis can be confirmed by isolating *C. immitis* from a clinical specimen (bronchoalveolar lavage fluid, cerebrospinal fluid, or tissue sample).[150] When performing fungal cultures in an attempt to isolate *C. immitis*, the microbiology laboratory must have established biocontainment procedures to prevent infection in laboratory staff.
- **Staining:** The diagnosis of coccidioidomycosis can be made by identifying characteristic *Coccidioides* spherules (8 to 10 microns in diameter) that contain multiple endospores (2 to 5 microns in diameter).

Depending on the clinical sample, the staining may be performed on a wet mount (using saline or potassium hydroxide) of a sample or on a histopathology specimen (usually with hematoxylin and eosin staining).

## **Treatment**

### **Initial Treatment**

The Adult and Adolescent OI Guidelines recommended initial treatment of coccidioidomycosis is based on whether the disease is considered mild (e.g., focal pneumonia) or severe (e.g., disseminated or diffuse pulmonary disease) ([Table 16](#)).<sup>[150]</sup> For mild disease, the recommended treatment is fluconazole (400 mg once daily) or itraconazole (200 mg three times daily for 3 days, then twice daily); if bone or joint disease is present, itraconazole is preferred. For severe pulmonary disease or extrapulmonary disease, which both carry high mortality rates, the recommended therapy is amphotericin B deoxycholate (or lipid formulation of amphotericin B).<sup>[149,150]</sup> In persons with severe non-meningeal disease, initial therapy with an amphotericin B preparation should continue until clinical improvement has occurred, and then treatment can be switched to oral fluconazole or oral itraconazole. To treat coccidioidal meningitis, high-dose oral fluconazole (800-1,200 mg once daily) is recommended, in consultation with a specialist.<sup>[150]</sup>

### **Discontinuation of Therapy**

Discontinuation of therapy for coccidioidomycosis depends on the type and severity of the coccidioidomycosis infection, the CD4 cell count, whether virologic suppression on antiretroviral therapy has been achieved, and if continued monitoring for recurrence can be performed using serial chest radiograph and coccidioidal serology ([Table 17](#)).<sup>[150]</sup>

## Cryptosporidiosis

Cryptosporidiosis is an intestinal infection caused by the protozoan parasite *Cryptosporidium* (Figure 14).[160,161] The life cycle of this organism in humans is complex, and all stages of development can take place within a single host.[160] Cryptosporidiosis can be transmitted through contaminated water sources (including swimming pools, lakes, and public water supplies), can persist despite chlorination, and can also be transmitted from person to person, especially among men who have sex with men.[162] In the current HIV era, the incidence of cryptosporidiosis in persons with HIV is very low (less than 1 case per 1,000 person-years).[1,162]

### Clinical Manifestations

The incubation period for cryptosporidiosis is typically 7 to 10 days.[160] Infection of the gastrointestinal tract by *Cryptosporidium* impairs absorption and enhances secretion, typically manifesting as watery diarrhea and often accompanied by nausea, vomiting, and intestinal cramping. The severity and duration of disease depend on the host immune response, ranging from an asymptomatic or mild self-limited illness, to chronic low-level diarrhea, to a profuse cholera-like illness. For persons with HIV, the CD4 cell count is a strong predictor of illness severity (Figure 15).[163] In a retrospective analysis, adults with HIV and self-limited cryptosporidiosis had a mean CD4 count of 312 cells/mm<sup>3</sup> versus a mean CD4 count of 57 cells/mm<sup>3</sup> in those with persistent infection. In some cases, biliary complications (primarily cholangiopathy) can develop from *Cryptosporidium* infection.[164]

### Diagnosis

Diagnostic testing for *Cryptosporidium* should be performed in persons with HIV and acute diarrhea, chronic diarrhea, or biliary tract disease, especially if their CD4 count is less than 200 cells/mm<sup>3</sup>. [160,164] The diagnosis can be made by identifying oocysts in stool or tissue; the recommended test to identify *Cryptosporidium* depends on the available tests at the laboratory used by the clinician (Figure 16).[165]

- **Ova and Parasite Examination of Stool:** Routine ova and parasite testing does not detect *Cryptosporidium* and thus should not be relied on to diagnose *Cryptosporidium*.
- **Modified Acid-Fast Stain:** The modified acid-fast stain, which stains the organism red, is the most common method used to detect *Cryptosporidium* on microscopic examination of a stool sample.
- **Immunofluorescence Antigen Testing:** Many centers now offer detection of *Cryptosporidium* using direct immunofluorescence antigen testing, most often with an enzyme-linked immunoassay (ELISA).
- **Enteric Pathogen PCR Panel:** Some laboratories now have a multiplex enteric pathogen panel for evaluating patients with diarrhea.[166] This test is a molecular assay that utilizes PCR technology. Most of these panels will detect common bacterial, viral, and parasitic pathogens. Many, but not all, include detection of *Cryptosporidium*. These multiplex molecular tests are often better than direct microscopy at detecting *Cryptosporidium*. [167,168,169]

### Treatment

Treatment of cryptosporidiosis includes a combination of antiretroviral therapy-related immune reconstitution, supportive symptomatic therapy, and the use antimicrobial agents that have activity against *Cryptosporidium* (Table 18).[162]

- **Antiretroviral Therapy and Immune Reconstitution:** The most important aspect of treatment for cryptosporidiosis is immune restoration with antiretroviral therapy.
- **Supportive Therapy:** Since immune reconstitution may take months, supportive care plays a vital role in managing symptoms and may include oral rehydration, intravenous rehydration, replacement of electrolytes, and symptomatic treatment of diarrhea.
- **Antimicrobial Therapy:** Antimicrobial treatments have been studied, including nitazoxanide,

paromomycin, or azithromycin, but none of these options has been consistently effective in the absence of antiretroviral therapy.[[170](#),[171](#),[172](#),[173](#),[174](#)] Some experts recommend giving a trial of nitazoxanide or paromomycin in addition to antiretroviral therapy, a recommendation based on a few studies that demonstrated improvement in diarrhea symptoms and reduced parasite burden in individuals with CD4 counts greater than 50 cells/mm<sup>3</sup>. [[162](#),[173](#),[174](#),[175](#)]

- **Timing of Antiretroviral Therapy:** Since antiretroviral therapy is the mainstay of cryptosporidiosis treatment for patients with HIV, antiretroviral therapy should be started as soon as possible after the diagnosis of cryptosporidiosis.

## Cystoisosporiasis (formerly Isosporiasis)

*Cystoisospora belli* (formerly *Isospora belli*) is a parasite that primarily affects immunocompromised persons in tropical and subtropical areas of the world.[176,177] Infection is acquired via the ingestion of food or water that is contaminated with human feces that contain *C. belli* oocysts.[177,178] Most persons with HIV who develop cystoisosporiasis have a CD4 count less than 250 cells/mm<sup>3</sup> and have current or past residence in a highly endemic geographic region. In the United States, most cases of cystoisosporiasis occur in the context of travel or immigration.[179,180,181,182]

### Clinical Manifestations

Individuals with HIV and cystoisosporiasis typically develop watery diarrhea, nausea, vomiting, intestinal cramping, anorexia, and low-grade fever.[180] These symptoms often resemble those seen with other gastrointestinal opportunistic infections in persons with HIV. Several reports have documented cases of extraintestinal disease, including involvement of gallbladder, lymph nodes, and spleen, but such cases are rare.

### Diagnosis

The diagnosis of cystoisosporiasis can be made by direct visualization of a stool sample, using a modified acid-fast stain on that shows oocysts that are relatively large (15 to 20 microns in diameter) (Figure 18).[183] The unsporulated *Cystoisospora* oocysts appear elliptical, with one or both ends slightly tapered.[177] Modified acid-fast staining of a stool sample can identify *C. belli* oocysts. In the early phase, oocysts have an internal granular mass and as they mature, one or two internal sporoblasts may be seen. The *C. belli* oocysts are approximately 30 by 15 microns in size and are distinctly larger and more oval than the *C. parvum* oocysts (4 to 6 microns in diameter) and *Cyclospora* spp. oocysts (6 to 10 microns in diameter).[177] Various techniques, other than modified acid-fast staining, have been used on wet mounts to identify *C. belli*, including bright-field microscopy, differential interference contrast, and ultraviolet fluorescence microscopy.[184] Polymerase chain reaction (PCR) methods, especially quantitative PCR (qPCR) for enteric pathogens, are increasingly used to diagnose *C. belli* due to their speed and ability to detect multiple parasites at once, offering a diagnostic advantage and greater efficiency than traditional microscopy.[184] These methods show high sensitivity (87–100%) and specificity (88–100%).[182,185]

### Treatment

#### Treatment of Acute Infection

Treatment of acute cystoisosporiasis includes supportive care (rehydration and nutritional supplementation) and antimicrobial therapy targeted against *C. belli* (Table 19).[184]

- **Preferred Therapy:** Several treatment studies in persons with HIV showed good responses to trimethoprim-sulfamethoxazole.[180,181,186] Based on available data, the preferred acute therapy consists of trimethoprim-sulfamethoxazole (160/800 mg) 4 times daily for 10 days, with twice-daily dosing considered an acceptable option.[184] Some experts prefer to initiate treatment with trimethoprim-sulfamethoxazole (160/800 mg) twice daily and increase the dose to four times daily—if symptoms worsen or persist—and possibly extend the duration of acute therapy up to 4 weeks.
- **Alternative Therapy:** Alternatives include pyrimethamine or ciprofloxacin.[187] Note that pyrimethamine may not be easily available due to the extremely high cost of this medication.
- **Timing of Initiating Antiretroviral Therapy:** Antiretroviral therapy should be initiated when cystoisosporiasis treatment is started, unless there is concern that the antiretroviral therapy medications will not be absorbed well.[184]

#### Chronic Maintenance Therapy

Individuals with HIV and a CD4 count less than 200 cells/mm<sup>3</sup> have a high rate of relapse with cystoisosporiasis and thus should receive chronic maintenance therapy with trimethoprim-sulfamethoxazole (160/800 mg) dosed either daily for 3 times weekly ([Table 20](#)).<sup>[184]</sup> Pyrimethamine or ciprofloxacin may be options for those unable to take trimethoprim-sulfamethoxazole.<sup>[184]</sup>

### **Discontinuing Chronic Maintenance Therapy**

Chronic maintenance therapy for cystoisosporiasis in persons with HIV can be discontinued if the following criteria are met:

- The person has experienced a sustained increase in CD4 count to above 200 cells/mm<sup>3</sup> for more than 6 months in response to antiretroviral therapy, *and*
- There is no evidence of active *C. belli* infection.

## Summary Points

- Adults with HIV who have a CD4 count below 200 cells/mm<sup>3</sup> are at significant risk of developing *Pneumocystis pneumonia*; the recommended therapy is trimethoprim-sulfamethoxazole, and the use of adjunctive corticosteroids improves survival for individuals with moderate-to-severe disease.
- *Toxoplasma* encephalitis is typically caused by reactivation of latent organisms in persons with a CD4 count below 100 cells/mm<sup>3</sup>. *Toxoplasma* encephalitis is usually a presumptive diagnosis based on characteristic clinical and neuroradiographic findings combined with a positive serum anti-*Toxoplasma* antibody.
- *Mycobacterium avium* complex is a non-tuberculous mycobacterial infection that can cause multiorgan disease in persons with a CD4 count of less than 50 cells/mm<sup>3</sup>. Therapy requires a prolonged course with at least two active drugs.
- Patients with cryptococcal meningitis typically have a CD4 count of less than 100 cells/mm<sup>3</sup>. Initial antifungal therapy with liposomal amphotericin B and flucytosine is recommended for the induction phase. All persons with elevated intracranial pressure should have this managed through serial therapeutic lumbar punctures with CSF removal.
- Cytomegalovirus (CMV) has the potential to cause retinitis in persons with HIV who have a CD4 count below 50 cells/mm<sup>3</sup>. Therapy usually consists of ocular injections of antiviral medications combined with systemic CMV therapy. Persons with HIV can also develop gastrointestinal and neurologic CMV infections.
- Progressive multifocal leukoencephalopathy (PML) is a focal demyelinating disease caused by the JC virus; immune restoration with antiretroviral therapy is the mainstay of therapy.
- Fungal opportunistic infections include *Candida* esophagitis, histoplasmosis and coccidioidomycosis. *Candida* esophagitis is typically treated with a course of oral fluconazole for 2 to 3 weeks whereas severe histoplasmosis and coccidioidomycosis requires initial treatment with liposomal amphotericin B and a longer duration of therapy.
- Multiple intestinal parasites (e.g., *Cryptosporidium*, *Microsporidium*, *Cystoisospora*) can cause intestinal disease in persons with HIV. Treatment generally includes supportive care and antiretroviral therapy to restore immune function.

## Citations

1. Buchacz K, Lau B, Jing Y, et al. Incidence of AIDS-Defining Opportunistic Infections in a Multicohort Analysis of HIV-infected Persons in the United States and Canada, 2000-2010. *J Infect Dis.* 2016;214:862-72.  
[\[PubMed Abstract\]](#) -
2. Buchacz K, Baker RK, Palella FJ Jr, et al. AIDS-defining opportunistic illnesses in US patients, 1994-2007: a cohort study. *AIDS.* 2010;24:1549-59.  
[\[PubMed Abstract\]](#) -
3. Kaplan JE, Hanson D, Dworkin MS, et al. Epidemiology of human immunodeficiency virus-associated opportunistic infections in the United States in the era of highly active antiretroviral therapy. *Clin Infect Dis.* 2000;30 Suppl 1:S5-14.  
[\[PubMed Abstract\]](#) -
4. Panel on Guidelines for the Prevention and Treatment of Opportunistic Infections in Adults and Adolescents with HIV. Guidelines for the prevention and treatment of opportunistic infections in adults and adolescents with HIV. National Institutes of Health, HIV Medicine Association, and Infectious Diseases Society of America.  
[\[HIV.gov\]](#) -
5. Müller M, Wandel S, Colebunders R, Attia S, Furrer H, Egger M. Immune reconstitution inflammatory syndrome in patients starting antiretroviral therapy for HIV infection: a systematic review and meta-analysis. *Lancet Infect Dis.* 2010;10:251-61.  
[\[PubMed Abstract\]](#) -
6. Novak RM, Richardson JT, Buchacz K, et al. Immune reconstitution inflammatory syndrome: incidence and implications for mortality. *AIDS.* 2012;26:721-30.  
[\[PubMed Abstract\]](#) -
7. da Cunha Colombo ER, Mora DJ, Silva-Vergara ML. Immune reconstitution inflammatory syndrome (IRIS) associated with *Cryptococcus neoformans* infection in AIDS patients. *Mycoses.* 2011;54:e178-82.  
[\[PubMed Abstract\]](#) -
8. Manzardo C, Guardo AC, Letang E, Plana M, Gatell JM, Miro JM. Opportunistic infections and immune reconstitution inflammatory syndrome in HIV-1-infected adults in the combined antiretroviral therapy era: a comprehensive review. *Expert Rev Anti Infect Ther.* 2015;13:751-67.  
[\[PubMed Abstract\]](#) -
9. Summers NA, Kelley CF, Armstrong W, Marconi VC, Nguyen ML. Not a Disease of the Past: A Case Series of Progressive Multifocal Leukoencephalopathy in the Established Antiretroviral Era. *AIDS Res Hum Retroviruses.* 2019;35:544-52.  
[\[PubMed Abstract\]](#) -
10. Stringer JR, Beard CB, Miller RF, Wakefield AE. A new name (*Pneumocystis jiroveci*) for *Pneumocystis* from humans. *Emerg Infect Dis.* 2002;8:891-6.  
[\[PubMed Abstract\]](#) -
11. Kaplan JE, Hanson DL, Navin TR, Jones JL. Risk factors for primary *Pneumocystis carinii* pneumonia in human immunodeficiency virus-infected adolescents and adults in the United States: reassessment of indications for chemoprophylaxis. *J Infect Dis.* 1998;178:1126-32.  
[\[PubMed Abstract\]](#) -

12. Phair J, Munoz A, Detels R, Kaslow R, Rinaldo C, Saah A. The risk of *Pneumocystis carinii* pneumonia among men infected with human immunodeficiency virus type 1. Multicenter AIDS Cohort Study Group. *N Engl J Med*. 1990;322:161-5.  
[\[PubMed Abstract\]](#) -
13. Kovacs JA, Masur H. Evolving health effects of *Pneumocystis*: one hundred years of progress in diagnosis and treatment. *JAMA*. 2009;301:2578-85.  
[\[PubMed Abstract\]](#) -
14. Huang L, Cattamanchi A, Davis JL, et al. HIV-associated *Pneumocystis* pneumonia. *Proc Am Thorac Soc*. 2011;8:294-300.  
[\[PubMed Abstract\]](#) -
15. Panel on Guidelines for the Prevention and Treatment of Opportunistic Infections in Adults and Adolescents with HIV. Guidelines for the prevention and treatment of opportunistic infections in adults and adolescents with HIV. National Institutes of Health, HIV Medicine Association, and Infectious Diseases Society of America. *Pneumocystis* Pneumonia. Updated: September 9, 2025.  
[\[HIV.gov\]](#) -
16. Boisselle PM, Crans CA Jr, Kaplan MA. The changing face of *Pneumocystis carinii* pneumonia in AIDS patients. *AJR Am J Roentgenol*. 1999;172:1301-9.  
[\[PubMed Abstract\]](#) -
17. Crans CA Jr, Boisselle PM. Imaging features of *Pneumocystis carinii* pneumonia. *Crit Rev Diagn Imaging*. 1999;40:251-84.  
[\[PubMed Abstract\]](#) -
18. Opravil M, Marincek B, Fuchs WA, et al. Shortcomings of chest radiography in detecting *Pneumocystis carinii* pneumonia. *J Acquir Immune Defic Syndr*. 1994;7:39-45.  
[\[PubMed Abstract\]](#) -
19. Ingram RJ, Call S, Andrade A, White C, Wheeler D. Management and outcome of pneumothoraces in patients infected with human immunodeficiency virus. *Clin Infect Dis*. 1996;23:624-7.  
[\[PubMed Abstract\]](#) -
20. Pastores SM, Garay SM, Naidich DP, Rom WN. Review: pneumothorax in patients with AIDS-related *Pneumocystis carinii* pneumonia. *Am J Med Sci*. 1996;312:229-34.  
[\[PubMed Abstract\]](#) -
21. Kanne JP, Yandow DR, Meyer CA. *Pneumocystis jirovecii* pneumonia: high-resolution CT findings in patients with and without HIV infection. *AJR Am J Roentgenol*. 2012;198:W555-61.  
[\[PubMed Abstract\]](#) -
22. Smith DE, McLuckie A, Wyatt J, Gazzard B. Severe exercise hypoxaemia with normal or near normal X-rays: a feature of *Pneumocystis carinii* infection. *Lancet*. 1988;2:1049-51.  
[\[PubMed Abstract\]](#) -
23. Zaman MK, White DA. Serum lactate dehydrogenase levels and *Pneumocystis carinii* pneumonia. Diagnostic and prognostic significance. *Am Rev Respir Dis*. 1988;137:796-800.  
[\[PubMed Abstract\]](#) -
24. Sax PE, Komarow L, Finkelman MA, et al. Blood (1->3)-beta-D-glucan as a diagnostic test for HIV-related *Pneumocystis jirovecii* pneumonia. *Clin Infect Dis*. 2011;53:197-202.

[\[PubMed Abstract\]](#) -

25. Salerno D, Mushatt D, Myers L, et al. Serum and bal beta-D-glucan for the diagnosis of Pneumocystis pneumonia in HIV positive patients. *Respir Med.* 2014;108:1688-95.  
[\[PubMed Abstract\]](#) -
26. White PL, Backx M, Barnes RA. Diagnosis and management of *Pneumocystis jirovecii* infection. *Expert Rev Anti Infect Ther.* 2017;15:435-47.  
[\[PubMed Abstract\]](#) -
27. Golden JA, Hollander H, Stulbarg MS, Gamsu G. Bronchoalveolar lavage as the exclusive diagnostic modality for *Pneumocystis carinii* pneumonia. A prospective study among patients with acquired immunodeficiency syndrome. *Chest.* 1986;90:18-22.  
[\[PubMed Abstract\]](#) -
28. Kovacs JA, Gill VJ, Meshnick S, Masur H. New insights into transmission, diagnosis, and drug treatment of *Pneumocystis carinii* pneumonia. *JAMA.* 2001;286:2450-60.  
[\[PubMed Abstract\]](#) -
29. Cruciani M, Marcati P, Malena M, Bosco O, Serpelloni G, Mengoli C. Meta-analysis of diagnostic procedures for *Pneumocystis carinii* pneumonia in HIV-1-infected patients. *Eur Respir J.* 2002;20:982-9.  
[\[PubMed Abstract\]](#) -
30. Larsen HH, Masur H, Kovacs JA, et al. Development and evaluation of a quantitative, touch-down, real-time PCR assay for diagnosing *Pneumocystis carinii* pneumonia. *J Clin Microbiol.* 2002;40:490-4.  
[\[PubMed Abstract\]](#) -
31. Torres J, Goldman M, Wheat LJ, et al. Diagnosis of *Pneumocystis carinii* pneumonia in human immunodeficiency virus-infected patients with polymerase chain reaction: a blinded comparison to standard methods. *Clin Infect Dis.* 2000;30:141-5.  
[\[PubMed Abstract\]](#) -
32. Gagnon S, Boota AM, Fischl MA, Baier H, Kirksey OW, La Voie L. Corticosteroids as adjunctive therapy for severe *Pneumocystis carinii* pneumonia in the acquired immunodeficiency syndrome. A double-blind, placebo-controlled trial. *N Engl J Med.* 1990;323:1444-50.  
[\[PubMed Abstract\]](#) -
33. Zolopa A, Andersen J, Powderly W, et al. Early antiretroviral therapy reduces AIDS progression/death in individuals with acute opportunistic infections: a multicenter randomized strategy trial. *PLoS One.* 2009;4:e5575  
[\[PubMed Abstract\]](#) -
34. Luft BJ, Remington JS. Toxoplasmic encephalitis in AIDS. *Clin Infect Dis.* 1992;15:211-22.  
[\[PubMed Abstract\]](#) -
35. Porter SB, Sande MA. Toxoplasmosis of the central nervous system in the acquired immunodeficiency syndrome. *N Engl J Med.* 1992;327:1643-8.  
[\[PubMed Abstract\]](#) -
36. Panel on Guidelines for the Prevention and Treatment of Opportunistic Infections in Adults and Adolescents with HIV. Guidelines for the prevention and treatment of opportunistic infections in adults and adolescents with HIV. National Institutes of Health, HIV Medicine Association, and Infectious Diseases Society of America. *Toxoplasmosis.* Updated: September 9, 2025.

[\[HIV.gov\]](#) -

37. Rabaud C, May T, Amiel C, Katlama C, Leport C, Ambroise-Thomas P, Canton P. Extracerebral toxoplasmosis in patients infected with HIV. A French National Survey. *Medicine (Baltimore)*. 1994;73:306-14.  
[\[PubMed Abstract\]](#) -
38. Cingolani A, De Luca A, Ammassari A, Murri R, Linzalone A, Grillo R, Antinori A. PCR detection of *Toxoplasma gondii* DNA in CSF for the differential diagnosis of AIDS-related focal brain lesions. *J Med Microbiol*. 1996;45:472-6.  
[\[PubMed Abstract\]](#) -
39. Novati R, Castagna A, Morsica G, et al. Polymerase chain reaction for *Toxoplasma gondii* DNA in the cerebrospinal fluid of AIDS patients with focal brain lesions. *AIDS*. 1994;8:1691-4.  
[\[PubMed Abstract\]](#) -
40. Antinori A, Ammassari A, De Luca A, et al. Diagnosis of AIDS-related focal brain lesions: a decision-making analysis based on clinical and neuroradiologic characteristics combined with polymerase chain reaction assays in CSF. *Neurology*. 1997;48:687-94.  
[\[PubMed Abstract\]](#) -
41. Cinque P, Scarpellini P, Vago L, Linde A, Lazzarin A. Diagnosis of central nervous system complications in HIV-infected patients: cerebrospinal fluid analysis by the polymerase chain reaction. *AIDS*. 1997;11:1-17.  
[\[PubMed Abstract\]](#) -
42. Dannemann B, McCutchan JA, Israelski D, et al. Treatment of toxoplasmic encephalitis in patients with AIDS. A randomized trial comparing pyrimethamine plus clindamycin to pyrimethamine plus sulfadiazine. The California Collaborative Treatment Group. *Ann Intern Med*. 1992;116:33-43.  
[\[PubMed Abstract\]](#) -
43. Katlama C, De Wit S, O'Doherty E, Van Glabeke M, Clumeck N. Pyrimethamine-clindamycin vs. pyrimethamine-sulfadiazine as acute and long-term therapy for toxoplasmic encephalitis in patients with AIDS. *Clin Infect Dis*. 1996;22:268-75.  
[\[PubMed Abstract\]](#) -
44. Gallant J. Get Rich Quick With Old Generic Drugs! The Pyrimethamine Pricing Scandal. *Open Forum Infect Dis*. 2015;2:ofv177.  
[\[PubMed Abstract\]](#) -
45. Luft BJ, Hafner R, Korzun AH, et al. Toxoplasmic encephalitis in patients with the acquired immunodeficiency syndrome. Members of the ACTG 077p/ANRS 009 Study Team. *N Engl J Med*. 1993;329:995-1000.  
[\[PubMed Abstract\]](#) -
46. Miro JM, Lopez JC, Podzamczar D, et al. Discontinuation of primary and secondary *Toxoplasma gondii* prophylaxis is safe in HIV-infected patients after immunological restoration with highly active antiretroviral therapy: results of an open, randomized, multicenter clinical trial. *Clin Infect Dis*. 2006;43:79-89.  
[\[PubMed Abstract\]](#) -
47. Uthman MM, Uthman OA, Yahaya I. Interventions for the prevention of *Mycobacterium avium* complex in adults and children with HIV. *Cochrane Database Syst Rev*. 2013;:CD007191.  
[\[PubMed Abstract\]](#) -

48. Panel on Guidelines for the Prevention and Treatment of Opportunistic Infections in Adults and Adolescents with HIV. Guidelines for the prevention and treatment of opportunistic infections in adults and adolescents with HIV. National Institutes of Health, HIV Medicine Association, and Infectious Diseases Society of America. *Mycobacterium avium* complex disease. Updated: August 15, 2024. [[HIV.gov](#)] -
49. Nightingale SD, Byrd LT, Southern PM, Jockusch JD, Cal SX, Wynne BA. Incidence of *Mycobacterium avium-intracellulare* complex bacteremia in human immunodeficiency virus-positive patients. *J Infect Dis.* 1992;165:1082-5. [[PubMed Abstract](#)] -
50. Karakousis PC, Moore RD, Chaisson RE. *Mycobacterium avium* complex in patients with HIV infection in the era of highly active antiretroviral therapy. *Lancet Infect Dis.* 2004;4:557-65. [[PubMed Abstract](#)] -
51. Horsburgh CR Jr. The pathophysiology of disseminated *Mycobacterium avium* complex disease in AIDS. *J Infect Dis.* 1999;179 Suppl 3:S461-5. [[PubMed Abstract](#)] -
52. Gordin FM, Cohn DL, Sullam PM, Schoenfelder JR, Wynne BA, Horsburgh CR Jr. Early manifestations of disseminated *Mycobacterium avium* complex disease: a prospective evaluation. *J Infect Dis.* 1997;176:126-32. [[PubMed Abstract](#)] -
53. Shafran SD. Prevention and treatment of disseminated *Mycobacterium avium* complex infection in human immunodeficiency virus-infected individuals. *Int J Infect Dis.* 1998;3:39-47. [[PubMed Abstract](#)] -
54. Nyberg DA, Federle MP, Jeffrey RB, Bottles K, Wofsy CB. Abdominal CT findings of disseminated *Mycobacterium avium-intracellulare* in AIDS. *AJR Am J Roentgenol.* 1985;145:297-9. [[PubMed Abstract](#)] -
55. Hafner R, Inderlied CB, Peterson DM, et al. Correlation of quantitative bone marrow and blood cultures in AIDS patients with disseminated *Mycobacterium avium* complex infection. *J Infect Dis.* 1999;180:438-47. [[PubMed Abstract](#)] -
56. Shanson DC, Dryden MS. Comparison of methods for isolating *Mycobacterium avium-intracellulare* from blood of patients with AIDS. *J Clin Pathol.* 1988;41:687-90. [[PubMed Abstract](#)] -
57. Ward TT, Rimland D, Kauffman C, Huycke M, Evans TG, Heifets L. Randomized, open-label trial of azithromycin plus ethambutol vs. clarithromycin plus ethambutol as therapy for *Mycobacterium avium* complex bacteremia in patients with human immunodeficiency virus infection. Veterans Affairs HIV Research Consortium. *Clin Infect Dis.* 1998;27:1278-85. [[PubMed Abstract](#)] -
58. Shafran SD, Singer J, Zarowny DP, et al. A comparison of two regimens for the treatment of *Mycobacterium avium* complex bacteremia in AIDS: rifabutin, ethambutol, and clarithromycin versus rifampin, ethambutol, clofazimine, and ciprofloxacin. Canadian HIV Trials Network Protocol 010 Study Group. *N Engl J Med.* 1996;335:377-83. [[PubMed Abstract](#)] -

59. Dunne M, Fessel J, Kumar P, et al. A randomized, double-blind trial comparing azithromycin and clarithromycin in the treatment of disseminated *Mycobacterium avium* infection in patients with human immunodeficiency virus. *Clin Infect Dis*. 2000;31:1245-52.  
[\[PubMed Abstract\]](#) -
60. Phillips P, Bonner S, Gataric N, et al. Nontuberculous mycobacterial immune reconstitution syndrome in HIV-infected patients: spectrum of disease and long-term follow-up. *Clin Infect Dis*. 2005;41:1483-97.  
[\[PubMed Abstract\]](#) -
61. McKenney J, Bauman S, Neary B, et al. Prevalence, correlates, and outcomes of cryptococcal antigen positivity among patients with AIDS, United States, 1986-2012. *Clin Infect Dis*. 2014;60:959-65.  
[\[PubMed Abstract\]](#) -
62. Panel on Guidelines for the Prevention and Treatment of Opportunistic Infections in Adults and Adolescents with HIV. Guidelines for the prevention and treatment of opportunistic infections in adults and adolescents with HIV. National Institutes of Health, HIV Medicine Association, and Infectious Diseases Society of America. Cryptococcosis. Updated: October 29, 2024.  
[\[HIV.gov\]](#) -
63. Mirza SA, Phelan M, Rimland D, et al. The changing epidemiology of cryptococcosis: an update from population-based active surveillance in 2 large metropolitan areas, 1992-2000. *Clin Infect Dis*. 2003;36:789-94.  
[\[PubMed Abstract\]](#) -
64. Darras-Joly C, Chevret S, Wolff M, et al. *Cryptococcus neoformans* infection in France: epidemiologic features of and early prognostic parameters for 76 patients who were infected with human immunodeficiency virus. *Clin Infect Dis*. 1996;23:369-76.  
[\[PubMed Abstract\]](#) -
65. Murakawa GJ, Kerschmann R, Berger T. Cutaneous *Cryptococcus* infection and AIDS. Report of 12 cases and review of the literature. *Arch Dermatol*. 1996;132:545-8.  
[\[PubMed Abstract\]](#) -
66. Chuck SL, Sande MA. Infections with *Cryptococcus neoformans* in the acquired immunodeficiency syndrome. *N Engl J Med*. 1989;321:794-9.  
[\[PubMed Abstract\]](#) -
67. van der Horst CM, Saag MS, Cloud GA, et al. Treatment of cryptococcal meningitis associated with the acquired immunodeficiency syndrome. National Institute of Allergy and Infectious Diseases Mycoses Study Group and AIDS Clinical Trials Group. *N Engl J Med*. 1997;337:15-21.  
[\[PubMed Abstract\]](#) -
68. Tanner DC, Weinstein MP, Fedorciw B, Joho KL, Thorpe JJ, Reller L. Comparison of commercial kits for detection of cryptococcal antigen. *J Clin Microbiol*. 1994;32:1680-4.  
[\[PubMed Abstract\]](#) -
69. Graybill JR, Sobel J, Saag M, et al. Diagnosis and management of increased intracranial pressure in patients with AIDS and cryptococcal meningitis. The NIAID Mycoses Study Group and AIDS Cooperative Treatment Groups. *Clin Infect Dis*. 2000;30:47-54.  
[\[PubMed Abstract\]](#) -
70. Powderly WG, Cloud GA, Dismukes WE, Saag MS. Measurement of cryptococcal antigen in serum and cerebrospinal fluid: value in the management of AIDS-associated cryptococcal meningitis. *Clin Infect*

Dis. 1994;18:789-92.

[\[PubMed Abstract\]](#) -

71. Hamill RJ, Sobel JD, El-Sadr W, et al. Comparison of 2 doses of liposomal amphotericin B and conventional amphotericin B deoxycholate for treatment of AIDS-associated acute cryptococcal meningitis: a randomized, double-blind clinical trial of efficacy and safety. *Clin Infect Dis.* 2010;51:225-32.  
[\[PubMed Abstract\]](#) -
72. Jarvis JN, Lawrence DS, Meya DB, et al. Single-Dose Liposomal Amphotericin B Treatment for Cryptococcal Meningitis. *N Engl J Med.* 2022;386:1109-20.  
[\[PubMed Abstract\]](#) -
73. Bozzette SA, Larsen RA, Chiu J, et al. A placebo-controlled trial of maintenance therapy with fluconazole after treatment of cryptococcal meningitis in the acquired immunodeficiency syndrome. California Collaborative Treatment Group. *N Engl J Med.* 1991;324:580-4.  
[\[PubMed Abstract\]](#) -
74. Rolfes MA, Hullsiek KH, Rhein J, et al. The effect of therapeutic lumbar punctures on acute mortality from cryptococcal meningitis. *Clin Infect Dis.* 2014;59:1607-14.  
[\[PubMed Abstract\]](#) -
75. Fessler RD, Sobel J, Guyot L, et al. Management of elevated intracranial pressure in patients with Cryptococcal meningitis. *J Acquir Immune Defic Syndr Hum Retrovirol.* 1998;17:137-42.  
[\[PubMed Abstract\]](#) -
76. Aberg JA, Watson J, Segal M, Chang LW. Clinical utility of monitoring serum cryptococcal antigen (sCRAG) titers in patients with AIDS-related cryptococcal disease. *HIV Clin Trials.* 2000;1:1-6.  
[\[PubMed Abstract\]](#) -
77. Shelburne SA 3rd, Darcourt J, White AC Jr, Greenberg SB, Hamill RJ, Atmar RL, Visnegarwala F. The role of immune reconstitution inflammatory syndrome in AIDS-related *Cryptococcus neoformans* disease in the era of highly active antiretroviral therapy. *Clin Infect Dis.* 2005;40:1049-52.  
[\[PubMed Abstract\]](#) -
78. Boulware DR, Meya DB, Muzoora C, et al. Timing of antiretroviral therapy after diagnosis of cryptococcal meningitis. *N Engl J Med.* 2014;370:2487-98.  
[\[PubMed Abstract\]](#) -
79. Makadzange AT, Ndhlovu CE, Takarinda K, et al. Early versus delayed initiation of antiretroviral therapy for concurrent HIV infection and cryptococcal meningitis in sub-saharan Africa. *Clin Infect Dis.* 2010;50:1532-8.  
[\[PubMed Abstract\]](#) -
80. Njei B, Kongnyuy EJ, Kumar S, Okwen MP, Sankar MJ, Mbuagbaw L. Optimal timing for antiretroviral therapy initiation in patients with HIV infection and concurrent cryptococcal meningitis. *Cochrane Database Syst Rev.* 2013;2:CD009012.  
[\[PubMed Abstract\]](#) -
81. Saag MS, Cloud GA, Graybill JR, et al. A comparison of itraconazole versus fluconazole as maintenance therapy for AIDS-associated cryptococcal meningitis. National Institute of Allergy and Infectious Diseases Mycoses Study Group. *Clin Infect Dis.* 1999;28:291-6.  
[\[PubMed Abstract\]](#) -

82. Powderly WG, Saag MS, Cloud GA, et al. A controlled trial of fluconazole or amphotericin B to prevent relapse of cryptococcal meningitis in patients with the acquired immunodeficiency syndrome. The NIAID AIDS Clinical Trials Group and Mycoses Study Group. *N Engl J Med.* 1992;326:793-8.  
[\[PubMed Abstract\]](#) -
83. Kuppermann BD, Petty JG, Richman DD, Mathews WC, Fullerton SC, Rickman LS, Freeman WR. Correlation between CD4+ counts and prevalence of cytomegalovirus retinitis and human immunodeficiency virus-related noninfectious retinal vasculopathy in patients with acquired immunodeficiency syndrome. *Am J Ophthalmol.* 1993;115:575-82.  
[\[PubMed Abstract\]](#) -
84. Whitley RJ, Jacobson MA, Friedberg DN, et al. Guidelines for the treatment of cytomegalovirus diseases in patients with AIDS in the era of potent antiretroviral therapy: recommendations of an international panel. International AIDS Society-USA. *Arch Intern Med.* 1998;158:957-69.  
[\[PubMed Abstract\]](#) -
85. Schwarcz L, Chen MJ, Vittinghoff E, Hsu L, Schwarcz S. Declining incidence of AIDS-defining opportunistic illnesses: results from 16 years of population-based AIDS surveillance. *AIDS.* 2013;27:597-605.  
[\[PubMed Abstract\]](#) -
86. Panel on Guidelines for the Prevention and Treatment of Opportunistic Infections in Adults and Adolescents with HIV. Guidelines for the prevention and treatment of opportunistic infections in adults and adolescents with HIV. National Institutes of Health, HIV Medicine Association, and Infectious Diseases Society of America. Cytomegalovirus disease. Updated: July 14, 2025.  
[\[HIV.gov\]](#) -
87. Wohl DA, Kendall MA, Andersen J, et al. Low rate of CMV end-organ disease in HIV-infected patients despite low CD4+ cell counts and CMV viremia: results of ACTG protocol A5030. *HIV Clin Trials.* 2009;10:143-52.  
[\[PubMed Abstract\]](#) -
88. Au Eong KG, Beatty S, Charles SJ. Cytomegalovirus retinitis in patients with acquired immune deficiency syndrome. *Postgrad Med J.* 1999;75:585-90.  
[\[PubMed Abstract\]](#) -
89. Jabs DA, Van Natta ML, Holbrook JT, Kempen JH, Meinert CL, Davis MD. Longitudinal study of the ocular complications of AIDS: 1. Ocular diagnoses at enrollment. *Ophthalmology.* 2007;114:780-6.  
[\[PubMed Abstract\]](#) -
90. Wilcox CM, Diehl DL, Cello JP, Margaretten W, Jacobson MA. Cytomegalovirus esophagitis in patients with AIDS. A clinical, endoscopic, and pathologic correlation. *Ann Intern Med.* 1990;113:589-93.  
[\[PubMed Abstract\]](#) -
91. DeRodriguez CV, Fuhrer J, Lake-Bakaar G. Cytomegalovirus colitis in patients with acquired immunodeficiency syndrome. *J R Soc Med.* 1994;87:203-5.  
[\[PubMed Abstract\]](#) -
92. Dieterich DT, Rahmin M. Cytomegalovirus colitis in AIDS: presentation in 44 patients and a review of the literature. *J Acquir Immune Defic Syndr.* 1991;4 Suppl 1:S29-35.  
[\[PubMed Abstract\]](#) -
93. Arribas JR, Clifford DB, Fichtenbaum CJ, Commins DL, Powderly WG, Storch GA. Level of cytomegalovirus (CMV) DNA in cerebrospinal fluid of subjects with AIDS and CMV infection of the

- central nervous system. *J Infect Dis.* 1995;172:527-31.  
[\[PubMed Abstract\]](#) -
94. Wolf DG, Spector SA. Diagnosis of human cytomegalovirus central nervous system disease in AIDS patients by DNA amplification from cerebrospinal fluid. *J Infect Dis.* 1992;166:1412-5.  
[\[PubMed Abstract\]](#) -
95. Goldberg DE, Smithen LM, Angelilli A, Freeman WR. HIV-associated retinopathy in the HAART era. *Retina.* 2005;25:633-49; quiz 682-3.  
[\[PubMed Abstract\]](#) -
96. Karavellas MP, Plummer DJ, Macdonald JC, et al. Incidence of immune recovery vitritis in cytomegalovirus retinitis patients following institution of successful highly active antiretroviral therapy. *J Infect Dis.* 1999;179:697-700.  
[\[PubMed Abstract\]](#) -
97. Karavellas MP, Song M, Macdonald JC, Freeman WR. Long-term posterior and anterior segment complications of immune recovery uveitis associated with cytomegalovirus retinitis. *Am J Ophthalmol.* 2000;130:57-64.  
[\[PubMed Abstract\]](#) -
98. Nguyen QD, Kempen JH, Bolton SG, Dunn JP, Jabs DA. Immune recovery uveitis in patients with AIDS and cytomegalovirus retinitis after highly active antiretroviral therapy. *Am J Ophthalmol.* 2000;129:634-9.  
[\[PubMed Abstract\]](#) -
99. Karavellas MP, Azen SP, MacDonald JC, et al. Immune recovery vitritis and uveitis in AIDS: clinical predictors, sequelae, and treatment outcomes. *Retina.* 2001;21:1-9.  
[\[PubMed Abstract\]](#) -
100. Morrison VL, Kozak I, LaBree LD, Azen SP, Kayicioglu OO, Freeman WR. Intravitreal triamcinolone acetonide for the treatment of immune recovery uveitis macular edema. *Ophthalmology.* 2007;114:334-9.  
[\[PubMed Abstract\]](#) -
101. Kuritzkes DR, Parenti D, Ward DJ, et al. Filgrastim prevents severe neutropenia and reduces infective morbidity in patients with advanced HIV infection: results of a randomized, multicenter, controlled trial. G-CSF 930101 Study Group. *AIDS.* 1998;12:65-74.  
[\[PubMed Abstract\]](#) -
102. Ortega-Larrocea G, Espinosa E, Reyes-Terán G. Lower incidence and severity of cytomegalovirus-associated immune recovery uveitis in HIV-infected patients with delayed highly active antiretroviral therapy. *AIDS.* 2005;19:735-8.  
[\[PubMed Abstract\]](#) -
103. Ferenczy MW, Marshall LJ, Nelson CD, et al. Molecular biology, epidemiology, and pathogenesis of progressive multifocal leukoencephalopathy, the JC virus-induced demyelinating disease of the human brain. *Clin Microbiol Rev.* 2012;25:471-506.  
[\[PubMed Abstract\]](#) -
104. Weissert R. Progressive multifocal leukoencephalopathy. *J Neuroimmunol.* 2011;231:73-7.  
[\[PubMed Abstract\]](#) -
105. Khanna N, Elzi L, Mueller NJ, et al. Incidence and outcome of progressive multifocal

- leukoencephalopathy over 20 years of the Swiss HIV Cohort Study. Clin Infect Dis. 2009;48:1459-66.  
[\[PubMed Abstract\]](#) -
106. Pavlovic D, Patera AC, Nyberg F, Gerber M, Liu M. Progressive multifocal leukoencephalopathy: current treatment options and future perspectives. Ther Adv Neurol Disord. 2015;8:255-73.  
[\[PubMed Abstract\]](#) -
107. Engsig FN, Hansen AB, Omland LH, et al. Incidence, clinical presentation, and outcome of progressive multifocal leukoencephalopathy in HIV-infected patients during the highly active antiretroviral therapy era: a nationwide cohort study. J Infect Dis. 2009;199:77-83.  
[\[PubMed Abstract\]](#) -
108. Berger JR, Kaszovitz B, Post MJ, Dickinson G. Progressive multifocal leukoencephalopathy associated with human immunodeficiency virus infection. A review of the literature with a report of sixteen cases. Ann Intern Med. 1987;107:78-87.  
[\[PubMed Abstract\]](#) -
109. Zunt JR, Tu RK, Anderson DM, Copass MC, Marra CM. Progressive multifocal leukoencephalopathy presenting as human immunodeficiency virus type 1 (HIV)-associated dementia. Neurology. 1997;49:263-5.  
[\[PubMed Abstract\]](#) -
110. Khoury MN, Alsop DC, Agnihotri SP, et al. Hyperintense cortical signal on magnetic resonance imaging reflects focal leukocortical encephalitis and seizure risk in progressive multifocal leukoencephalopathy. Ann Neurol. 2014;75:659-69.  
[\[PubMed Abstract\]](#) -
111. Lima MA, Drislane FW, Koralnik IJ. Seizures and their outcome in progressive multifocal leukoencephalopathy. Neurology. 2006;66:262-4.  
[\[PubMed Abstract\]](#) -
112. Panel on Guidelines for the Prevention and Treatment of Opportunistic Infections in Adults and Adolescents with HIV. Guidelines for the prevention and treatment of opportunistic infections in adults and adolescents with HIV. National Institutes of Health, HIV Medicine Association, and Infectious Diseases Society of America. Progressive multifocal leukoencephalopathy/JC virus infection. Last updated: October 19, 2022.  
[\[HIV.gov\]](#) -
113. Ferretti F, Bestetti A, Yiannoutsos CT, et al. Diagnostic and Prognostic Value of JC Virus DNA in Plasma in Progressive Multifocal Leukoencephalopathy. Clin Infect Dis. 2018;67:65-72.  
[\[PubMed Abstract\]](#) -
114. Antinori A, Cingolani A, Lorenzini P, et al. Clinical epidemiology and survival of progressive multifocal leukoencephalopathy in the era of highly active antiretroviral therapy: data from the Italian Registry Investigative Neuro AIDS (IRINA). J Neurovirol. 2003;9 Suppl 1:47-53.  
[\[PubMed Abstract\]](#) -
115. Klein RS, Harris CA, Small CB, Moll B, Lesser M, Friedland GH. Oral candidiasis in high-risk patients as the initial manifestation of the acquired immunodeficiency syndrome. N Engl J Med. 1984;311:354-8.  
[\[PubMed Abstract\]](#) -
116. Thompson GR 3rd, Patel PK, Kirkpatrick WR, et al. Oropharyngeal candidiasis in the era of antiretroviral therapy. Oral Surg Oral Med Oral Pathol Oral Radiol Endod. 2010;109:488-95.  
[\[PubMed Abstract\]](#) -

117. Rex JH, Rinaldi MG, Pfaller MA. Resistance of *Candida* species to fluconazole. *Antimicrob Agents Chemother.* 1995;39:1-8.  
[\[PubMed Abstract\]](#) -
118. Fichtenbaum CJ, Koletar S, Yiannoutsos C, et al. Refractory mucosal candidiasis in advanced human immunodeficiency virus infection. *Clin Infect Dis.* 2000;30:749-56.  
[\[PubMed Abstract\]](#) -
119. Maenza JR, Merz WG, Romagnoli MJ, Keruly JC, Moore RD, Gallant JE. Infection due to fluconazole-resistant *Candida* in patients with AIDS: prevalence and microbiology. *Clin Infect Dis.* 1997;24:28-34.  
[\[PubMed Abstract\]](#) -
120. Panel on Guidelines for the Prevention and Treatment of Opportunistic Infections in Adults and Adolescents with HIV. Guidelines for the prevention and treatment of opportunistic infections in adults and adolescents with HIV. National Institutes of Health, HIV Medicine Association, and Infectious Diseases Society of America. *Candidiasis (Mucocutaneous).* September 16, 2024.  
[\[HIV.gov\]](#) -
121. Vazquez JA. Optimal management of oropharyngeal and esophageal candidiasis in patients living with HIV infection. *HIV AIDS (Auckl).* 2010;2:89-101.  
[\[PubMed Abstract\]](#) -
122. Wilcox CM, Alexander LN, Clark WS, Thompson SE 3rd. Fluconazole compared with endoscopy for human immunodeficiency virus-infected patients with esophageal symptoms. *Gastroenterology.* 1996;110:1803-9.  
[\[PubMed Abstract\]](#) -
123. Wilcox CM, Darouiche RO, Laine L, Moskovitz BL, Mallegol I, Wu J. A randomized, double-blind comparison of itraconazole oral solution and fluconazole tablets in the treatment of esophageal candidiasis. *J Infect Dis.* 1997;176:227-32.  
[\[PubMed Abstract\]](#) -
124. Phillips P, De Beule K, Frechette G, et al. A double-blind comparison of itraconazole oral solution and fluconazole capsules for the treatment of oropharyngeal candidiasis in patients with AIDS. *Clin Infect Dis.* 1998;26:1368-73.  
[\[PubMed Abstract\]](#) -
125. Alsaad AM, Kaplan YC, Koren G. Exposure to fluconazole and risk of congenital malformations in the offspring: A systematic review and meta-analysis. *Reprod Toxicol.* 2015;52:78-82.  
[\[PubMed Abstract\]](#) -
126. Mølgaard-Nielsen D, Pasternak B, Hviid A. Use of oral fluconazole during pregnancy and the risk of birth defects. *N Engl J Med.* 2013;369:830-9.  
[\[PubMed Abstract\]](#) -
127. Mølgaard-Nielsen D, Svanström H, Melbye M, Hviid A, Pasternak B. Association Between Use of Oral Fluconazole During Pregnancy and Risk of Spontaneous Abortion and Stillbirth. *JAMA.* 2016;315:58-67.  
[\[PubMed Abstract\]](#) -
128. Hajjeh RA. Disseminated histoplasmosis in persons infected with human immunodeficiency virus. *Clin Infect Dis.* 1995 Aug;21 Suppl 1:S108-10.  
[\[PubMed Abstract\]](#) -

129. Wheat J. Endemic mycoses in AIDS: a clinical review. *Clin Microbiol Rev.* 1995;8:146-59.  
[\[PubMed Abstract\]](#) -
130. McKinsey DS, Spiegel RA, Hutwagner L, et al. Prospective study of histoplasmosis in patients infected with human immunodeficiency virus: incidence, risk factors and pathophysiology. *Clin Infect Dis.* 1997;24:1195-203.  
[\[PubMed Abstract\]](#) -
131. Wheat LJ, Connolly-Stringfield PA, Baker RL, et al. Disseminated histoplasmosis in the acquired immune deficiency syndrome: clinical findings, diagnosis and treatment, and review of the literature. *Medicine (Baltimore).* 1990;69:361-74.  
[\[PubMed Abstract\]](#) -
132. Kauffman CA. Histoplasmosis: a clinical and laboratory update. *Clin Microbiol Rev.* 2007;20:115-32.  
[\[PubMed Abstract\]](#) -
133. Hendren N, Yek C, Mull J, Cutrell JB. Disseminated histoplasmosis presenting as multiple oral ulcers. *BMJ Case Rep.* 2017;2017:.  
[\[PubMed Abstract\]](#) -
134. Subedee A, Van Sickels N. Hemophagocytic Syndrome in the Setting of AIDS and Disseminated Histoplasmosis: Case Report and a Review of Literature. *J Int Assoc Provid AIDS Care.* 2015;14:391-7.  
[\[PubMed Abstract\]](#) -
135. Townsend JL, Shanbhag S, Hancock J, Bowman K, Nijhawan AE. Histoplasmosis-Induced Hemophagocytic Syndrome: A Case Series and Review of the Literature. *Open Forum Infect Dis.* 2015 Apr;2:ofv055.  
[\[PubMed Abstract\]](#) -
136. Panel on Guidelines for the Prevention and Treatment of Opportunistic Infections in Adults and Adolescents with HIV. Guidelines for the prevention and treatment of opportunistic infections in adults and adolescents with HIV. National Institutes of Health, HIV Medicine Association, and Infectious Diseases Society of America. Histoplasmosis. Last updated: October 29, 2024.  
[\[HIV.gov\]](#) -
137. Wheat LJ. Approach to the diagnosis of the endemic mycoses. *Clin Chest Med.* 2009;30:379-89.  
[\[PubMed Abstract\]](#) -
138. Connolly PA, Durkin MM, Lemonte AM, Hackett EJ, Wheat LJ. Detection of histoplasma antigen by a quantitative enzyme immunoassay. *Clin Vaccine Immunol.* 2007;14:1587-91.  
[\[PubMed Abstract\]](#) -
139. Tobón AM, Agudelo CA, Rosero DS, et al. Disseminated histoplasmosis: a comparative study between patients with acquired immunodeficiency syndrome and non-human immunodeficiency virus-infected individuals. *Am J Trop Med Hyg.* 2005;73:576-82.  
[\[PubMed Abstract\]](#) -
140. Edelman M, Mckitrick J. Images in clinical medicine. *Histoplasma capsulatum* in a peripheral-blood smear. *N Engl J Med.* 2000;342:28.  
[\[PubMed Abstract\]](#) -
141. Hage CA, Davis TE, Fuller D, et al. Diagnosis of histoplasmosis by antigen detection in BAL fluid. *Chest.* 2010;137:623-8.  
[\[PubMed Abstract\]](#) -

142. Wheat J, Myint T, Guo Y, et al. Central nervous system histoplasmosis: Multicenter retrospective study on clinical features, diagnostic approach and outcome of treatment. *Medicine (Baltimore)*. 2018;97:e0245.  
[\[PubMed Abstract\]](#) -
143. Limper AH, Knox KS, Sarosi GA, et al. An official American Thoracic Society statement: Treatment of fungal infections in adult pulmonary and critical care patients. *Am J Respir Crit Care Med*. 2011;183:96-128.  
[\[PubMed Abstract\]](#) -
144. Lestner JM, Roberts SA, Moore CB, Howard SJ, Denning DW, Hope WW. Toxicodynamics of itraconazole: implications for therapeutic drug monitoring. *Clin Infect Dis*. 2009;49:928-30.  
[\[PubMed Abstract\]](#) -
145. Wheat J, MaWhinney S, Hafner R, et al. Treatment of histoplasmosis with fluconazole in patients with acquired immunodeficiency syndrome. National Institute of Allergy and Infectious Diseases Acquired Immunodeficiency Syndrome Clinical Trials Group and Mycoses Study Group. *Am J Med*. 1997;103:223-32.  
[\[PubMed Abstract\]](#) -
146. Nacher M, Sarazin F, El Guedj M, et al. Increased incidence of disseminated histoplasmosis following highly active antiretroviral therapy initiation. *J Acquir Immune Defic Syndr*. 2006;41:468-70.  
[\[PubMed Abstract\]](#) -
147. Woods CW, McRill C, Plikaytis BD, et al. Coccidioidomycosis in human immunodeficiency virus-infected persons in Arizona, 1994-1997: incidence, risk factors, and prevention. *J Infect Dis*. 2000;181:1428-34.  
[\[PubMed Abstract\]](#) -
148. Masannat FY, Ampel NM. Coccidioidomycosis in patients with HIV-1 infection in the era of potent antiretroviral therapy. *Clin Infect Dis*. 2010;50:1-7.  
[\[PubMed Abstract\]](#) -
149. Ampel NM. Coccidioidomycosis in persons infected with HIV type 1. *Clin Infect Dis*. 2005;41:1174-8.  
[\[PubMed Abstract\]](#) -
150. Panel on Guidelines for the Prevention and Treatment of Opportunistic Infections in Adults and Adolescents with HIV. Guidelines for the prevention and treatment of opportunistic infections in adults and adolescents with HIV. National Institutes of Health, HIV Medicine Association, and Infectious Diseases Society of America. Coccidioidomycosis. Updated: October 29, 2024.  
[\[HIV.gov\]](#) -
151. Singh VR, Smith DK, Lawrence J, et al. Coccidioidomycosis in patients infected with human immunodeficiency virus: review of 91 cases at a single institution. *Clin Infect Dis*. 1996;23:563-8.  
[\[PubMed Abstract\]](#) -
152. Stockamp NW, Thompson GR 3rd. Coccidioidomycosis. *Infect Dis Clin North Am*. 2016;30:229-46.  
[\[PubMed Abstract\]](#) -
153. Galgiani JN, Ampel NM, Blair JE, et al. 2016 Infectious Diseases Society of America (IDSA) Clinical Practice Guideline for the Treatment of Coccidioidomycosis. *Clin Infect Dis*. 2016;63:e112-46.  
[\[PubMed Abstract\]](#) -
154. Fish DG, Ampel NM, Galgiani JN, et al. Coccidioidomycosis during human immunodeficiency virus

- infection. A review of 77 patients. *Medicine (Baltimore)*. 1990;69:384-91.  
[\[PubMed Abstract\]](#) -
155. Durkin M, Connolly P, Kuberski T, et al. Diagnosis of coccidioidomycosis with use of the *Coccidioides* antigen enzyme immunoassay. *Clin Infect Dis*. 2008;47:e69-73.  
[\[PubMed Abstract\]](#) -
156. Kuberski T, Herrig J, Pappagianis D. False-positive IgM serology in coccidioidomycosis. *J Clin Microbiol*. 2010;48:2047-9.  
[\[PubMed Abstract\]](#) -
157. Durkin M, Estok L, Hospenthal D, et al. Detection of *Coccidioides* antigenemia following dissociation of immune complexes. *Clin Vaccine Immunol*. 2009;16:1453-6.  
[\[PubMed Abstract\]](#) -
158. Kassis C, Zaidi S, Kuberski T, et al. Role of *Coccidioides* Antigen Testing in the Cerebrospinal Fluid for the Diagnosis of Coccidioidal Meningitis. *Clin Infect Dis*. 2015;61:1521-6.  
[\[PubMed Abstract\]](#) -
159. Dizon D, Mitchell M, Dizon B, Libke R, Peterson MW. The utility of real-time polymerase chain reaction in detecting *Coccidioides immitis* among clinical specimens in the Central California San Joaquin Valley. *Med Mycol*. 2019;57:688-93.  
[\[PubMed Abstract\]](#) -
160. Chen XM, Keithly JS, Paya CV, LaRusso NF. Cryptosporidiosis. *N Engl J Med*. 2002; 346:1723-31.  
[\[PubMed Abstract\]](#) -
161. Goodgame RW. Understanding intestinal spore-forming protozoa: cryptosporidia, microsporidia, isospora, and cyclospora. *Ann Intern Med*. 1996;124:429-41.  
[\[PubMed Abstract\]](#) -
162. Panel on Guidelines for the Prevention and Treatment of Opportunistic Infections in Adults and Adolescents with HIV. Guidelines for the prevention and treatment of opportunistic infections in adults and adolescents with HIV. National Institutes of Health, HIV Medicine Association, and Infectious Diseases Society of America. Cryptosporidiosis. Last updated: January 18, 2023.  
[\[HIV.gov\]](#) -
163. Flanigan T, Whalen C, Turner J, Soave R, Toerner J, Havlir D, Kotler D. *Cryptosporidium* infection and CD4 counts. *Ann Intern Med*. 1992;116:840-2.  
[\[PubMed Abstract\]](#) -
164. Chen XM, LaRusso NF. Cryptosporidiosis and the pathogenesis of AIDS-cholangiopathy. *Semin Liver Dis*. 2002;22:277-89.  
[\[PubMed Abstract\]](#) -
165. Weber R, Bryan RT, Bishop HS, Wahlquist SP, Sullivan JJ, Juranek DD. Threshold of detection of *Cryptosporidium* oocysts in human stool specimens: evidence for low sensitivity of current diagnostic methods. *J Clin Microbiol*. 1991;29:1323-7.  
[\[PubMed Abstract\]](#) -
166. Binnicker MJ. Multiplex Molecular Panels for Diagnosis of Gastrointestinal Infection: Performance, Result Interpretation, and Cost-Effectiveness. *J Clin Microbiol*. 2015;53:3723-8.  
[\[PubMed Abstract\]](#) -

167. Roellig DM, Yoder JS, Madison-Antenucci S, et al. Community Laboratory Testing for Cryptosporidium: Multicenter Study Retesting Public Health Surveillance Stool Samples Positive for Cryptosporidium by Rapid Cartridge Assay with Direct Fluorescent Antibody Testing. PLoS One. 2017;12:e0169915.  
[\[PubMed Abstract\]](#) -
168. Ryan U, Papparini A, Oskam C. New Technologies for Detection of Enteric Parasites. Trends Parasitol. 2017;33:532-46.  
[\[PubMed Abstract\]](#) -
169. Garcia LS, Arrowood M, Kokoskin E, et al. Practical Guidance for Clinical Microbiology Laboratories: Laboratory Diagnosis of Parasites from the Gastrointestinal Tract Clin Microbiol Rev. 2017;31:e00025-17.  
[\[PubMed Abstract\]](#) -
170. Dionisio D, Orsi A, Sterrantino G, et al. Chronic cryptosporidiosis in patients with AIDS: stable remission and possible eradication after long-term, low dose azithromycin. J Clin Pathol. 1998;51:138-42.  
[\[PubMed Abstract\]](#) -
171. Hewitt RG, Yiannoutsos CT, Higgs ES, et al. Paromomycin: no more effective than placebo for treatment of cryptosporidiosis in patients with advanced human immunodeficiency virus infection. AIDS Clinical Trial Group. Clin Infect Dis. 2000;31:1084-92.  
[\[PubMed Abstract\]](#) -
172. Kadappu KK, Nagaraja MV, Rao PV, Shastry BA. Azithromycin as treatment for cryptosporidiosis in human immunodeficiency virus disease. J Postgrad Med. 2002;48:179-81.  
[\[PubMed Abstract\]](#) -
173. Rossignol JF, Hidalgo H, Feregrino M et al. A double-‘blind’ placebo-controlled study of nitazoxanide in the treatment of cryptosporidial diarrhea in AIDS patients in Mexico. Trans R Soc Trop Med Hyg. 1998;92:663-6.  
[\[PubMed Abstract\]](#) -
174. Rossignol JF. Nitazoxanide in the treatment of acquired immune deficiency syndrome-related cryptosporidiosis: results of the United States compassionate use program in 365 patients. Aliment Pharmacol Ther. 2006;24:887-94.  
[\[PubMed Abstract\]](#) -
175. Abubakar I, Aliyu SH, Arumugam C, Usman NK, Hunter PR. Treatment of cryptosporidiosis in immunocompromised individuals: systematic review and meta-analysis. Br J Clin Pharmacol. 2007;63:387-93.  
[\[PubMed Abstract\]](#) -
176. Barta JR, Schrenzel MD, Carreno R, Rideout BA. The genus *Atoxoplasma* (Garnham 1950) as a junior objective synonym of the genus *Isospora* (Schneider 1881) species infecting birds and resurrection of *Cystoisospora* (Frenkel 1977) as the correct genus for *Isospora* species infecting mammals. J Parasitol. 2005;91:726-7.  
[\[PubMed Abstract\]](#) -
177. Lindsay DS, Dubey JP, Blagburn BL. Biology of *Isospora* spp. from humans, nonhuman primates, and domestic animals. Clin Microbiol Rev. 1997;10:19-34.  
[\[PubMed Abstract\]](#) -
178. Pape JW, Johnson WD Jr. *Isospora belli* infections. Prog Clin Parasitol. 1991;2:119-27.

[\[PubMed Abstract\]](#) -

179. Sorvillo FJ, Lieb LE, Seidel J, Kerndt P, Turner J, Ash LR. Epidemiology of isosporiasis among persons with acquired immunodeficiency syndrome in Los Angeles County. *Am J Trop Med Hyg.* 1995;53:656-9.

[\[PubMed Abstract\]](#) -

180. DeHovitz JA, Pape JW, Boncy M, Johnson WD Jr. Clinical manifestations and therapy of *Isospora belli* infection in patients with the acquired immunodeficiency syndrome. *N Engl J Med.* 1986;315:87-90.

[\[PubMed Abstract\]](#) -

181. Verdier RI, Fitzgerald DW, Johnson WD Jr, Pape JW. Trimethoprim-sulfamethoxazole compared with ciprofloxacin for treatment and prophylaxis of *Isospora belli* and *Cyclospora cayetanensis* infection in HIV-infected patients. A randomized, controlled trial. *Ann Intern Med.* 2000;132:885-8.

[\[PubMed Abstract\]](#) -

182. Legua P, Seas C. Cystoisospora and cyclospora. *Curr Opin Infect Dis.* 2013;26:479-83.

[\[PubMed Abstract\]](#) -

183. Ng E, Markell EK, Fleming RL, Fried M. Demonstration of *Isospora belli* by acid-fast stain in a patient with acquired immune deficiency syndrome. *J Clin Microbiol.* 1984;20:384-6.

[\[PubMed Abstract\]](#) -

184. Panel on Guidelines for the Prevention and Treatment of Opportunistic Infections in Adults and Adolescents with HIV. Guidelines for the prevention and treatment of opportunistic infections in adults and adolescents with HIV. National Institutes of Health, HIV Medicine Association, and Infectious Diseases Society of America. Cystoisosporiasis (formerly Isosporiasis). Last updated: April 23, 2025.

[\[HIV.gov\]](#) -

185. Taniuchi M, Verweij JJ, Sethabutr O, et al. Multiplex polymerase chain reaction method to detect *Cyclospora*, *Cystoisospora*, and *Microsporidia* in stool samples. *Diagn Microbiol Infect Dis.* 2011;71:386-90.

[\[PubMed Abstract\]](#) -

186. Pape JW, Verdier RI, Johnson WD Jr. Treatment and prophylaxis of *Isospora belli* infection in patients with the acquired immunodeficiency syndrome. *N Engl J Med.* 1989;320:1044-7.

[\[PubMed Abstract\]](#) -

187. Weiss LM, Perlman DC, Sherman J, Tanowitz H, Wittner M. *Isospora belli* infection: treatment with pyrimethamine. *Ann Intern Med.* 1988;109:474-5.

[\[PubMed Abstract\]](#) -

## References

- Atkinson A, Miro JM, Mocroft A, et al. No need for secondary *Pneumocystis jirovecii* pneumonia prophylaxis in adult people living with HIV from Europe on ART with suppressed viraemia and a CD4 cell count greater than 100 cells/ $\mu$ L. *J Int AIDS Soc.* 2021;24:e25726.  
[\[PubMed Abstract\]](#) -
- Benson CA, Williams PL, Currier JS, et al. A prospective, randomized trial examining the efficacy and safety of clarithromycin in combination with ethambutol, rifabutin, or both for the treatment of disseminated *Mycobacterium avium* complex disease in persons with acquired immunodeficiency syndrome. *Clin Infect Dis.* 2003;37:1234-43.

[\[PubMed Abstract\]](#) -

- Blanshard C, Benhamou Y, Dohin E, Lernestedt JO, Gazzard BG, Katlama C. Treatment of AIDS-associated gastrointestinal cytomegalovirus infection with foscarnet and ganciclovir: a randomized comparison. *J Infect Dis.* 1995;172:622-8.  
[\[PubMed Abstract\]](#) -
- Carr A, Marriott D, Field A, Vasak E, Cooper DA. Treatment of HIV-1-associated microsporidiosis and cryptosporidiosis with combination antiretroviral therapy. *Lancet.* 1998;351:256-61.  
[\[PubMed Abstract\]](#) -
- Day JN, Chau TT, Wolbers M, et al. Combination antifungal therapy for cryptococcal meningitis. *N Engl J Med.* 2013;368:1291-302.  
[\[PubMed Abstract\]](#) -
- Katlama C, Mouthon B, Gourdon D, Lapierre D, Rousseau F. Atovaquone as long-term suppressive therapy for toxoplasmic encephalitis in patients with AIDS and multiple drug intolerance. Atovaquone Expanded Access Group. *AIDS.* 1996;10:1107-12.  
[\[PubMed Abstract\]](#) -
- Kovacs JA. Efficacy of atovaquone in treatment of toxoplasmosis in patients with AIDS. The NIAID-Clinical Center Intramural AIDS Program. *Lancet.* 1992;340:637-8.  
[\[PubMed Abstract\]](#) -
- Martin DF, Sierra-Madero J, Walmsley S, et al. A controlled trial of valganciclovir as induction therapy for cytomegalovirus retinitis. *N Engl J Med.* 2002;346:1119-26.  
[\[PubMed Abstract\]](#) -
- Miao YM, Awad-El-Kariem FM, Franzen C, et al. Eradication of cryptosporidia and microsporidia following successful antiretroviral therapy. *J Acquir Immune Defic Syndr.* 2000;25:124-9.  
[\[PubMed Abstract\]](#) -
- Molina JM, Tourneur M, Sarfati C, et al. Fumagillin treatment of intestinal microsporidiosis. *N Engl J Med.* 2002;346:1963-9.  
[\[PubMed Abstract\]](#) -
- Opportunistic Infections Project Team of the Collaboration of Observational HIV Epidemiological Research in Europe (COHERE), Mocroft A, Reiss P, et al. Is it safe to discontinue primary *Pneumocystis jiroveci* pneumonia prophylaxis in patients with virologically suppressed HIV infection and a CD4 cell count Pappas PG, Kauffman CA, Andes DR, et al. Clinical Practice Guideline for the Management of Candidiasis: 2016 Update by the Infectious Diseases Society of America. *Clin Infect Dis.* 2016;62:e1-50. Prosty C, Hanula R, Levin Y, Bogoch II, McDonald EG, Lee TC. Revisiting the Evidence Base for Modern-Day Practice of the Treatment of Toxoplasmic Encephalitis: A Systematic Review and Meta-Analysis. *Clin Infect Dis.* 2023;76:e1302-e1319. Rhein J, Bahr NC, Hemmert AC, et al. Diagnostic performance of a multiplex PCR assay for meningitis in an HIV-infected population in Uganda. *Diagn Microbiol Infect Dis.* 2016;84:268-73. Skiest DJ, Vazquez JA, Anstead GM, et al. Posaconazole for the treatment of azole-refractory oropharyngeal and esophageal candidiasis in subjects with HIV infection. *Clin Infect Dis.* 2007;44:607-14. Smith NH, Cron S, Valdez LM, Chappell CL, White AC Jr. Combination drug therapy for cryptosporidiosis in AIDS. *J Infect Dis.* 1998;178:900-3. Wheat J, Hafner R, Korzun AH, et al. Itraconazole treatment of disseminated histoplasmosis in patients with the acquired immunodeficiency syndrome. AIDS Clinical Trial Group. *Am J Med.* 1995;98:336-42. Yangco BG, Buchacz K, Baker R, Palella FJ, Armon C, Brooks JT. Is primary

## Figures

**Figure 1 (Image Series) - *Pneumocystis* Pneumonia and Chest Imaging (Image Series) - Figure 1 (Image Series) - *Pneumocystis* Pneumonia and Chest Imaging**  
**Image 1A: *Pneumocystis* Pneumonia: Chest Radiograph**

This chest radiograph scan shows extensive bilateral infiltrates in an adult with HIV and *Pneumocystis* pneumonia.

Source: Brian R. Wood, MD



**Figure 1 (Image Series) - *Pneumocystis* Pneumonia and Chest Imaging**  
**Image 1B: *Pneumocystis* Pneumonia: Pneumothorax**

This chest radiograph scan shows a right lung pneumothorax (white arrows) in an adult with HIV and *Pneumocystis* pneumonia.

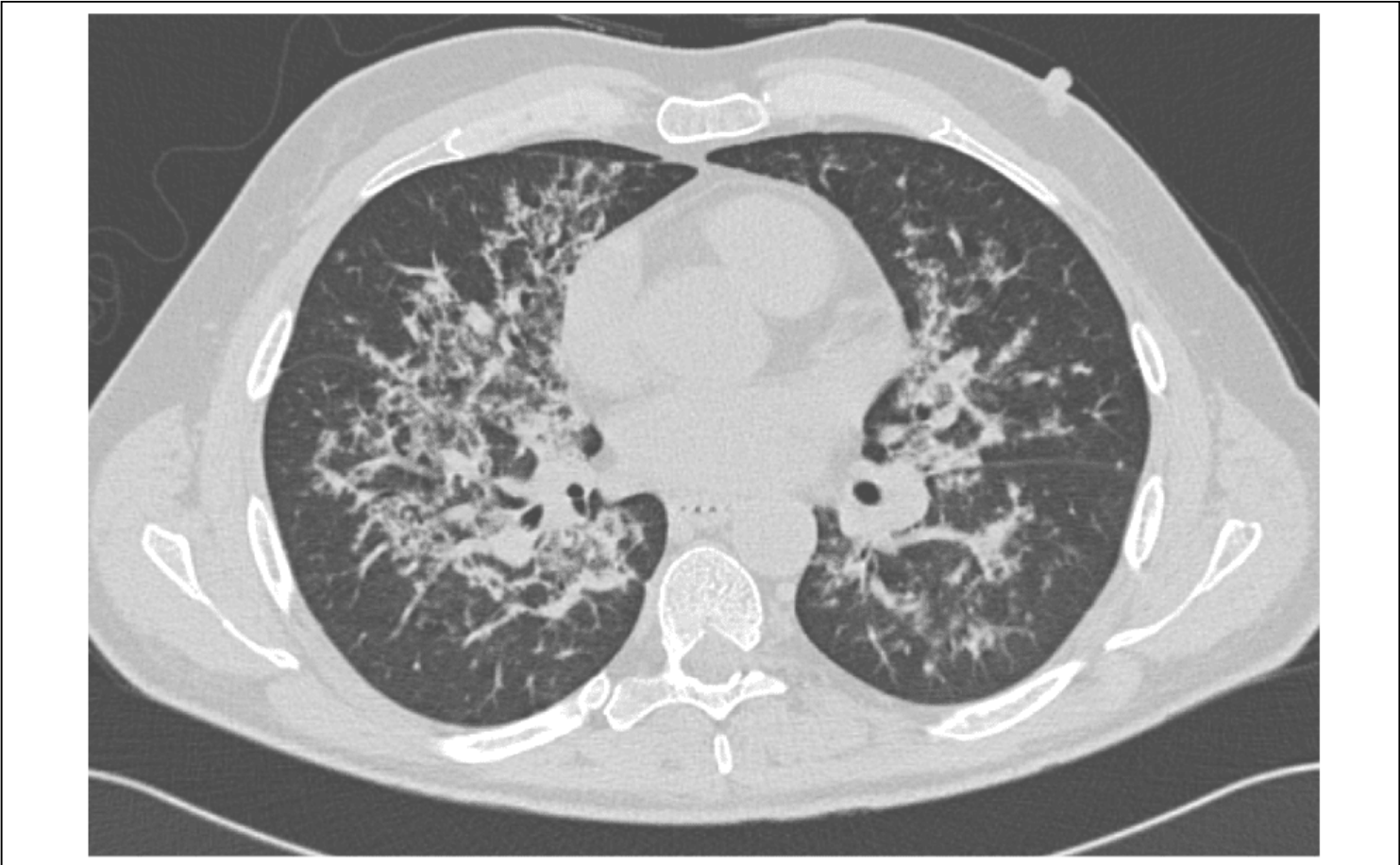Source: Brian R. Wood, MD



**Figure 1 (Image Series) - *Pneumocystis* Pneumonia and Chest Imaging**  
**Image 1C: *Pneumocystis* Pneumonia: Chest Computed Tomographic (CT) Scan**

This chest CT scan shows extensive bilateral infiltrates in an adult with HIV and *Pneumocystis* pneumonia.

Source: Brian R. Wood, MD



**Figure 2 (Image Series) - *Toxoplasma* Encephalitis: Symptoms and Signs (Image Series) - Figure 2 (Image Series) - *Toxoplasma* Encephalitis: Symptoms and Signs**  
**Image 2A: Symptoms of Patients with Acute *Toxoplasma* Encephalitis**

This graphic shows the frequency of symptoms present in 115 persons with HIV and *Toxoplasma* encephalitis seen at San Francisco General Hospital during the years 1981-1990.

Source: Porter SB, Sande MA. Toxoplasmosis of the central nervous system in the acquired immunodeficiency syndrome. N Engl J Med. 1992;327:1643-8.



**Figure 2 (Image Series) - *Toxoplasma* Encephalitis: Symptoms and Signs**  
**Image 2B: Clinical Signs in Patients with Acute *Toxoplasma* Encephalitis**

Frequency of signs present in 115 persons with HIV and *Toxoplasma* encephalitis; focal signs consisted of hemiparesis (39%), ataxia (30%), cranial-nerve palsies (28%), sensory deficits (12%), aphasia (8%), and hemianopia (7%).

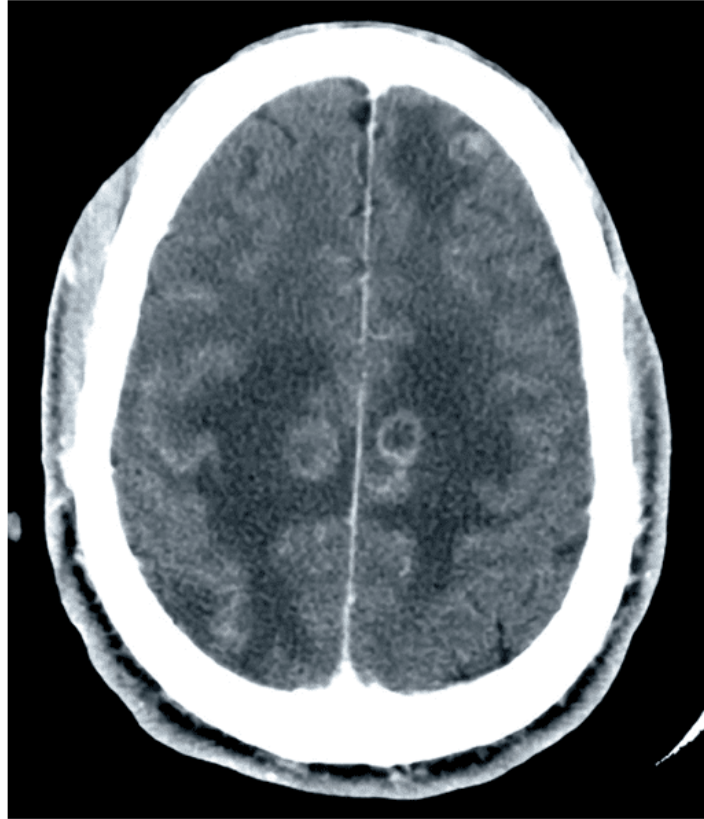
Source: Porter SB, Sande MA. Toxoplasmosis of the central nervous system in the acquired immunodeficiency syndrome. N Engl J Med. 1992;327:1643-8.



**Figure 3 (Image Series) - *Toxoplasma* Encephalitis and Brain Imaging (Image Series) - Figure 3 (Image Series) - *Toxoplasma* Encephalitis and Brain Imaging**  
**Image 3A: Contrast Brain Computed Tomographic (CT) Scan in Person with HIV and *Toxoplasma* Encephalitis**

This contrast CT scan shows multiple ring-enhancing lesions with surrounding vasogenic edema.

Source: David H. Spach, MD



**Figure 3 (Image Series) - *Toxoplasma* Encephalitis and Brain Imaging**  
**Image 3B: Brain Magnetic Resonance Imaging (MRI) Scan in Person with HIV and *Toxoplasma* Encephalitis**

The MRI scan shows multiple lesions.

Source: David H. Spach, MD



### Figure 4 Timing of Neurologic Response in Patients with *Toxoplasma* Encephalitis

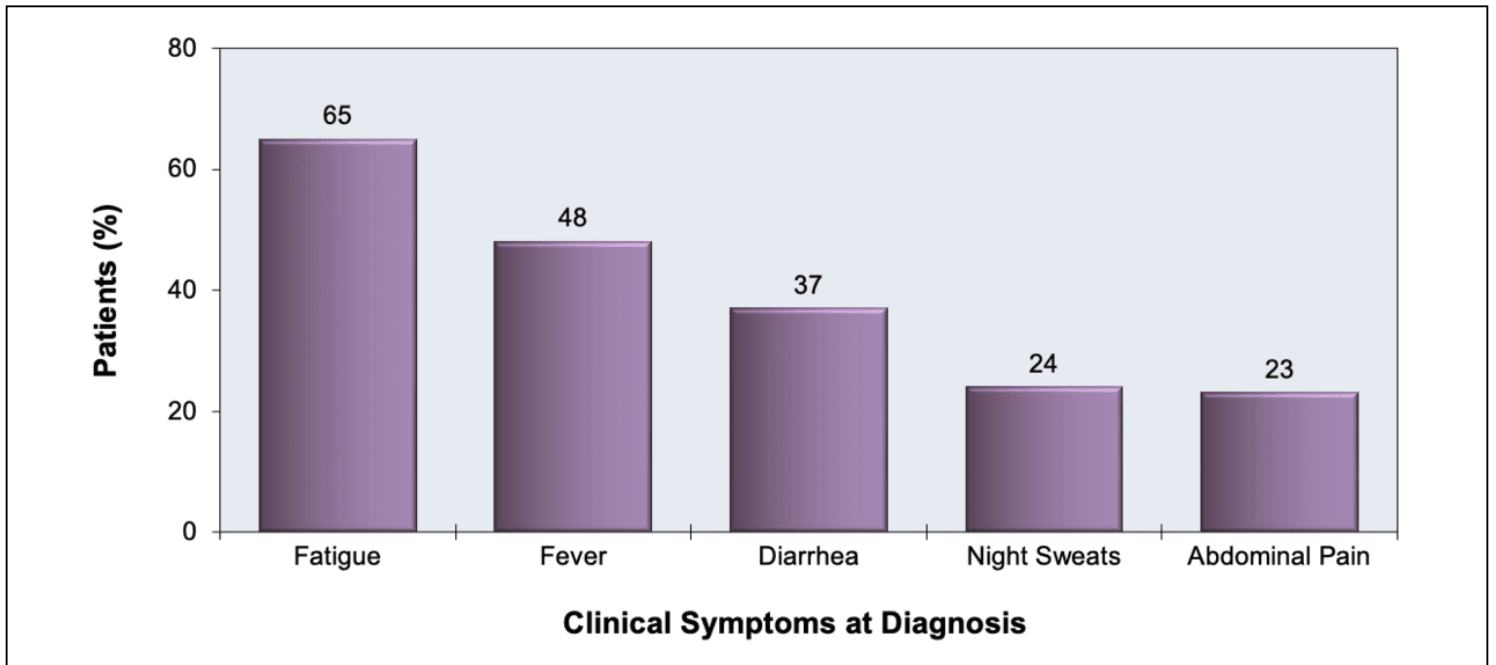
The timing of neurologic response in 35 adults with HIV and *Toxoplasma* encephalitis who improved with treatment is shown. A neurologic response was defined as improvement in at least half of the baseline neurologic abnormalities.

Reproduced from Luft BJ, Hafner R, Korzun AH, et al. Toxoplasmic encephalitis in patients with the acquired immunodeficiency syndrome. Members of the ACTG 077p/ANRS 009 Study Team. N Engl J Med. 1993;329:995-1000. Reproduced with permission from the Massachusetts Medical Society. Copyright © 1993 Massachusetts Medical Society. All rights reserved.



### Figure 5 Common Clinical Manifestations of Persons with HIV and MAC Bacteremia

Source: Gordin FM, Cohn DL, Sullam PM, Schoenfelder JR, Wynne BA, Horsburgh CR Jr. Early manifestations of disseminated *Mycobacterium avium* complex disease: a prospective evaluation. J Infect Dis. 1997;176:126-32.



**Figure 6 Clinical Manifestations of Persons with HIV and Cryptococcal Meningitis at the Time of Diagnosis**

Clinical manifestations of 65 adults with HIV from France at the time of diagnosis of cryptococcal meningitis. The mean CD4 count at the time of diagnosis was 46 cells/mm<sup>3</sup>.

Source: Darras-Joly C, Chevret S, Wolff M, et al. Cryptococcus neoformans infection in France: epidemiologic features of and early prognostic parameters for 76 patients who were infected with human immunodeficiency virus. Clin Infect Dis. 1996;23:369-76.



**Figure 7 Patient Outcomes Related to Change in Cerebrospinal Fluid (CSF) Opening Pressure in Persons with HIV and Cryptococcal Meningitis**

The graph represents outcomes of 161 individuals with HIV and cryptococcal meningitis who had lumbar puncture with opening pressure measured prior to therapy and 2 weeks after treatment. Clinical failure was defined as persistent or worsening signs and symptoms of cryptococcal meningitis after 2 weeks of therapy; mycologic failure was defined as positive CSF culture after 2 weeks of therapy.

Source: Graybill JR, Sobel J, Saag M, et al. Diagnosis and management of increased intracranial pressure in patients with AIDS and cryptococcal meningitis. The NIAID Mycoses Study Group and AIDS Cooperative Treatment Groups. Clin Infect Dis. 2000;30:47-54.



**Figure 8 (Image Series) - Retinitis Findings on Fundoscopic Examination (Image Series) - Figure 8 (Image Series) - Retinitis Findings on Fundoscopic Examination**

**Image 8A: Normal Retina**

This image of a normal retina identifies important landmarks visible with a hand-held ophthalmoscope. The macula is in the center of the retina; it contains densely packed cones that specialize in visual acuity and color vision. The fovea is the central depression within the macula. The visible portion of the optic nerve is the optic nerve head or optic disc. Retinal veins and arteries are prominently seen extending from the optic nerve.

Source: Elaine L. Chuang, M.D



**Figure 8 (Image Series) - Retinitis Findings on Fundoscopic Examination**  
**Image 8B: Cytomegalovirus Retinitis, Central Portion of Retina**

This retinal photograph taken from a person with HIV and cytomegalovirus retinitis shows an opacified, edematous retina (yellow) and hemorrhage (red); the retinitis involves the optic nerve head and extends adjacent to the macula along the retinal blood vessels. This lesion is considered an immediate sight-threatening lesion.

Source: Elaine L. Chuang, M.D

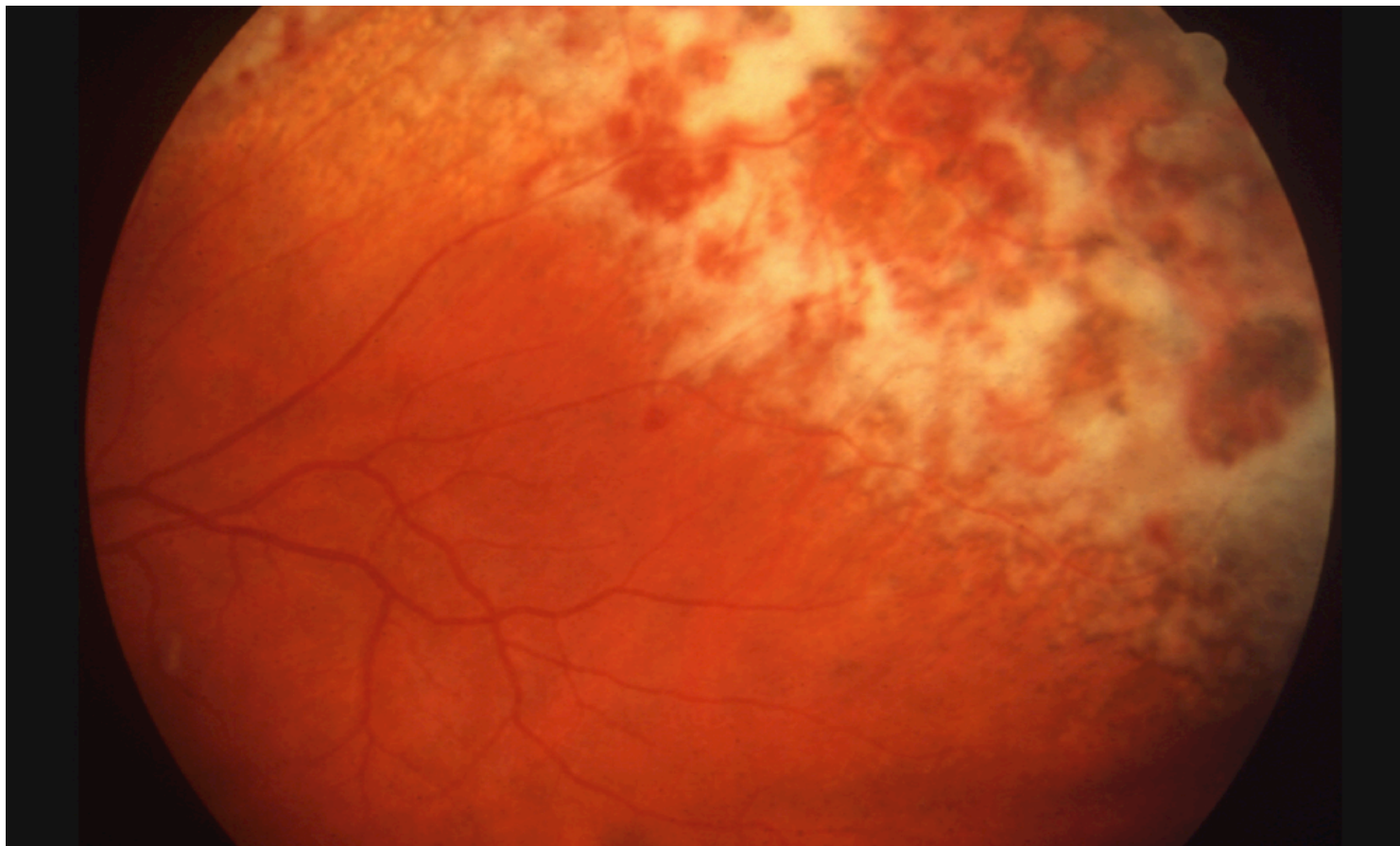


## **Figure 8 (Image Series) - Retinitis Findings on Fundoscopic Examination**

### **Image 8C: Cytomegalovirus Retinitis, Brushfire Pattern**

This retinal photograph taken of a person with HIV and cytomegalovirus retinitis shows extensive retinitis in a brushfire pattern in the upper and right region of the image. In the area farthest to the upper right, retinal necrosis and atrophy have led to retinal pigment epithelial change, as evident by the darkly pigmented appearance.

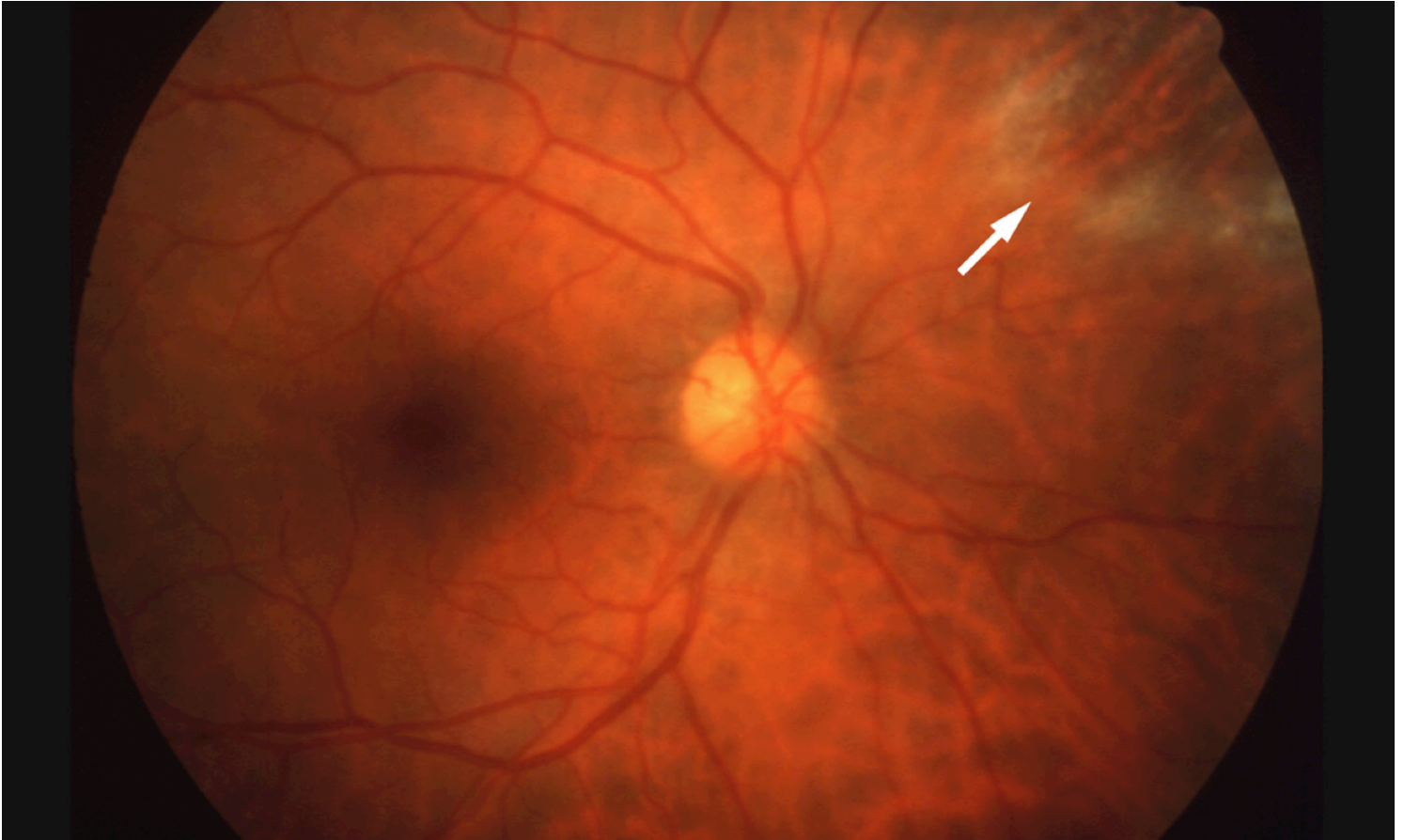Source: Elaine L. Chuang, M.D



**Figure 8 (Image Series) - Retinitis Findings on Fundoscopic Examination**  
**Image 8D: Cytomegalovirus Retinitis, Smoldering Lesion**

This retinal photograph is taken from a person with HIV in whom cytomegalovirus retinitis (arrow) developed in a slower fashion ("smoldering CMV retinitis"). This "smoldering" type of lesion often does not cause noticeable symptoms and may escape detection until it extends closer to the site-threatening region (zone 1).

Source: Elaine L. Chuang, M.D



**Figure 8 (Image Series) - Retinitis Findings on Fundoscopic Examination**

**Image 8E: HIV Retinopathy**

This retinal photograph taken of a person with HIV retinopathy shows multiple cotton wool spots. These cotton wool spots represent nerve fiber layer infarcts, identical to those often seen in persons with hypertension or diabetes mellitus. These lesions do not cause symptoms and resolve spontaneously.

Source: Elaine L. Chuang, M.D



**Figure 9 Retinal Anatomic Zones**

This illustration shows a schematic representation of an entire retina with superimposed anatomic zones (as defined by the UCLA CMV Retinopathy Study Group). Using a standard direct ophthalmologic examination, only a small portion of the retina is visualized (all of zone 1 and some of zone 2). Zone 1 comprises less than 10% of the entire retina.

Source: The retinal anatomic zones are based on the classification in Holland GN, Buhles WC Jr, Mastre B, Kaplan HJ. A controlled retrospective study of ganciclovir treatment for cytomegalovirus retinopathy. Use of a standardized system for the assessment of disease outcome. UCLA CMV Retinopathy. Study Group. Arch Ophthalmol. 1989;107:1759-66.

Illustration credit: Cognition Studio, Inc.



**Figure 10 Magnetic Resonance Imaging (MRI) in Person with HIV and Progressive Multifocal Leukoencephalopathy**

This T2-weighted MRI scan shows diffuse confluent lesions most prominent in the occipital lobes.

Source: David H. Spach, MD



**Figure 11 Chest Computed Tomographic (CT) Scan in an Adult with HIV and Disseminated Histoplasmosis**

This chest CT scan shows patchy bilateral infiltrates and extensive cavitary lesions in an adult with HIV and disseminated histoplasmosis.

Source: Devika Singh, MD, MPH



**Figure 12 Estimated Sensitivity of Diagnostic Tests for Disseminated Histoplasmosis in Persons with HIV**

These data reflect the sensitivity of four different tests used to diagnose disseminated histoplasmosis in persons with HIV. These data include samples from blood, bone marrow, respiratory secretions, or localized skin lesions.

Source: Wheat J. Endemic mycoses in AIDS: a clinical review. Clin Microbiol Rev. 1995;8:146-59.



**Figure 13 Disseminated Histoplasmosis and Peripheral Blood Smear**

This peripheral blood smear from a person with HIV shows a cluster of intracellular *Histoplasma capsulatum* organisms (white arrow). Blood cultures subsequently grew *Histoplasma capsulatum*.

Source: Harborview Medical Center Microbiology Laboratory



**Figure 14 *Cryptosporidium***

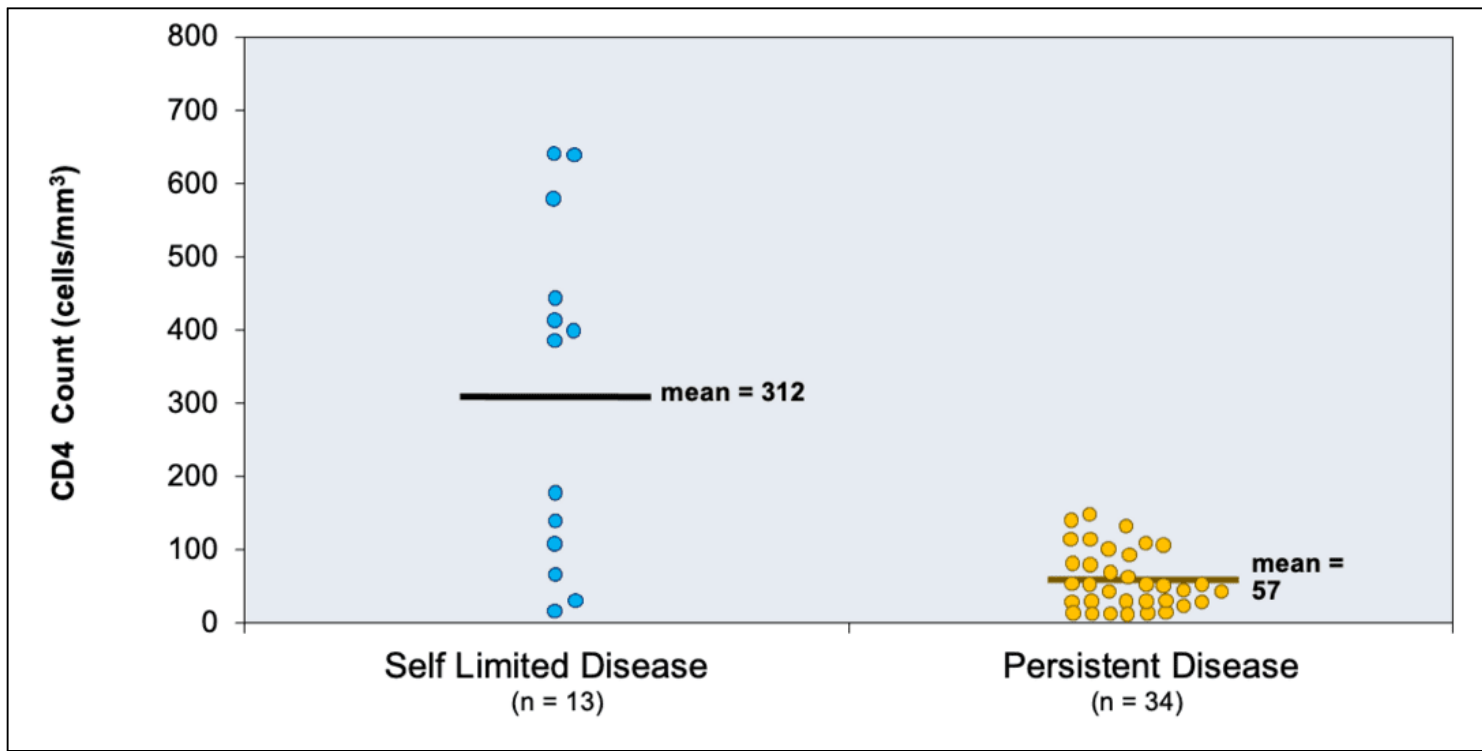
This illustration is showing *Cryptosporidium* oocysts with sporozoites.

Source: Centers for Disease Control and Prevention



**Figure 15 Relationship of CD4 Cell Count and Cryptosporidiosis Disease in Persons with HIV**

Source: Reproduced with permission from: Flanigan T, Whalen C, Turner J, Soave R, Toerner J, Havlir D, Kotler D. Cryptosporidium infection and CD4 counts. Ann Intern Med. 1992;116:840-2. The American College of Physicians is not responsible for the accuracy of the translation.



**Figure 16 (Image Series) - Techniques for the Diagnosis of Cryptosporidiosis (Image Series) -  
Figure 16 (Image Series) - Techniques for the Diagnosis of Cryptosporidiosis  
Image 16A: Modified Acid-fast Staining of Stool Samples Showing *Cryptosporidium* Oocysts**

The black arrows point to multiple *Cryptosporidium* oocysts.

Image courtesy of Carolyn Wallis, Harborview Medical Center Microbiology Laboratory.



**Figure 16 (Image Series) - Techniques for the Diagnosis of Cryptosporidiosis**  
**Image 16B: Immunofluorescence Microscopy for Detection of Oocysts**

Oocysts of *Cryptosporidium parvum* (smaller ovals on left and top) and *Giardia intestinalis* (larger ovals and lower right) stained with immunofluorescent antibodies.

Source: Centers for Disease Control and Prevention



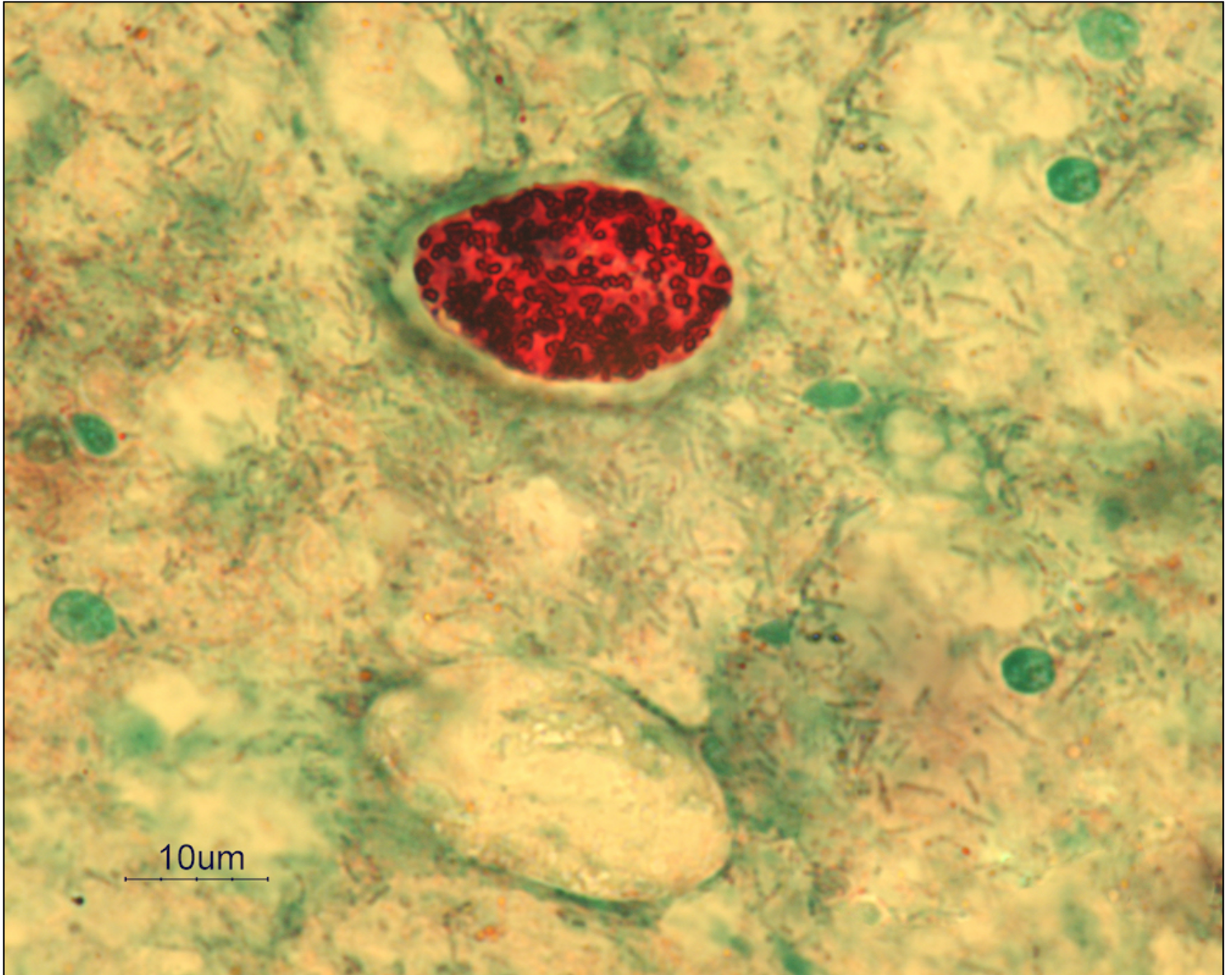
**Figure 17 Correlation of Clinical Manifestations with Different *Microsporidia* Species**

Clinical Syndromes with Microsporidiosis by Organism	
Microsporidia Organism	Clinical Manifestation
<i>E. bieneusi</i>	Malabsorption, diarrhea, and cholangitis
<i>E. cuniculi</i>	Hepatitis, encephalitis, and disseminated disease
<i>E. intestinalis</i>	Diarrhea, disseminated infection, and superficial keratoconjunctivitis
<i>E. hellem</i>	Superficial keratoconjunctivitis, sinusitis, respiratory disease, prostatic abscesses, and disseminated infection
<i>Anncaliia</i> and <i>Trachipleistophora</i>	Keratoconjunctivitis
<i>Nosema</i> , <i>Vittaforma</i> , and <i>Microsporidium</i>	Stromal keratitis following trauma in immunocompetent hosts
<i>Pleistophora</i> , <i>Anncaliia</i> , and <i>Trachipleistophora</i>	Myositis
<i>Trachipleistophora</i>	Encephalitis and disseminated disease

**Figure 18 (Image Series) - *Cystoisospora belli* Diagnostic Stains (Image Series) - Figure 18 (Image Series) - *Cystoisospora belli* Diagnostic Stains**  
**Image 18A: *Cystoisospora belli* Oocyst with Granular Mass**

Modified acid-fast smear of stool sample showing *Cystoisospora belli* oocyst with internal granular mass (zygote).

Image courtesy of Carolyn Wallis, Harborview Medical Center Microbiology Laboratory.



**Figure 18 (Image Series) - *Cystoisospora belli* Diagnostic Stains**  
**Image 18B: *Cystoisospora belli* Oocyst with Internal Sporoblast**

Image courtesy of Carolyn Wallis, Harborview Medical Center Microbiology Laboratory.



**Figure 18 (Image Series) - *Cystoisospora belli* Diagnostic Stains**  
**Image 18C: Wet Mount Staining Techniques for *Cystoisospora belli***

These stool sample wet mount tests show three wet mount techniques for diagnosing *Cystoisospora belli*: bright-field microscopy (A and D); differential interference contrast (DIC) (B and E); and blue UV fluorescence microscopy (C and F). The images on the top row (A, B, and C) show *C. belli* with a single internal sporoblast, and the images on the bottom row (D, E, and F) show two internal sporoblasts.

Source: Centers for Disease Control and Prevention.

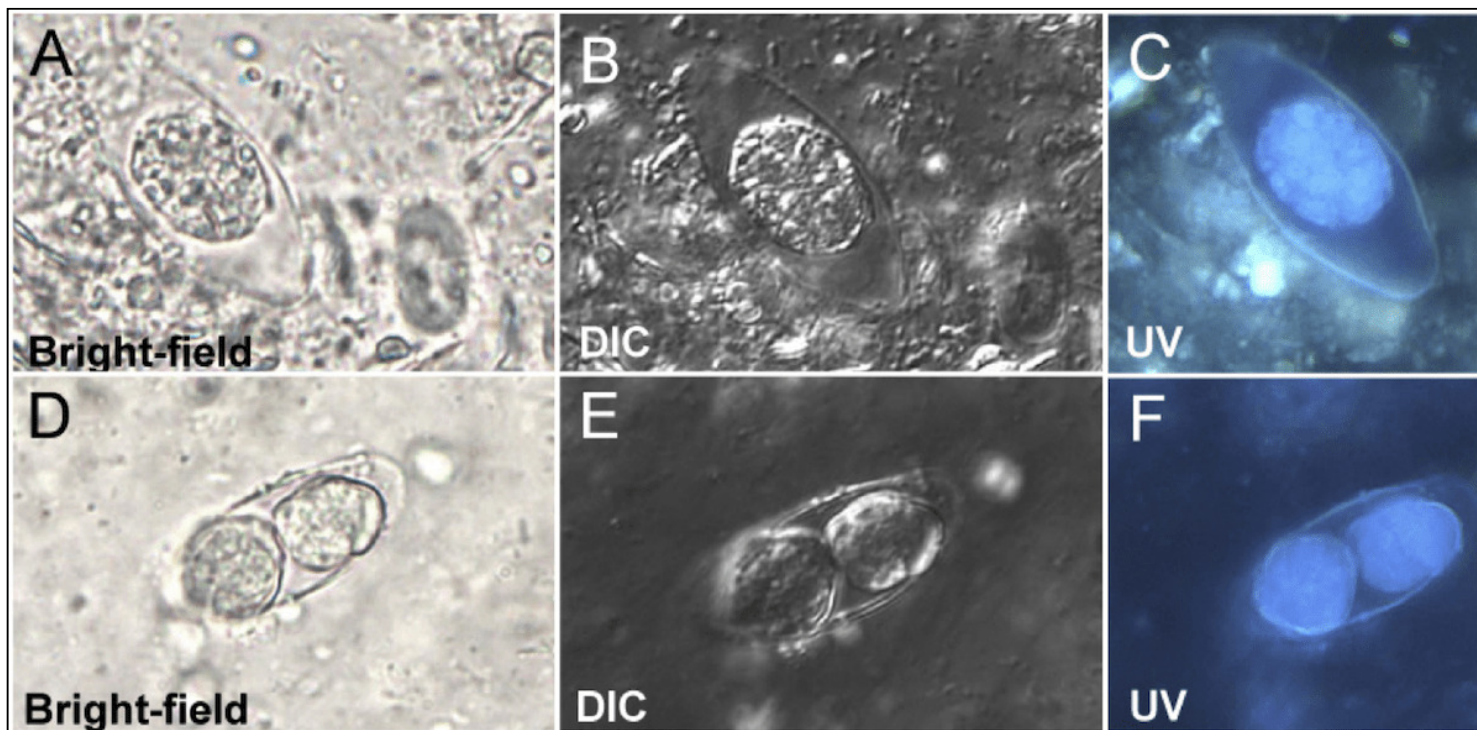


Table 1. HIV Clinical Guidelines: Recommendations for Treating Mild-to-Moderate *Pneumocystis* Pneumonia  
 Guidelines for the Prevention and Treatment of Opportunistic Infections in Adults and Adolescents with HIV  
 For Mild-to-Moderate PCP People with HIV who develop PCP despite trimethoprim-sulfamethoxazole prophylaxis usually effectively with standard doses of trimethoprim-sulfamethoxazole (BIII)

If not already started, antiretroviral therapy should be initiated in patients within 2 weeks of diagnosis if possible **(AI)**.

**Preferred Therapy**

- Trimethoprim-sulfamethoxazole (trimethoprim 15–20 mg and sulfamethoxazole 75–100 mg) PO given in three divided doses (AI), *or*
- Trimethoprim-sulfamethoxazole two DS tablets PO three times daily (AI)

**Alternative Therapy**

- Dapsone<sup>a</sup> 100 mg PO daily *plus* trimethoprim 15 mg/kg/day PO given in three divided doses (BI), *or*
- Primaquine<sup>a</sup> 30 mg (base) PO daily *plus* clindamycin PO (450 mg every 6 hours or 600 mg every 12 hours) (BI), *or*
- Atovaquone 750 mg PO twice daily with food (BI)

**Duration of Therapy**

- The recommended duration of therapy (irrespective of regimen) is 21 days **(AII)**.
- Secondary prophylaxis should be initiated immediately after completion of treatment **(AII)**.

**Other Considerations/Comments**

- For people with HIV with non-life-threatening adverse reactions to trimethoprim-sulfamethoxazole, therapy should be continued if clinically feasible.
- If trimethoprim-sulfamethoxazole is discontinued because of a mild adverse reaction, alternative therapy should be considered after the reaction has resolved **(AII)**. The dose of trimethoprim-sulfamethoxazole can be increased gradually (desensitization) **(BI)** or the drug can be discontinued at a reduced dose or frequency **(CIII)**.
- Trimethoprim-sulfamethoxazole should be permanently discontinued, with no rechallenge, in people with HIV with life-threatening adverse reactions including suspected or confirmed Stevens-Johnson Syndrome or toxic epidermal necrolysis **(AIII)**. See above for alternative options for treatment **(AIII)**.

<sup>a</sup>Glucose-6-phosphate dehydrogenase (G6PD) (G6PD) levels should be checked before administration of dapsone or primaquine. An alternative agent should be used if the patient is found to have G6PD deficiency.

Abbreviations: PCP = *Pneumocystis* pneumonia; PO = orally; DS = double strength

Rating System for Prevention and Treatment Recommendations

- Strength of Recommendation: A = Strong; B = Moderate; C = Weak
- Quality of Evidence for the Recommendation: I = One or more randomized trials with clinical outcomes and/or validated laboratory endpoints; II = One or more well-designed, non-randomized trials or observational cohort studies with long-term clinical outcomes; III = Expert opinion

Source:

- Panel on Guidelines for the Prevention and Treatment of Opportunistic Infections in Adults and

Adolescents with HIV. Guidelines for the prevention and treatment of opportunistic infections in adults and adolescents with HIV. National Institutes of Health, HIV Medicine Association, and Infectious Diseases Society of America. *Pneumocystis* Pneumonia. Updated: September 9, 2025. [[HIV.gov](https://www.hiv.gov)]

Table 2. Recommendations for Treating Moderate-to-Severe *Pneumocystis* Pneumonia

Guidelines for the Prevention and Treatment of Opportunistic Infections in Adults and Adolescents with HIV

For Moderate-to-Severe PCP People with HIV who develop *Pneumocystis* pneumonia (PCP) despite trimethoprim-sulfamethoxazole prophylaxis usually can be treated effectively with standard treatment doses of trimethoprim-sulfamethoxazole (BIII)

If not already started, antiretroviral therapy should be initiated in patients within 2 weeks if possible **(AI)**.

**Preferred Therapy**

- Trimethoprim-sulfamethoxazole (trimethoprim 15–20 mg/kg/day *and* sulfamethoxazole 7.5–10 mg/kg/day) IV given in divided doses every 6 or 8 hours (AI); may switch to PO for clinical improvement (AI)

**Alternative Therapy**

- Primaquine<sup>a</sup> 30 mg (base) PO once daily *plus* Clindamycin (600 mg IV every 6 hours or 300 mg PO every 8 hours or 450 mg PO every 6 hours *or* 600 mg PO every 8 hours) (AI), *or*
- Pentamidine 4 mg/kg IV once daily infused over ≥60 minutes (AI); may reduce to pentamidine 3 mg/kg IV once daily in the event of toxicities (BI)

Note: Some clinicians prefer primaquine *plus* clindamycin because it is more effective than pentamidine.

**Adjunctive Corticosteroids for Moderate-to-Severe PCP Based on the Following**

- PaO<sub>2</sub> <70 mm Hg at room air, *or*
- Alveolar-arterial (A-a) gradient ≥35 mmHg

**Corticosteroid Dosing Schedule**

- Prednisone doses (beginning as early as possible and within 72 hours of initiating PCP treatment)
  - Days 1–5: 40 mg PO twice daily
  - Days 6–10: 40 mg PO daily
  - Days 11–21: 20 mg PO daily
- IV methylprednisolone can be given as 80% of prednisone dose.
- Benefit of corticosteroid if started after 72 hours of PCP treatment is unknown, but use it for moderate-to-severe PCP **(BIII)**.

**Additional Considerations/Comments**

- For people with HIV with non-life-threatening adverse reactions to trimethoprim-sulfamethoxazole, the drug should be continued if clinically feasible.
- If trimethoprim-sulfamethoxazole is discontinued because of a mild adverse reaction, alternative therapy should be considered after the reaction has resolved **(AII)**. The dose of trimethoprim-sulfamethoxazole can be increased gradually (desensitization) **(BI)** or the drug can be restarted at a reduced dose or frequency **(CIII)**.
- Trimethoprim-sulfamethoxazole should be permanently discontinued, with no rechallenge, in people with HIV with life-threatening adverse reactions including suspected or confirmed Stevens-Johnson Syndrome or toxic epidermal necrolysis **(AIII)**. See above for alternative options.

<sup>a</sup>Glucose-6-phosphate dehydrogenase (G6PD) levels should be checked before administration of dapson or primaquine. An alternative agent should be used if the patient is found to have G6PD deficiency.

Abbreviations: PCP = *Pneumocystis* pneumonia; IV = intravenous; PaO<sub>2</sub> = room air arterial oxygen partial

pressure; PO = orally; DS = double; strength; SS = single strength

### Rating System for Prevention and Treatment Recommendations

- Strength of Recommendation: A = Strong; B = Moderate; C = Weak
- Quality of Evidence for the Recommendation: I = One or more randomized trials with clinical outcomes and/or validated laboratory endpoints; II = One or more well-designed, non-randomized trials or observational cohort studies with long-term clinical outcomes; III = Expert opinion

Source:

- Panel on Guidelines for the Prevention and Treatment of Opportunistic Infections in Adults and Adolescents with HIV. Guidelines for the prevention and treatment of opportunistic infections in adults and adolescents with HIV. National Institutes of Health, HIV Medicine Association, and Infectious Diseases Society of America. *Pneumocystis* Pneumonia. Updated: September 9, 2025. [[HIV.gov](https://www.hiv.gov)]

Table 3. Preventing Recurrences of *Pneumocystis* Pneumonia (Secondary Prophylaxis)  
Guidelines for the Prevention and Treatment of Opportunistic Infections in Adults and Adolescents with HIV

## Recommendations for Preventing Recurrence of *Pneumocystis* Pneumonia (Secondary Prophylaxis)

### Indications for Initiating Secondary Prophylaxis

- Prior *Pneumocystis* Pneumonia

#### Preferred Therapy

- Trimethoprim-sulfamethoxazole 1 DS tablet PO daily (AI), *or*
- Trimethoprim-sulfamethoxazole 1 SS tablet PO daily (AI)
- Note: Trimethoprim-sulfamethoxazole also confers protection against toxoplasmosis and some protection against many respiratory bacterial infections. Patients who are receiving pyrimethamine *plus* sulfadiazine for treatment or suppression of toxoplasmosis do not require additional prophylaxis for PCP (AII).

#### Alternative Therapy

- The following regimens can be used for people who are seropositive or seronegative for *Toxoplasma gondii*:
  - Trimethoprim-sulfamethoxazole one DS tablet PO three times weekly (**BI**), *or*
  - Dapsone<sup>a</sup> 50 mg PO daily with pyrimethamine 50 mg *plus* leucovorin 25 mg PO weekly (**BI**), *or*
  - Dapsone<sup>a</sup> 200 mg *plus* pyrimethamine 75 mg *plus* leucovorin 25 mg PO weekly (**BI**), *or*
  - Atovaquone 1,500 mg PO daily with food (**BI**)
- The following regimens should only be used in people who are seronegative for *Toxoplasma gondii*:
  - Dapsone<sup>a</sup> 100 mg PO daily (**BI**), *or*
  - Aerosolized pentamidine 300 mg via Respigard II nebulizer every month (**BI**), *or*
  - Intravenous pentamidine 300 mg every 28 days (**CIII**)

### Indications for Discontinuing Secondary Prophylaxis

- CD4 count increased from  $<200$  cells/mm<sup>3</sup> to  $\geq 200$  cells/mm<sup>3</sup> for  $\geq 3$  months as a result of antiretroviral therapy (AII) *or*
- Can consider if CD4 count 100–200 cells/mm<sup>3</sup> and HIV RNA remains below limits of detection of assay used for 3 to 6 months (BII)
- For people with HIV in whom PCP occurs at a CD4 count  $>200$  cells/mm<sup>3</sup> while not on antiretroviral therapy, discontinuation of prophylaxis can be considered once plasma HIV RNA levels are suppressed to below limits of detection of the assay used for  $\geq 3$  to 6 months, although there are no data to support recommendations in this setting (CIII).

Note: If an episode of PCP occurs at a CD4 count  $>200$  cells/mm<sup>3</sup> while a patient is on antiretroviral therapy, it would be prudent to continue PCP prophylaxis for life, regardless of how high the CD4 cell count rises as a consequence of antiretroviral therapy (BIII).

### Indications for Restarting Secondary Prophylaxis

- CD4 count  $<100$  cells/mm<sup>3</sup> regardless of HIV RNA (AIII), *or*
- CD4 count 100–200 cells/mm<sup>3</sup> and HIV RNA above detection limit of the assay used (AIII)

### Other Considerations

- For people with HIV with non-life-threatening adverse reactions to trimethoprim-sulfamethoxazole, the drug should be continued if clinically feasible.
- If trimethoprim-sulfamethoxazole is discontinued because of a mild adverse reaction, reinstatement of therapy should be considered after the reaction has resolved (**AII**). The dose of trimethoprim-sulfamethoxazole can be increased gradually (desensitization) (**BI**) or the drug can be given at a

reduced dose or frequency (**CIII**).

- Trimethoprim-sulfamethoxazole should be permanently discontinued, with no rechallenge, in people with HIV with life-threatening adverse events, **including** suspected or confirmed Stevens-Johnson Syndrome or toxic epidermal necrolysis (**AIII**). See above for alternative options for secondary PCP prophylaxis.

<sup>a</sup> Whenever possible, patients should be tested for glucose-6-phosphate dehydrogenase (G6PD) deficiency before administration of dapsone or primaquine. An alternative agent should be used if the patient is found to have G6PD deficiency.

Abbreviations: DS = double strength; SS = single strength; PO = orally; PCP = *Pneumocystis pneumonia*

### Rating System for Prevention and Treatment Recommendations

- Strength of Recommendation: A = Strong; B = Moderate; C = Weak
- Quality of Evidence for the Recommendation: I = One or more randomized trials with clinical outcomes and/or validated laboratory endpoints; II = One or more well-designed, non-randomized trials or observational cohort studies with long-term clinical outcomes; III = Expert opinion

Source:

- Panel on Guidelines for the Prevention and Treatment of Opportunistic Infections in Adults and Adolescents with HIV. Guidelines for the prevention and treatment of opportunistic infections in adults and adolescents with HIV. National Institutes of Health, HIV Medicine Association, and Infectious Diseases Society of America. *Pneumocystis Pneumonia*. Updated: September 9, 2025. [[HIV.gov](https://www.hiv.gov)]

Table 4. Initial Therapy for *Toxoplasma gondii* Encephalitis  
Guidelines for the Prevention and Treatment of Opportunistic Infections in Adults and Adolescents with HIV

## Recommendations for Treating Acute *Toxoplasma gondii* Encephalitis

### Preferred Regimens for Acute Infection

- Pyrimethamine 200 mg PO once, followed by weight-based dosing (AI):
  - Body weight  $\leq 60$  kg: pyrimethamine 50 mg PO daily *plus* sulfadiazine 1,000 mg PO every 6 hours *plus* leucovorin 10–25 mg PO daily (can increase to 50 mg daily or twice daily)
  - Body weight  $> 60$  kg: pyrimethamine 75 mg PO daily *plus* sulfadiazine 1,500 mg PO every 6 hours *plus* leucovorin 10–25 mg PO daily (can increase to 50 mg daily or twice daily)

or

- Trimethoprim-Sulfamethoxazole (trimethoprim 5 mg/kg and sulfamethoxazole 25 mg/kg) (IV or PO) twice daily (AII)

**Note:** if pyrimethamine is unavailable or cannot be obtained without delay due to cost or other factors, trimethoprim-sulfamethoxazole should be used in place of pyrimethamine *plus* sulfadiazine (AII).

### Alternative Regimens for Acute Infection

- (Pyrimethamine *plus* leucovorin)<sup>a</sup> *plus* clindamycin 600 mg IV or PO every 6 hours (AI); preferred alternative for patients intolerant of sulfadiazine or who do not respond to pyrimethamine-sulfadiazine; must add additional agent for PCP prophylaxis (AII), *or*
- Atovaquone<sup>b</sup> 1,500 mg PO twice daily *plus* (pyrimethamine + leucovorin)<sup>a</sup> (BII), *or*
- Atovaquone<sup>b</sup> 1,500 mg PO twice daily *plus* sulfadiazine<sup>c</sup> (BII), *or*
- Atovaquone<sup>b</sup> 1,500 mg PO twice daily (BII)
- For patients with a history of sulfa allergy, rapid sulfa desensitization may be attempted using one of several published strategies (BI).
- During the desensitization phase, atovaquone 1,500 mg PO should be administered twice daily until therapeutic doses of trimethoprim-sulfamethoxazole (trimethoprim 5 mg/kg and sulfamethoxazole 25 mg/kg) twice daily are achieved (CIII).

### Total Duration for Treating Acute Infection

- At least 6 weeks (BII); longer duration if clinical or radiologic disease is extensive or response is incomplete at 6 weeks
- After completion of the acute therapy, all patients should be continued on chronic maintenance therapy.

### Other Considerations

- Adjunctive corticosteroids (e.g., dexamethasone) should only be administered when clinically indicated to treat a mass effect associated with focal lesions or associated edema (BIII) or for control of clinically significant immune reconstitution inflammatory syndrome (IRIS) symptoms in conjunction with antiretroviral therapy and anti-toxoplasma therapy (CIII); discontinue as soon as clinically feasible. For patients in whom the diagnosis of toxoplasma encephalitis is presumptive based in part on clinical response, one needs to be careful as central nervous system lymphoma may also respond to steroids clinically and radiologically.
- Antiseizure medications should be administered to patients with toxoplasma encephalitis and associated seizures (AII) and continued through at least the period of acute treatment (BII); antiseizure medications should not be used as prophylaxis in patients without seizures (BII).

<sup>a</sup> Pyrimethamine and leucovorin doses: Same as doses listed in Preferred Regimens for Acute Infection

<sup>b</sup> Atovaquone should be taken with meals or nutritional supplements to ensure adequate oral absorption.

<sup>c</sup> Sulfadiazine dose: Same as weight-based dose and frequency listed in Preferred Regimen for Acute Infection

Abbreviations: PO = orally; IV = intravenous; PCP = *Pneumocystis pneumonia*

#### Rating System for Prevention and Treatment Recommendations

- Strength of Recommendation: A = Strong; B = Moderate; C = Weak
- Quality of Evidence for the Recommendation: I = One or more randomized trials with clinical outcomes and/or validated laboratory endpoints; II = One or more well-designed, non-randomized trials or observational cohort studies with long-term clinical outcomes; III = Expert opinion

Source:

- Panel on Guidelines for the Prevention and Treatment of Opportunistic Infections in Adults and Adolescents with HIV. Guidelines for the prevention and treatment of opportunistic infections in adults and adolescents with HIV. National Institutes of Health, HIV Medicine Association, and Infectious Diseases Society of America. *Toxoplasmosis*. Updated: September 9, 2025. [[HIV.gov](https://www.hiv.gov)]

Table 5. Chronic Maintenance Therapy for *Toxoplasma gondii* Encephalitis  
Guidelines for the Prevention and Treatment of Opportunistic Infections in Adults and Adolescents with HIV

## Chronic Maintenance Therapy for *Toxoplasma gondii* Encephalitis

### Preferred Regimens

- Pyrimethamine 25–50 mg PO daily *plus* sulfadiazine 2,000–4,000 mg PO daily (in 2 to 4 divided doses) *plus* leucovorin 10–25 mg PO daily (AI), *or*
- Trimethoprim-sulfamethoxazole one DS tablet twice daily (AII)

### Alternative Regimens

- (Pyrimethamine 25–50 mg *plus* leucovorin 10–25 mg) PO daily *plus* clindamycin 1,800 mg PO daily (dosed in 3 or 4 divided doses) (BI); must add additional agent to prevent PCP (AII), *or*
- Atovaquone<sup>a</sup> 750–1,500 mg PO twice daily *plus* (pyrimethamine 25 mg *plus* leucovorin 10 mg) PO daily (BII), *or*
- Atovaquone<sup>a</sup> 750–1,500 mg PO twice daily *plus* sulfadiazine 2,000–4,000 mg PO daily (in 2 to 4 divided doses) (BII), *or*
- Atovaquone<sup>a</sup> 750–1,500 mg PO twice daily (BII)

### Criteria for Discontinuing Chronic Maintenance Therapy (BI)

- Successfully completed initial therapy, *and*
- Asymptomatic of signs and symptoms of toxoplasma encephalitis, *and*
- CD4 count >200 cells/mm<sup>3</sup> for >6 months in response to antiretroviral therapy

### Criteria for Restarting Secondary Prophylaxis/Chronic Maintenance Therapy:

- CD4 count <200 cells/mm<sup>3</sup> regardless of HIV RNA level (AIII)

<sup>a</sup> Atovaquone should be taken with meals or nutritional supplement to ensure adequate oral absorption.

### Rating System for Prevention and Treatment Recommendations

- Strength of Recommendation: A = Strong; B = Moderate; C = Weak
- Quality of Evidence for the Recommendation: I = One or more randomized trials with clinical outcomes and/or validated laboratory endpoints; II = One or more well-designed, non-randomized trials or observational cohort studies with long-term clinical outcomes; III = Expert opinion

Source:

- Panel on Guidelines for the Prevention and Treatment of Opportunistic Infections in Adults and Adolescents with HIV. Guidelines for the prevention and treatment of opportunistic infections in adults and adolescents with HIV. National Institutes of Health, HIV Medicine Association, and Infectious Diseases Society of America. *Toxoplasmosis*. Updated: September 9, 2025. [[HIV.gov](https://www.hiv.gov)]

Table 6. Treatment of Disseminated MAC  
Guidelines for the Prevention and Treatment of Opportunistic Infections in Adults and Adolescents with HIV

## Treating Disseminated MAC Disease

### Preferred Therapy:

- At least two drugs as initial therapy to prevent or delay emergence of resistance (AI)
  - Clarithromycin 500 mg PO twice daily (AI) *plus* ethambutol 15 mg/kg PO daily (AI), *or*
  - Azithromycin 500–600 mg PO daily (AII) *plus* ethambutol 15 mg/kg PO daily (AI) when drug interactions or intolerance precludes the use of clarithromycin (AII)
  - **Note:** Testing of susceptibility to clarithromycin or azithromycin is recommended.
- Some experts would add rifabutin when more severe disease manifestations are present.
  - Rifabutin 300 mg PO daily (**CI**). Dose adjustment of rifabutin may be necessary based on drug interactions.
- Some experts would also add a fourth drug if more severe disease is present, the risk of mortality is high, emergence of drug resistance is likely (e.g., after failure of MAC prophylaxis), CD4 count is <50 cells/mm<sup>3</sup>, mycobacterial loads are high (>2 log<sub>10</sub> CFU/mL of blood), or effective antiretroviral therapy is absent (**CIII**). Fourth drug options may include:
  - A fluoroquinolone (**CIII**) (e.g., levofloxacin 500 mg PO daily or moxifloxacin 400 mg PO daily), *or*
  - An injectable aminoglycoside (**CIII**) (e.g., amikacin 10–15 mg/kg IV daily or streptomycin 1 g IV or IM daily) (generally avoided unless in the setting of refractory disease when other alternatives are not available or tolerated)
  - Bedaquiline, tedizolid, linezolid, and omadacycline have demonstrated *in vitro* activity against clinical isolates of MAC; these might also be considered in people with refractory MAC disease.

### Duration of Therapy

- At least 12 months (AII)
- Shorter duration may be considered depending on the degree of immunologic recovery following initiation of antiretroviral therapy; count should be >100 cells/mm<sup>3</sup> for ≥6 months before discontinuation of therapy (**CIII**).

### Other Considerations

- Nonsteroidal anti-inflammatory drugs (NSAIDs) may be used for people with HIV who experience moderate-to-severe symptoms attributed to immune reconstitution inflammatory syndrome (IRIS) (**BIII**).
- If IRIS symptoms persist, a short-term course (4–8 weeks) of systemic corticosteroid therapy (equivalent to prednisone 20–40 mg/day) can be used (**BII**).

Abbreviations: MAC = *Mycobacterium avium* complex; PO = orally; CFU = colony-forming units; IV = intravenous; IM = intramuscular

### Rating System for Prevention and Treatment Recommendations

- Strength of Recommendation: A = Strong; B = Moderate; C = Weak
- Quality of Evidence for the Recommendation: I = One or more randomized trials with clinical outcomes and/or validated laboratory endpoints; II = One or more well-designed, non-randomized trials or observational cohort studies with long-term clinical outcomes; III = Expert opinion

Source:

- Panel on Guidelines for the Prevention and Treatment of Opportunistic Infections in Adults and Adolescents with HIV. Guidelines for the prevention and treatment of opportunistic infections in adults and adolescents with HIV. National Institutes of Health, HIV Medicine Association, and Infectious Diseases Society of America. *Mycobacterium avium* complex disease. Updated: August 15, 2024.



Table 7. Treating Cryptococcal Meningitis: Induction Therapy  
Guidelines for the Prevention and Treatment of Opportunistic Infections in Adults and Adolescents with HIV

### **Cryptococcosis: Treating Central Nervous System and/or Disseminated Disease**

#### **Induction Therapy (Duration: 2 Weeks, Followed by Consolidation Therapy)**

Irrespective of which regimen is used, patients must be followed carefully in the hospital for at least 7 days and ideally 14 days (All). Lumbar puncture should be performed at Day 7 and Day 14 to ensure an appropriate clinical response and culture sterility. If increased intracranial pressure is documented, daily lumbar puncture should be performed until the pressure is decreased into the normal range and symptoms have abated **(All)**.

#### *Preferred Regimens*

- In the United States and other settings where daily monitoring of electrolytes and kidney function and administration of electrolytes and IV fluid is possible:
  -
- In resource-limited health care systems, as recommended by the World Health Organization:
  - flucytosine 25 mg/kg PO four times a day plus fluconazole 1,200 mg PO daily for 2 weeks **(AI)**

Note: Flucytosine dose should be adjusted in renal impairment and ideally use therapeutic drug monitoring.

#### *Alternative Regimens*

- Amphotericin B lipid complex 5 mg/kg IV daily *plus* flucytosine 25 mg/kg PO four times a day for 2 weeks **(BII)**, *or*
- Amphotericin B deoxycholate 1.0 mg/kg IV daily *plus* flucytosine 25 mg/kg PO four times a day for 1 week, followed by fluconazole 1,200 mg PO daily for an additional week **(BI)**

Note: Flucytosine dose should be adjusted in renal impairment and ideally use therapeutic drug monitoring

#### *Additional Studied Regimens (Duration of Therapy: 2 Weeks)*

- Amphotericin B deoxycholate 0.7-1.0 mg/kg IV once daily *plus* flucytosine 25 mg/kg PO four times a day **(BI)**
- Liposomal amphotericin B 3-4 mg/kg IV once daily *plus* fluconazole 800-1,200 mg PO once daily **(BIII)**
- Amphotericin B deoxycholate 0.7-1.0 mg/kg IV once daily *plus* fluconazole 800-1,200 mg PO once daily **(BI)**
- Fluconazole 1,200 mg PO or IV once daily *plus* flucytosine 25 mg/kg PO four times a day **(BII)**

If the patient has not improved clinically or remains clinically unstable, continue or start (liposomal amphotericin B or amphotericin B deoxycholate) plus flucytosine induction therapy until the CSF culture is confirmed to be negative **(BIII)**.

#### *Additional Considerations*

- CSF opening pressure should always be measured when a lumbar puncture is performed. Repeated therapeutic lumbar punctures are essential to manage symptomatic increased intracranial pressure and have a survival benefit
- Corticosteroids should not be used routinely during induction therapy unless used for management of immune reconstitution inflammatory syndrome (

• Corticosteroids, acetazolamide, and mannitol are ineffective in reducing intracranial pressure and  
Abbreviations: PO = orally; IV = intravenously

### Rating System for Prevention and Treatment Recommendations

- Strength of Recommendation: A = Strong; B = Moderate; C = Weak
- Quality of Evidence for the Recommendation: I = One or more randomized trials with clinical outcomes and/or validated laboratory endpoints; II = One or more well-designed, non-randomized trials or observational cohort studies with long-term clinical outcomes; III = Expert opinion

Source:

- Panel on Guidelines for the Prevention and Treatment of Opportunistic Infections in Adults and Adolescents with HIV. Guidelines for the prevention and treatment of opportunistic infections in adults and adolescents with HIV. National Institutes of Health, HIV Medicine Association, and Infectious Diseases Society of America. Cryptococcosis. Updated: October 29, 2024. [[HIV.gov](https://www.hiv.gov)]

Table 8. Treating Cryptococcal Meningitis: Consolidation Therapy  
Guidelines for the Prevention and Treatment of Opportunistic Infections in Adults and Adolescents with HIV

### Treating Cryptococcal Meningitis: Consolidation Therapy

#### Consolidation Therapy (Duration of Therapy: $\geq 8$ Weeks, Followed by Maintenance Therapy)

Perform a lumbar puncture after 1 week and/or 2 weeks of induction therapy to document whether the culture is negative (AII). After 2 weeks of induction therapy, people who are clinically stable may be switched to consolidation therapy while awaiting culture results. Duration of consolidation therapy should be at least 8 weeks after the cerebrospinal culture at 2 weeks is negative (AII).

#### Preferred Regimen

- Fluconazole 800 mg PO once daily (AI)
- For clinically stable patients, continue fluconazole 800 mg until CSF cultures are known to be sterile and antiretroviral therapy has been initiated; the dose then can be reduced to 400 mg PO daily
- If CSF remains positive in a clinically stable patient after 2 weeks of induction therapy, use one of the following two options for an additional 2 weeks before reducing the dose to fluconazole 800 mg PO daily:
  - Fluconazole 1,200 mg PO daily plus flucytosine 25 mg/kg PO four times a day for an additional 2 weeks **(BIII)**, or
  - Fluconazole 1,200 mg PO daily for an additional 2 weeks **(BIII)**

#### Alternative Regimen

- Itraconazole 200 mg PO twice a day, if fluconazole is not available or not tolerated **(CI)**

Abbreviations: PO = orally; CSF = cerebrospinal fluid

#### Rating System for Prevention and Treatment Recommendations

- Strength of Recommendation: A = Strong; B = Moderate; C = Weak
- Quality of Evidence for the Recommendation: I = One or more randomized trials with clinical outcomes and/or validated laboratory endpoints; II = One or more well-designed, non-randomized trials or observational cohort studies with long-term clinical outcomes; III = Expert opinion

Source:

- Panel on Guidelines for the Prevention and Treatment of Opportunistic Infections in Adults and Adolescents with HIV. Guidelines for the prevention and treatment of opportunistic infections in adults and adolescents with HIV. National Institutes of Health, HIV Medicine Association, and Infectious Diseases Society of America. Cryptococcosis. Updated: October 29, 2024. [[HIV.gov](https://www.hiv.gov)]

Table 9. Treating Cryptococcal Meningitis: Maintenance Therapy  
Guidelines for the Prevention and Treatment of Opportunistic Infections in Adults and Adolescents with HIV

## **Cryptococcosis: Treating Central Nervous System and/or Disseminated Disease**

### **Maintenance Therapy**

#### **Recommended Maintenance Therapy**

##### *Preferred Regimen*

- Fluconazole 200 mg PO once daily for at least 1 year from initiation of antifungal therapy (AI)

##### *Alternative Regimen*

- Itraconazole 200 mg PO twice a day
- If susceptibility studies have been performed and the fluconazole MIC is  $\geq 16$   $\mu\text{g/mL}$ , the fluconazole dose may be increased to 400 mg daily (**BIII**).

#### **Criteria for Stopping Maintenance Therapy (BII)**

- At least 1 year from initiation of antifungal therapy, *and*
- Patient remains asymptomatic from cryptococcal infection, *and*
- CD4 count  $\geq 100$  cells/mm<sup>3</sup> and suppressed HIV RNA in response to effective antiretroviral therapy

#### **Restarting Maintenance Therapy**

- If CD4 count declines to  $\leq 100$  cells/mm<sup>3</sup> (AIII)

Abbreviations: PO = orally

#### Rating System for Prevention and Treatment Recommendations

- Strength of Recommendation: A = Strong; B = Moderate; C = Weak
- Quality of Evidence for the Recommendation: I = One or more randomized trials with clinical outcomes and/or validated laboratory endpoints; II = One or more well-designed, non-randomized trials or observational cohort studies with long-term clinical outcomes; III = Expert opinion

Source:

- Panel on Guidelines for the Prevention and Treatment of Opportunistic Infections in Adults and Adolescents with HIV. Guidelines for the prevention and treatment of opportunistic infections in adults and adolescents with HIV. National Institutes of Health, HIV Medicine Association, and Infectious Diseases Society of America. Cryptococcosis. Updated: October 29, 2024. [[HIV.gov](https://www.hiv.gov)]

Table 10. Treatment of CMV Retinitis  
Guidelines for the Prevention and Treatment of Opportunistic Infections in Adults and Adolescents with HIV

## Recommendations for the Treating CMV Retinitis

### General Considerations

- CMV retinitis should be treated with the active participation of an ophthalmologist who is familiar with CMV retinitis diagnosis and management.

### Induction Therapy Followed by Maintenance Therapy

#### Preferred Therapy

- Valganciclovir<sup>a</sup> 900 mg PO every 12 hours for 14–21 days, then maintenance therapy with valganciclovir 900 mg PO once daily (AI), *or*
- Ganciclovir<sup>a</sup> 5 mg/kg IV every 12 hours for 14–21 days, then maintenance therapy with valganciclovir 900 mg PO once daily (AI), *or*
- Ganciclovir<sup>a</sup> 5 mg/kg IV every 12 hours for 14–21 days, then maintenance therapy with ganciclovir 5 mg/kg IV daily (AI)

#### Notes

- Many clinicians prefer the IV formulation when retinitis is more central and sight-threatening or when adequate gastrointestinal absorption is a concern; transition to oral valganciclovir can be considered when there is evidence of clinical response.
- PO valganciclovir is the preferred maintenance regimen as it is the easiest and least toxic to administer to an outpatient population, provided that gastrointestinal absorption is adequate.

#### Alternative Therapy

- Foscarnet<sup>a</sup> 60 mg/kg IV every 8 hours or 90 mg/kg IV every 12 hours for 14–21 days, then maintenance therapy with foscarnet 90 mg/kg or 120 mg/kg IV every 24 hours (BI), *or*
- Cidofovir<sup>a,b</sup> 5 mg/kg/week IV for 2 weeks, then maintenance therapy with cidofovir 5 mg/kg every other week. Administer 1 L of normal saline before and, if additional fluid load can be tolerated, administer another 1 L of normal saline after each cidofovir infusion. Administer probenecid 2 g PO 3 hours before each cidofovir dose followed by 1 g PO 2 hours after the dose, and 1 g PO 8 hours after the dose (total of 4 g)

Note: Cidofovir should be avoided in patients with sulfonamide allergy because of cross-hypersensitivity with probenecid.

#### If Immediate Sight-Threatening Lesions (within 1,500 microns of the fovea or optic disc)

- Add intravitreal injections of ganciclovir (2 mg/injection) or foscarnet (2.4 mg/injection) repeated weekly during the induction period until lesion inactivity is achieved (BIII), then systemic treatment alone is considered to be adequate for maintenance therapy.

Note: Intravitreal administration of cidofovir hypotony of the injected eye

#### Peripheral Lesions

- Valganciclovir<sup>a</sup> 900 mg PO every 12 hours for 14–21 days, then maintenance therapy with 900 mg once daily (AI)

#### Duration of Induction Therapy for CMV Retinitis

- Minimum 14–21 days; duration determined by clinical response based on retinal examination

**Note:** Many clinicians continue induction-level treatment until retinal lesion opacity is resolved or markedly reduced, indicating virus inactivity (**BIII**).

### **Starting Maintenance Therapy for CMV Retinitis**

- Maintenance therapy is started after induction has achieved control of retinitis. Regimens are as detailed above.

### **Immune Reconstitution Uveitis (IRU)**

- The Panel favors the use of both corticosteroids and anti-CMV therapy for active intraocular inflammation at the onset of immune reconstitution uveitis and the use of corticosteroids for cystoid macular edemas, a late complication of immune reconstitution uveitis (CIII).
- Corticosteroids can be administered by oral, periocular, or intravitreal routes.
  - Prednisone 1 mg/kg PO daily (maximum dose of 60–80 mg/day) until clinical response, but for no longer than 1 month, followed by tapering and discontinuation over 2 to 3 months
  - Periocular or intravitreal corticosteroid injections can be repeated after the expected duration of effect if there is evidence of incomplete clinical response and no treatment complications

<sup>a</sup>Renal dose adjustment required in patients with chronic renal insufficiency and/or acute renal failure

<sup>b</sup>Contraindicated for serum creatinine >1.5 mg/dL or creatinine clearance <55 mL/min

Abbreviations: CMV = cytomegalovirus; IV = intravenous; PO = orally

### Rating System for Prevention and Treatment Recommendations

- Strength of Recommendation: A = Strong; B = Moderate; C = Weak
- Quality of Evidence for the Recommendation: I = One or more randomized trials with clinical outcomes and/or validated laboratory endpoints; II = One or more well-designed, non-randomized trials or observational cohort studies with long-term clinical outcomes; III = Expert opinion

Source:

- Panel on Guidelines for the Prevention and Treatment of Opportunistic Infections in Adults and Adolescents with HIV. Guidelines for the prevention and treatment of opportunistic infections in adults and adolescents with HIV. National Institutes of Health, HIV Medicine Association, and Infectious Diseases Society of America. Cytomegalovirus disease. Updated: July 14, 2025. [[HIV.gov](https://www.hiv.gov)]

Table 11. Treatment of CMV Esophagitis or Colitis  
Guidelines for the Prevention and Treatment of Opportunistic Infections in Adults and Adolescents with HIV

## Treatment of CMV Esophagitis or Colitis

### Recommended Treatment Regimens

#### Preferred Therapy

- Ganciclovir<sup>a</sup> 5 mg/kg IV every 12 hours **(AI)**; may switch to valganciclovir 900 mg PO every 12 hours once the patient can absorb and tolerate PO therapy (AIII).
- Valganciclovir<sup>a</sup> 900 mg PO every 12 hours can be used in patients with mild disease **(AIII)**.

#### Alternative Therapy

- Foscarnet<sup>a</sup> 60 mg/kg IV every 8 hours or 90 mg/kg IV every 12 hours (BIII)—for patients with treatment-limiting toxicities to ganciclovir or with ganciclovir resistance; *or*
- Cidofovir<sup>a,b</sup> 5 mg/kg/week IV for 2 weeks, then 5 mg/kg IV every other week. Administer 1 liter of normal saline before and, if additional fluid load can be tolerated, administer another 1 liter of normal saline after cidofovir infusion. Administer probenecid 2 g PO 3 hours before each cidofovir dose, followed by 1 g PO 2 hours after the dose and 1 g PO 8 hours after the dose (total of 4 g)(CI).

### Duration of Anti-CMV Therapy:

- 21–42 days or until signs and symptoms have resolved (AIII).

**Note:** After resolution of acute disease, maintenance therapy is not routinely recommended for CMV gastrointestinal disease unless there is concurrent retinitis, there have already been recurrent infections, or severe disease was present initially.

<sup>a</sup>Renal dose adjustment required in patients with chronic renal insufficiency and/or acute renal failure

<sup>b</sup>Contraindicated for serum creatinine >1.5 mg/dL or creatinine clearance <55 mL/min

Abbreviations: CMV = cytomegalovirus; IV = intravenous; PO = orally

### Rating System for Prevention and Treatment Recommendations

- Strength of Recommendation: A = Strong; B = Moderate; C = Weak
- Quality of Evidence for the Recommendation: I = One or more randomized trials with clinical outcomes and/or validated laboratory endpoints; II = One or more well-designed, non-randomized trials or observational cohort studies with long-term clinical outcomes; III = Expert opinion

Source:

- Panel on Guidelines for the Prevention and Treatment of Opportunistic Infections in Adults and Adolescents with HIV. Guidelines for the prevention and treatment of opportunistic infections in adults and adolescents with HIV. National Institutes of Health, HIV Medicine Association, and Infectious Diseases Society of America. Cytomegalovirus disease. Updated: July 14, 2025. [[HIV.gov](https://www.hiv.gov)]

Table 12. Recommendations for Treating and Monitoring Progressive Multifocal Leukoencephalopathy (PML) Guidelines for the Prevention and Treatment of Opportunistic Infections in Adults and Adolescents with HIV

### Recommendations for Treating PML

The main approach to treatment is to preserve immune function and reverse HIV-associated immunosuppression with effective antiretroviral therapy.

- In patients not on antiretroviral therapy who are diagnosed with PML, antiretroviral therapy should be (re)started immediately (AII).
- In patients who are receiving antiretroviral therapy but remain viremic because of inadequate adherence or drug resistance, antiretroviral therapy should be optimized to achieve HIV suppression (AIII).
- No role for antiretroviral therapy intensification in patients with HIV viral suppression (BII).
- Antiretroviral therapy regimens should be selected based on the likelihood of achieving virologic suppression and not on the central nervous system penetration-effectiveness (CPE) score (BII).
- No effective direct-acting antiviral therapy exists for preventing or treating JCV infections or PML.
- The following agents are **not recommended** for the treatment of PML: cytarabine (AII), cidofovir (AII), interferon-alpha (BIII), interleukin-2 (BIII), topotecan (BIII), pembrolizumab (BIII).
- The following agents are **not recommended** due to limited data: 5HT2a receptor antagonist (e.g., olanzapine, ziprasidone, mirtazapine, cyproheptadine, risperidone) (BIII), mefloquine (BIII). Expert consultation is recommended prior to initiation of these agents.
- PML-IRIS may require administration of corticosteroid therapy (BIII). The optimal corticosteroid regimen has not been established but should be tailored to individual patients. Antiretroviral therapy should NOT be discontinued during PML-IRIS (AIII).

### Recommendations for Monitoring PML

- Timing of follow-up assessments (clinical, lumbar puncture, and MRI) should be guided by clinical progress (BIII).
- In patients who appear stable or improved, neuroimaging can be obtained 6 to 8 weeks after antiretroviral therapy initiation (BIII).
- In patients who clinically worsen before or after this 6- to 8-week period, repeat magnetic resonance imaging (MRI) should be obtained as soon as worsening is recognized (BIII).

Abbreviations: PML= progressive multifocal leukoencephalopathy; IRIS = immune reconstitution inflammatory syndrome

### Rating System for Prevention and Treatment Recommendations

- Strength of Recommendation: A = Strong; B = Moderate; C = Weak
- Quality of Evidence for the Recommendation: I = One or more randomized trials with clinical outcomes and/or validated laboratory endpoints; II = One or more well-designed, non-randomized trials or observational cohort studies with long-term clinical outcomes; III = Expert opinion

Source:

- Panel on Guidelines for the Prevention and Treatment of Opportunistic Infections in Adults and Adolescents with HIV. Guidelines for the prevention and treatment of opportunistic infections in adults and adolescents with HIV. National Institutes of Health, HIV Medicine Association, and Infectious Diseases Society of America. Progressive multifocal leukoencephalopathy/JC virus infection. Last updated: October 19, 2022. [[HIV.gov](https://www.hiv.gov)]

Table 13. Treating Esophageal Candidiasis  
Guidelines for the Prevention and Treatment of Opportunistic Infections in Adults and Adolescents with HIV

### Treating Esophageal Candidiasis (Duration of Therapy 14 to 21 Days)

**Note:** Systemic antifungals are required for effective treatment of esophageal candidiasis (AI); topical therapy alone is not recommended (AI).

#### Preferred Therapy

- Fluconazole 200-mg loading dose, followed by fluconazole 100–200 mg (up to 400 mg) PO or IV daily **(AI)**; consider oral suspension for people with severe symptoms and difficulty swallowing.

#### Alternative Therapy

- Itraconazole oral solution 200 mg PO daily (AI), *or*
- Isavuconazole 400 mg PO as a loading dose, followed by isavuconazole 100 mg PO daily **(BI)**, *or*
- Isavuconazole 400 mg PO once weekly (BI), *or*
- Voriconazole 200 mg PO or IV twice daily (BI), *or*
- Posaconazole oral suspension 400 mg (10 mL) PO twice daily for 1 day, then 400 mg daily **(BI)**, *or*
- Posaconazole tablet 300 mg PO twice daily for 1 day, then 300 mg daily **(BI)**, *or*
- Lipid formulation of amphotericin B 3–4 mg/kg IV daily (BI), *or*
- Caspofungin 70-mg loading dose IV, followed by 50 mg IV daily **(BI)**, *or*
- Micafungin 150 mg IV daily (BI), *or*
- Anidulafungin 100 mg IV for one dose, then 50 mg IV daily (BI)

**Note:** A higher rate of esophageal candidiasis relapse has been reported with echinocandins than with fluconazole.

#### Other Considerations

- Systemic azoles may have **significant** drug–drug interactions with antiretroviral drugs and other drugs used for the treatment of opportunistic infections. Consider therapeutic drug monitoring if prolonged use is indicated.
- Fluconazole, itraconazole, posaconazole, and voriconazole can increase the risk for QTc prolongation, especially when coadministered with other QTc prolonging drugs that are cleared by CYP3A4.
- Chronic or prolonged use of azoles might promote development of resistance.

Abbreviations: PO= orally; IV = intravenously; QTc = QT corrected for heart rate

#### Rating System for Prevention and Treatment Recommendations

- Strength of Recommendation: A = Strong; B = Moderate; C = Weak
- Quality of Evidence for the Recommendation: I = One or more randomized trials with clinical outcomes and/or validated laboratory endpoints; II = One or more well-designed, non-randomized trials or observational cohort studies with long-term clinical outcomes; III = Expert opinion

Source:

- Panel on Guidelines for the Prevention and Treatment of Opportunistic Infections in Adults and Adolescents with HIV. Guidelines for the prevention and treatment of opportunistic infections in adults and adolescents with HIV. National Institutes of Health, HIV Medicine Association, and Infectious Diseases Society of America. Candidiasis (Mucocutaneous). September 16, 2024. [[HIV.gov](https://www.hiv.gov)]

Table 14. Treating Histoplasmosis  
Guidelines for the Prevention and Treatment of Opportunistic Infections in Adults and Adolescents with HIV

### Treating *Histoplasma capsulatum* Infections

#### Treating Severe Disseminated Disease

##### Induction Therapy (≥2 Weeks or Until Clinically Improved)

###### *Preferred Therapy*

- Liposomal amphotericin B: 3 mg/kg IV daily (AI)

###### *Alternative Therapy:*

- Amphotericin B lipid complex: 5 mg/kg IV daily (AIII)

##### Maintenance Therapy (≥12 months)

###### *Preferred Therapy*

- Itraconazole: 200 mg PO three times a day for 3 days, then 200 mg PO two times a day (AII)

###### *Alternative Therapy*

**Note:** these recommendations are based on limited clinical data for people who are intolerant to itraconazole and only moderately ill.

- Posaconazole: 300 mg extended-release tablet PO twice daily for 1 day, then 300 mg PO once daily (BIII), *or*
- Voriconazole: 400 mg PO twice daily for 1 day, then 200 mg PO twice daily (BIII), *or*
- Fluconazole: 800 mg PO once daily (CII)

#### Treating Mild-to-Moderate Disseminated Disease or Acute Pulmonary Histoplasmosis in People with a CD4 Count <300 cells/mm<sup>3</sup>

##### Induction and Maintenance Therapy (≥12 Months)

###### *Preferred Therapy*

- Itraconazole: 200 mg PO three times a day for 3 days, then 200 mg PO two times a day (AII)

###### *Alternative Therapy*

- Posaconazole: 300 mg extended-release tablet PO twice daily for 1 day, then 300 mg PO once daily (BIII), *or*
- Voriconazole: 400 mg PO twice daily for 1 day, then 200 mg PO twice daily (BIII), *or*
- Fluconazole: 800 mg PO once daily (CII)

#### Treating *Histoplasma* Meningitis

##### Induction Therapy (4–6 weeks Depending on Symptom Resolution and Improvement of CSF Findings)

###### *Preferred Therapy*

- Liposomal amphotericin B: 5 mg/kg IV daily (AIII)

### *Alternative Therapy*

- Amphotericin B deoxycholate: 0.7-1.0 mg/kg IV daily (BIII)

### **Maintenance Therapy (≥12 Months and Until Resolution of Abnormal CSF Findings)**

#### *Preferred Therapy*

- Itraconazole: 200 mg PO two or three times a day (AIII)

#### *Alternative Therapy*

**Note:** These recommendations are based on limited clinical data for people who are intolerant to itraconazole and only moderately ill.

- Voriconazole: 400 mg PO twice daily for 1 day, then 200 mg PO twice daily (BIII), *or*
- Fluconazole: 800 mg PO once daily (CII)—for people who cannot tolerate both itraconazole and voriconazole

Abbreviations: PO = orally

### Rating System for Prevention and Treatment Recommendations

- Strength of Recommendation: A = Strong; B = Moderate; C = Weak
- Quality of Evidence for the Recommendation: I = One or more randomized trials with clinical outcomes and/or validated laboratory endpoints; II = One or more well-designed, non-randomized trials or observational cohort studies with long-term clinical outcomes; III = Expert opinion

Source:

- Panel on Guidelines for the Prevention and Treatment of Opportunistic Infections in Adults and Adolescents with HIV. Guidelines for the prevention and treatment of opportunistic infections in adults and adolescents with HIV. National Institutes of Health, HIV Medicine Association, and Infectious Diseases Society of America. Histoplasmosis. Last updated: October 29, 2024. [[HIV.gov](https://www.hiv.gov)]

Table 15. Treatment of Histoplasmosis: Long-Term Suppressive Therapy  
Guidelines for the Prevention and Treatment of Opportunistic Infections in Adults and Adolescents with HIV

## **Treatment of *Histoplasma capsulatum* Infections: Long Term Suppressive Therapy**

### **Indications**

- Severe disseminated or central nervous system infection after completing  $\geq 12$  months of treatment (AIII), *or*
- Relapse despite appropriate initial therapy (BIII)

### **Recommended Suppressive Therapy**

#### *Preferred Therapy*

- Itraconazole 200 mg PO once daily (AIII)

#### *Alternative Therapy*

Note: These recommendations are based on limited clinical data for people who are intolerant to itraconazole.

- Fluconazole 400 mg PO once daily (CII), *or*
- Voriconazole 200 mg PO twice daily (BIII), *or*
- Posaconazole 300 mg daily (BIII)

### **Criteria for Discontinuing Long-Term Suppressive Therapy (All)**

- Receipt of azole treatment for  $>1$  year, *and*
- Negative fungal blood cultures, *and*
- Serum or urine *Histoplasma* antigen below the level of quantification, *and*
- Undetectable HIV viral load on stable antiretroviral therapy, *and*
- CD4 count  $\geq 150$  cells/mm<sup>3</sup> and on antiretroviral therapy for  $\geq 6$  months

### **Indication for Restarting Long-Term Suppressive Therapy**

- CD4 count  $<150$  cells/mm<sup>3</sup> (BIII)

Abbreviations: PO = orally\_

### Rating System for Prevention and Treatment Recommendations

- Strength of Recommendation: A = Strong; B = Moderate; C = Weak
- Quality of Evidence for the Recommendation: I = One or more randomized trials with clinical outcomes and/or validated laboratory endpoints; II = One or more well-designed, non-randomized trials or observational cohort studies with long-term clinical outcomes; III = Expert opinion

Source:

- Panel on Guidelines for the Prevention and Treatment of Opportunistic Infections in Adults and Adolescents with HIV. Guidelines for the prevention and treatment of opportunistic infections in adults and adolescents with HIV. National Institutes of Health, HIV Medicine Association, and Infectious Diseases Society of America. Histoplasmosis. Last updated: October 29, 2024. [[HIV.gov](https://www.hiv.gov)]

Table 16. Recommended Initial Treatment of Coccidioidomycosis  
Guidelines for the Prevention and Treatment of Opportunistic Infections in Adults and Adolescents with HIV

## Initial Treatment of Coccidioidomycosis

### Mild-to-Moderate Pulmonary Infections

#### *Indications for Treatment*

- Clinically mild infection, such as focal pneumonia

#### *Preferred Therapy*

- Fluconazole 400 mg PO once daily (All), *or*
- Itraconazole 200 mg PO three times daily for 3 days, then twice daily (All)

#### *Alternative Therapy (for Patients Who Failed to Respond to Fluconazole or Itraconazole):*

- Voriconazole loading dose of 400 mg twice daily on Day 1, followed by 200 mg PO twice daily (BIII), *or*
- Posaconazole (delayed-release tablet) 300 mg PO twice daily on Day 1, followed by 300 mg daily (BIII), *or*
  
- Isavuconazole sulfate 372 mg (isavuconazole 200 mg) PO every 8 hours for six doses, followed by isavuconazole sulfate 372 mg (isavuconazole 200 mg) PO once daily (BIII)

### Severe Pulmonary or Extrapulmonary Infection (Except Meningitis)

#### *Preferred Therapy*

- Amphotericin B deoxycholate 0.7–1.0 mg/kg IV daily (All), *or*
- Lipid formulation amphotericin B 3–5 mg/kg IV daily (AIII), particularly for those with underlying renal dysfunction

Note: Use until clinical improvement, then switch to triazole (fluconazole 400 mg PO daily or itraconazole 200 mg PO twice daily) (BIII).

#### *Alternative Therapy*

- Some specialists recommend combining amphotericin B deoxycholate or lipid formulation amphotericin B with a triazole (fluconazole or itraconazole 400 mg daily) as initial therapy and continue the triazole once amphotericin B is stopped (CIII).

### Treatment For Meningeal Infections (Consultation with a Specialist Is Advised [AIII])

#### *Preferred Therapy*

- Fluconazole 800–1,200 mg PO once daily (All)

#### *Alternative Therapy*

- Itraconazole 200 mg PO two to three times daily (BII), *or*
- Voriconazole 200–400 mg PO twice daily (BIII), *or*
- Posaconazole (delayed-release tablet) 300 mg twice on Day 1, followed by 300 mg PO once daily (CIII), *or*
- Isavuconazole sulfate 372 mg (isavuconazole 200 mg) PO every 8 hours for six doses, followed by isavuconazole sulfate 372 mg (isavuconazole 200 mg) PO once daily (CIII), *or*

- Intrathecal amphotericin B deoxycholate (AIII) when triazole antifungals are not effective. Use in consultation with a specialist and should be administered by a clinician experienced in this drug delivery technique.

### **Treatment in Pregnancy**

#### *Preferred Therapy During the First Trimester*

- Lipid formulation amphotericin B 3–5 mg/kg IV daily (AIII), *or*
- Amphotericin B deoxycholate 0.7–1.0 mg/kg IV daily (AIII)

Note: In general, azole antifungal agents should be avoided in the first trimester of pregnancy because of potential teratogenic effect, unless benefit is thought to outweigh risk (BIII).

#### *Preferred Therapy During the Second or Third Trimester*

- After the first trimester or when disease is diagnosed after the first trimester, treatment with fluconazole or itraconazole could be considered

### **Other Considerations**

- Certain patients with meningitis may develop hydrocephalus and require CSF shunting in addition to antifungal therapy. Use of corticosteroids is not recommended.
- All the triazole antifungals have the potential to interact with certain antiretroviral therapy agents and other anti-infective agents. These interactions are complex and can be bidirectional.

Abbreviations; CSF = cerebrospinal fluid; PO = oral; IV = intravenous

### Rating System for Prevention and Treatment Recommendations

- Strength of Recommendation: A = Strong; B = Moderate; C = Weak
- Quality of Evidence for the Recommendation: I = One or more randomized trials with clinical outcomes and/or validated laboratory endpoints; II = One or more well-designed, non-randomized trials or observational cohort studies with long-term clinical outcomes; III = Expert opinion

Source:

- Panel on Guidelines for the Prevention and Treatment of Opportunistic Infections in Adults and Adolescents with HIV. Guidelines for the prevention and treatment of opportunistic infections in adults and adolescents with HIV. National Institutes of Health, HIV Medicine Association, and Infectious Diseases Society of America. Coccidioidomycosis. Updated: October 29, 2024. [[HIV.gov](https://www.hiv.gov)]

Table 17. Discontinuing Therapy for Coccidioidomycosis  
Guidelines for the Prevention and Treatment of Opportunistic Infections in Adults and Adolescents with HIV

## Discontinuing Therapy for Coccidioidomycosis

### Focal Coccidioidal Pneumonia (AII)

#### Discontinuation can be considered after the following:

- Clinically response to 3 to 6 months of antifungal therapy, *and*
- CD4 count  $\geq 250$  cells/mm<sup>3</sup>, *and*
- Virologic suppression on antiretroviral therapy, *and*
- Continued monitoring for recurrence can be performed using serial chest radiograph and coccidioidal serology

### Diffuse Pulmonary Disease or Non-Meningeal Disseminated Coccidioidomycosis

- Relapse can occur in 25% to 33% of patients without HIV and in people with HIV who have a CD4 count  $>250$  cells/mm<sup>3</sup>.
- Discontinuation may be considered after  $\geq 12$  months of therapy based on clinical and serological response, and the

decision should be made in consultation with experts **(BIII)**.

- For diffuse pulmonary disease, continued monitoring for recurrence can be performed using serial chest radiograph and coccidioidal serology.

### Coccidioidal Meningitis

- Relapse has been reported in 80% of patients after stopping triazoles; suppressive therapy at treatment doses should be lifelong. Discontinuation of therapy **is not recommended**

#### Rating System for Prevention and Treatment Recommendations

- Strength of Recommendation: A = Strong; B = Moderate; C = Weak
- Quality of Evidence for the Recommendation: I = One or more randomized trials with clinical outcomes and/or validated laboratory endpoints; II = One or more well-designed, non-randomized trials or observational cohort studies with long-term clinical outcomes; III = Expert opinion

Source:

- Panel on Guidelines for the Prevention and Treatment of Opportunistic Infections in Adults and Adolescents with HIV. Guidelines for the prevention and treatment of opportunistic infections in adults and adolescents with HIV. National Institutes of Health, HIV Medicine Association, and Infectious Diseases Society of America. Coccidioidomycosis. Updated: October 29, 2024. [[HIV.gov](https://www.hiv.gov)]

Table 18. Recommendations for Treating Cryptosporidiosis  
Guidelines for the Prevention and Treatment of Opportunistic Infections in Adults and Adolescents with HIV

## Recommendations for Treating Cryptosporidiosis

### Managing Cryptosporidiosis

#### *Preferred Management Strategies*

- Aggressive oral and/or IV rehydration and replacement of electrolyte loss (AIII), *and*
- Symptomatic treatment of diarrhea with anti-motility agents (AIII); tincture of opium may be more effective than loperamide (CIII).
- People with HIV not taking antiretroviral therapy should initiate antiretroviral therapy to achieve immune restoration to CD4 count >100 cells/mm<sup>3</sup> (AII).

#### *General Considerations*

- Nitazoxanide 500 mg to 1000 mg PO twice daily with food for at least 14 days (CIII) plus optimized antiretroviral therapy, symptomatic treatment, and rehydration and electrolyte replacement, *or*
- Paromomycin 500 mg PO four times a day for at least 14 to 21 days (CIII) plus optimized antiretroviral therapy, symptomatic treatment, and rehydration and electrolyte replacement

#### *Pregnancy Considerations*

- Rehydration and initiation of antiretroviral therapy are the mainstays of initial treatment of cryptosporidiosis **(AII)**.
- Opiate exposure in late pregnancy has been associated with neonatal respiratory depression, and chronic exposure may result in neonatal withdrawal; therefore, tincture of opium **is not recommended** in late pregnancy **(AIII)**.
- Loperamide is the preferred antimotility agent in late pregnancy **(CIII)**. Loperamide should be avoided in the first trimester unless benefits are felt to outweigh potential risks **(CIII)**.
- Nitazoxanide **(CIII)** and paromomycin **(CIII)** can be used in pregnancy after the first trimester.

### Other Considerations

- Because diarrhea can cause lactase deficiency, people with cryptosporidiosis should avoid milk products (CIII).

Abbreviations: IV = intravenous; PO = orally

### Rating System for Prevention and Treatment Recommendations

- Strength of Recommendation: A = Strong; B = Moderate; C = Optional
- Quality of Evidence for the Recommendation: I = One or more randomized trials with clinical outcomes and/or validated laboratory endpoints; II = One or more well-designed, non-randomized trials or observational cohort studies with long-term clinical outcomes; III = Expert opinion

Source:

- Panel on Guidelines for the Prevention and Treatment of Opportunistic Infections in Adults and Adolescents with HIV. Guidelines for the prevention and treatment of opportunistic infections in adults and adolescents with HIV. National Institutes of Health, HIV Medicine Association, and Infectious Diseases Society of America. Cryptosporidiosis. Last updated: January 18, 2023. [[HIV.gov](https://www.hiv.gov)]

Table 19. Treatment of Acute *Cystoisospora belli* Infection  
Guidelines for the Prevention and Treatment of Opportunistic Infections in Adults and Adolescents with HIV

## Recommendations for Treating Acute *Cystoisospora belli* Infection

### General Management Considerations

- Fluid and electrolyte support in patients with dehydration (AIII)
- Nutritional supplementation for malnourished patients (AIII)

### Preferred Therapy for Acute Infection

- Trimethoprim-sulfamethoxazole (160 mg/800 mg) PO (or IV) four times daily for 10 days (AII), *or*
- Trimethoprim-sulfamethoxazole (160 mg/800 mg) PO (or IV) twice daily for 7 days (BI), *or*
  - In patients with persistent or worsening symptoms while on trimethoprim-sulfamethoxazole (160 mg/800 mg) twice daily, consider increasing the daily dose and/or extending the duration to 3–4 weeks (BIII)

**Note:** IV trimethoprim-sulfamethoxazole may be used for patients with potential or documented malabsorption.

### Alternative Therapy for Acute Infection (for Patients with Sulfa Intolerance [AIII])

- Pyrimethamine 50–75 mg PO daily *plus* leucovorin 10–25 mg PO daily for 4 weeks (BIII), *or*
- Ciprofloxacin 500 mg PO or 400 mg IV (for those who cannot tolerate PO) twice daily for 7 days (CI)

Abbreviations: IV = intravenous; PO = orally

### Rating System for Prevention and Treatment Recommendations

- Strength of Recommendation: A = Strong; B = Moderate; C = Weak
- Quality of Evidence for the Recommendation: I = One or more randomized trials with clinical outcomes and/or validated laboratory endpoints; II = One or more well-designed, non-randomized trials or observational cohort studies with long-term clinical outcomes; III = Expert opinion

Source:

- Panel on Guidelines for the Prevention and Treatment of Opportunistic Infections in Adults and Adolescents with HIV. Guidelines for the prevention and treatment of opportunistic infections in adults and adolescents with HIV. National Institutes of Health, HIV Medicine Association, and Infectious Diseases Society of America. Cystoisosporiasis (formerly Isosporiasis). Last updated: April 23, 2025. [[HIV.gov](https://www.hiv.gov)]

Table 20. *Cystoisospora belli* Infection: Chronic Maintenance Therapy (Secondary Prophylaxis)  
Guidelines for the Prevention and Treatment of Opportunistic Infections in Adults and Adolescents with HIV

**Recommendations for Treating *Cystoisospora belli* Infection  
Chronic Maintenance Therapy (Secondary Prophylaxis) in People with HIV and CD4 count <200 cells/mm<sup>3</sup>**

*Preferred Therapy*

- Trimethoprim-sulfamethoxazole (160 mg/800 mg) PO three times weekly (AI), *or*
- Trimethoprim-sulfamethoxazole (160 mg/800 mg) PO daily (AIII)

*Alternative Therapy*

- Trimethoprim-sulfamethoxazole (320 mg/1,600 mg) PO 3 times weekly (BIII), *or*
- Pyrimethamine 25 mg PO daily *plus* leucovorin 5–10 mg PO daily (BIII), *or*
- Ciprofloxacin 500 mg PO 3 times weekly (CI) as a second-line alternative

**Criteria for Discontinuation of Chronic Maintenance Therapy**

- Sustained increase in CD4 count >200 cells/mm<sup>3</sup> for >6 months in response to antiretroviral therapy and without evidence of active *C. belli* infection (BIII)

Abbreviations: PO = orally

Rating System for Prevention and Treatment Recommendations

- Strength of Recommendation: A = Strong; B = Moderate; C = Weak
- Quality of Evidence for the Recommendation: I = One or more randomized trials with clinical outcomes and/or validated laboratory endpoints; II = One or more well-designed, non-randomized trials or observational cohort studies with long-term clinical outcomes; III = Expert opinion

Source:

- Panel on Guidelines for the Prevention and Treatment of Opportunistic Infections in Adults and Adolescents with HIV. Guidelines for the prevention and treatment of opportunistic infections in adults and adolescents with HIV. National Institutes of Health, HIV Medicine Association, and Infectious Diseases Society of America. Cystoisosporiasis (formerly Isosporiasis). Last updated: April 23, 2025. [[HIV.gov](https://www.hiv.gov)]

