

Oral Manifestations

This is a PDF version of the following document:

Module 2: [Basic HIV Primary Care](#)

Lesson 2: [Oral Manifestations](#)

You can always find the most up-to-date version of this document at

<https://www.hiv.uw.edu/go/basic-primary-care/oral-manifestations/core-concept/all>.

Topic Overview

Background

The oral manifestations of HIV disease are manifold, prevalent, and clinically significant.[1] Although the recognition and management of HIV-related oral manifestations remains an important area of study for clinicians who provide medical care to persons with HIV, the referral of patients for routine and preventive dental care is equally important to maintaining patients' oral health and quality of life.[1] This topic will primarily focus on common HIV-related oral conditions, including oral candidiasis, oral hairy leukoplakia, oral viral infections, ulcerative disease, and malignancies. In addition, this lesson will also review several general oral health issues, including periodontal and salivary gland findings among individuals with HIV infection.

Oral Examination

A comprehensive oral examination should include both visual and tactile components, beginning with careful inspection of the face, neck, lips and all components of the mouth, including the roof, floor, sides, tongue, tonsillar pillars, and back of the throat, followed by manual palpation. A detailed patient history is often helpful in directing the examiner to explore a particular area in greater detail. The American Dental Association has produced an excellent oral examination video titled "How to Check Patients for Oral Cancer."

[Activity] A. How to Check Patients for Oral Cancer

Oral Health and HIV

With the advent of effective antiretroviral therapies, the prevalence of some HIV-related oral manifestations has decreased, particularly those disorders associated with lower CD4 cell counts, such as oral candidiasis, oral hair leukoplakia, and oral Kaposi's sarcoma.[2] At the same time, there has been a wider recognition of the role of common oral conditions such as dental caries and periodontal disease in malnutrition and weight loss and a renewed focus on the importance of routine and preventative dental care for patients with HIV.[3] Achieving good oral health improves a person's oral function and increases their quality of life—as measured by self-confidence, social acceptance, and employability, as well as having a positive influence on systemic health.[4,5] Individuals with HIV may develop gingivitis, periodontitis, and more severe manifestations of periodontal disease, particularly linear gingival erythema, necrotizing ulcerative gingivitis and necrotizing ulcerative periodontitis ([Figure 1](#)).[1,6,7,8]

Dental Caries and Periodontal Disease

Individuals with HIV are also at increased risk for dental caries, though this does not appear to be based on a person's level of immunologic suppression.[9] Several factors contribute to the increased rates of dental caries (and periodontal disease), including inadequate dental hygiene, poor diet, overgrowth of atypical bacterial pathogens, and HIV-associated salivary gland hypofunction or xerostomia.[8,10] For people with HIV, xerostomia may occur as a result of medication use, especially agents used in the treatment of HIV co-morbidities, or is related to HIV-related salivary gland disease.[10,11]. Salivary gland disease in persons with HIV often manifests as the enlargement of one or more major salivary glands and encompasses a number of neoplastic and non-neoplastic conditions. Salivary gland disease in people with HIV has also been associated with BK polyomavirus infection and also as part of immune reconstitution inflammatory syndrome (IRIS).[10,12] Severe dental and periodontal breakdown may be observed among individuals with chronic methamphetamine use—a finding often referred to as “meth mouth” and one that requires prompt identification and referral for care.[1]

Access to Oral Health Services

Clinicians who provide medical care to persons with HIV should have information about access to oral health providers in their area who can provide oral health services to people with HIV. Access to oral health services for people with HIV can be complicated by a lack of insurance coverage for dental care and a shortage of dentists who are trained and/or willing to see individuals with HIV, even for routine periodontal care.

Oral Candidiasis

Background

Oropharyngeal candidiasis is seen frequently among individuals with HIV and is an indicator of immune suppression.[13,14] It occurs most often in patients with CD4 cell counts less than 200 cells/mm³. *Candida albicans* is the most common species involved, but non-*albicans* species (*C. dubliniensis*, *C. glabrata*, *C. tropicalis*) can also cause disease.[15] The introduction and widespread use of effective antiretroviral therapy has led to a marked decrease in the prevalence of oral candidiasis. Although HIV-related immune suppression is typically the most important risk factor for developing oral candidiasis, other causes for oral candidiasis include antibiotic use, corticosteroids, chemotherapeutic drugs, and diabetes. By maximizing immune status with effective antiretroviral therapy, most cases of candidiasis can be avoided.

Clinical Manifestations

Among individuals with HIV, there are four different manifestations of oral candidiasis: pseudomembranous candidiasis (thrush), atrophic (erythematous) candidiasis, angular cheilitis (perleche) and rarely, hyperplastic candidiasis. Individuals with HIV who have either pseudomembranous or erythematous disease often complain of a burning sensation and altered taste.

Pseudomembranous Candidiasis

This form of candidiasis manifests as painless, creamy white plaques or patches that can be easily scraped off with a tongue depressor. Pseudomembranous candidiasis may involve any oral mucosal surface, including the palate, buccal mucosa, gingiva, and tongue ([Figure 2](#)).

Erythematous Candidiasis

Erythematous candidiasis, which is less common than pseudomembranous candidiasis, typically presents as flat red patches, most commonly on the hard palate and the dorsal surface of the tongue as areas of depapillation and fissuring ([Figure 3](#)).

Hyperplastic candidiasis

This type of oral candidiasis is uncommon and may present as inflamed regions with a cobble stone appearance under dental prostheses or as well-demarcated white plaques on buccal mucosa, inner commissures of the lips or lateral aspects of the tongue that do not scrape off ([Figure 4](#)).

Angular cheilitis

This form of oral candidiasis manifests as erythema and splitting of the corners of the mouth ([Figure 5](#)); if not treated, this can progress to a chronic, non-healing ulcer.

Diagnosis

A presumptive diagnosis of oropharyngeal candidiasis is based on typical clinical appearance or on a favorable response to an empiric trial of antifungal medication.[16] A definitive diagnosis of oropharyngeal

candidiasis requires obtaining a direct smear and performing a potassium hydroxide (KOH) wet mount, periodic acid-Schiff (PAS) stain, or Gram’s stain and seeing characteristic yeasts. Fungal cultures are reserved for patients who do not respond to first-line therapy or for cases of suspected antifungal resistance.

Treatment

Episodic treatment of clinical episodes is strongly preferred over chronic suppressive therapy, mainly because of the risk of developing antifungal drug resistance with chronic therapy. Chronic suppressive therapy is not recommended unless the individual has frequent or severe recurrences of mucosal candidiasis. In addition, routine primary prophylaxis is not recommended because oral candidiasis has relatively low attributable morbidity, and acute treatment is highly effective.^[16] In the Adult and Adolescent OI Guidelines, oral fluconazole is the drug of choice for treating oropharyngeal candidiasis based on its efficacy, convenience, and tolerability. The treatment duration is 7 to 14 days, regardless of which type of medication is used.^[16]

Table 1. Guidelines for the Prevention and Treatment of Opportunistic Infections in Adults and Adolescents with HIV

Treatment of Oropharyngeal Candidiasis: Initial Episodes

Pre ferr ed The rap y (Dur ati on: 7-1 4 D ays)	<ul style="list-style-type: none">
Alt ern ati ve The rap y	<ul style="list-style-type: none">

	<ul style="list-style-type: none">		
Rating of Recommendations: A = Strong; B = Moderate; C = Optional			
Rating of Evidence: I			

= Data from randomized controlled trials; II = Data from well-designed non-randomized trials, observational cohort studies with long-term clinical outcomes, relative bioavailability/bioequivalence

e studies, or regimen comparisons from randomized switch studies; III = Expert opinion

Source:



- Panel on Opportunistic Infections in Adults and Adolescents with HIV. Guidelines for the prevention and treatment of opportunistic infections in adults and adolescents with HIV: recommendations from the Centers for Disease Control and Prevention, the National Institutes of Health, and the HIV Medicine Association of the Infectious Diseases Society of America. Candidiasis (mucocutaneous). September 16, 2024. [[HIV.gov](https://www.hiv.gov)]
- **Preferred Therapy:** Oral fluconazole is not recommended for pregnant women, especially women in the first trimester of pregnancy. Topical therapies include miconazole buccal tablets, clotrimazole lozenges (troche), miconazole mucoadhesive buccal tablets, nystatin suspension, nystatin lozenges (pastille), and a topical gentian violet application; topical therapies reduce the risk of systemic drug exposure and adverse events, but they are not as effective, and thus all are considered alternative therapies.
- **Alternative Therapy:** Alternative systemic therapy consists of either itraconazole oral solution or posaconazole oral solution.

Fluconazole-Resistant Candidiasis

Refractory oropharyngeal candidiasis in persons with HIV and advanced immunosuppression emerged in response to the widespread and frequent use of fluconazole; in earlier years of the epidemic, it occurred in approximately 5% of persons with HIV.[16,17] Studies have identified multiple risk factors for the development of fluconazole-resistant candidiasis, including a greater number of fluconazole-treated episodes, longer median duration of fluconazole therapy, and advanced immunosuppression (especially a CD4 count of less than 50 cells/mm³).[18] In addition, the likelihood of fluconazole-resistant candidiasis depends on the

Candida species causing the infection: most *C. albicans* species are susceptible to fluconazole, whereas non-*albicans* species have variable resistance patterns to antifungal agents. A recently identified non-*albicans* species, *C. auris*, is remarkably resistant to all major antifungal drug classes and has shown a significant capacity to spread among health care facilities.[\[19,20,21\]](#) Although this organism has not been associated with oral infections in people with HIV, it could& presumably infect [\[22\]](#) the oral mucosa. Thus, oropharyngeal candidiasis that is resistant to multiple types of treatment should raise the possibility of *C. auris*, infection. For persons who have clinically refractory oropharyngeal candidiasis and/or azole-resistant candidiasis, expert consultation is advised.

Oral Hairy Leukoplakia

Background

Oral hairy leukoplakia (OHL) occurs in up to 15 to 20% of individuals with HIV, typically among those with moderate to advanced immune suppression.[23] As with other opportunistic infections, the prevalence of OHL has decreased with the advent of effective antiretroviral therapy. In most reports, Epstein-Barr virus (EBV) has been strongly associated with OHL, although the mechanism by which EBV infects the oral epithelium has not been fully elucidated.[24,25,26]

Clinical Manifestations

Individuals with OHL typically present with raised, white, corrugated lesions, most often on the lateral aspect of the tongue; less often, OHL can manifest with extensive oral mucosal involvement, including the buccal mucosa (Figure 6).[26,27,28,29] The OHL lesions are adherent and not removed when scraping the lesion with a tongue blade. This feature serves to distinguish OHL from oral candidiasis since pseudomembranous candidiasis lesions are typically easily removed by scraping with a tongue depressor. Typically, OHL does not cause symptoms, but some individuals may complain of glossodynia.

Diagnosis

The diagnosis of OHL is typically made based on clinical findings. Histologic confirmation of the diagnosis is not usually required, but if a biopsy is performed, characteristic histopathologic findings include cellular nuclear changes (acanthosis, Cowdry type A inclusions, ground glass, and nuclear beading), absence of an inflammatory infiltrate, regions of ballooning cells, and epithelial hyperplasia.[26,30] Additional confirmation can be made by demonstrating replicating EBV in the histologic sample, but this is rarely done.

Treatment

In most persons with HIV, antiretroviral therapy will cause OHL lesions to resolve. Thus, other than using antiretroviral therapy, no specific therapy for OHL is generally required. If an individual requests immediate treatment due to symptoms or cosmetic reasons, reports have described benefits from valacyclovir and from topical therapy (podophyllin resin combined with acyclovir cream).[31,32]

Aphthous Stomatitis

Background

The prevalence of aphthous stomatitis in persons with HIV has declined to about 9%, nearing that of the general population.[33] The cause of these ulcers remains unclear but may represent an overstimulation of tumor necrosis factor, perhaps triggered by an unidentified pathogen. Other possible etiologies include trauma and stress, systemic disease, nutritional deficiencies, and food allergies.[34] When compared with aphthous lesions in immunocompetent individuals, patients with HIV typically have oral ulcers that are more extensive, more frequent in occurrence, and slower to heal.[35]

Clinical Manifestations

Aphthous stomatitis manifests as round to oval lesions with a raised red halo on movable, nonkeratinized mucosal surfaces in the mouth, including the lip, buccal mucosa, and tongue, often with a yellow-gray pseudomembranous covering (Figure 7).[36,37] Aphthous stomatitis lesions are characterized as minor, major, or herpetiform based on the size and number of lesions.[36] Minor lesions are 0.2 to 0.5 cm in diameter and typically persist for 7 to 10 days; major lesions are greater than 0.5 cm in diameter and often persist for weeks.[34,36,38] Herpetiform lesions manifest as a crop of lesions, with each lesion smaller than 1 to 2 mm in diameter, but these small lesions can coalesce into large lesions. Aphthous stomatitis lesions often cause intense pain, particularly when patients eat or drink spicy, salty or acidic foods or beverages.[34,38] For individuals who have repeated episodes, the disorder is referred to as recurrent aphthous stomatitis.

Diagnosis

No causative agent has been identified for aphthous stomatitis. The diagnosis of aphthous stomatitis is based on clinical presentation and exclusion of other possible causes, including herpes simplex virus (HSV), syphilis, neoplasm, or a drug reaction.

Treatment

Treatment of aphthous lesions in persons with HIV typically consists of a combination of symptomatic relief and anti-inflammatory medications. Topical anesthetics are helpful for pain control of all lesions. Minor lesions can be treated with a mucosal binding agent and topical corticosteroid, ideally combined in a dental paste preparation. In contrast, more severe lesions may require systemic or intralesional corticosteroids, or the immunomodulator, thalidomide.[35,39] Antiretroviral therapy is an important component in treating aphthous stomatitis.[38] Objective evidence shows most efficacy from corticosteroids and antimicrobials used topically, although a meta-analysis concluded there was insufficient evidence to support any single treatment.[40,41] In general, treatment of aphthous ulcers should focus on acute ulcer control and preventing recurrences, and treatment algorithms should follow a stepwise progression, starting with topical preparations and proceeding if necessary to first- and second-line systemic therapies.[35] The following summarizes several key aspects of treatment options.

- **Chlorhexidine:** Bioadherent oral rinse gel and chlorhexidine gluconate mouth rinses reduce the severity and pain of ulceration but not the frequency.
- **Anti-Inflammatory Agents:** In patients with mild to moderate aphthous lesions, anti-inflammatory agents, such as benzydamine hydrochloride mouthwash and topical amlexanox paste, may provide symptomatic benefit with transient pain relief.
- **Topical Corticosteroids:** The use of topical corticosteroids remains the mainstay of treatment, with a recent randomized placebo-controlled trial showing a statistically significant improvement in healing ratio in patients treated with dexamethasone ointment compared with placebo.[42] A spectrum of different topical corticosteroids can be used. Although package inserts for most topical steroids have a warning “not for internal use,” extensive experience over several decades has shown efficacy and

safety with the use of topical steroids for aphthous stomatitis. Topical corticosteroids usually reduce painful symptoms, but they do not impact the rate of ulcer recurrence. The patient should avoid eating or drinking anything for at least 30 minutes after the topical agent has been applied. The commonly used preparations are as follows:

- Fluocinonide 0.05% ointment rubbed into the affected area three times daily, *or*
 - Hydrocortisone mucoadhesive buccal tablets 2.5 mg used 4 times daily, *or*
 - Triamcinolone acetonide 0.1 dental paste applied to ulcer 4 times daily, *or*
 - Betamethasone sodium phosphate as a 0.5 mg tablet dissolved in 15 mL of water to make a mouth rinse, used 4 times daily for 4 minutes each time.
- **Safety of Topical Corticosteroids:** Hydrocortisone and triamcinolone topical preparations are popular because neither causes significant adrenal suppression, but ulcers typically recur unless effective antiretroviral therapy is also used. Betamethasone, fluocinonide, fluocinolone, fluticasone, and clobetasol are more potent and more effective than hydrocortisone and triamcinolone, but they carry an increased risk for adrenocortical suppression and a predisposition to candidiasis. All corticosteroids, even when given in non-oral formulation, have the potential to induce serious complications, such as Cushing's syndrome in persons with HIV taking ritonavir or cobicistat, as well as with some protease inhibitors.[\[43\]](#) Corticosteroids should be used with caution in these patients.
 - **Tetracyclines:** Topical tetracyclines may reduce the severity of ulceration, but they do not alter the recurrence rate. A doxycycline capsule of 100 mg in 10 mL of water administered as a mouth rinse for 3 minutes or tetracycline 500 mg plus nicotinamide 500 mg administered 4 times daily may provide relief and reduce ulcer duration. Avoid tetracyclines in children younger than 12 years who might ingest them and develop tooth staining.
 - **Thalidomide:** In patients with severe aphthous lesions, the medication thalidomide (200 mg per day for 4 weeks) has been shown to significantly improve healing and resolution. The use of thalidomide is hampered by its pregnancy category X classification and the requirement that clinicians need to enroll in a special thalidomide distribution program.

Herpes Simplex Virus

Background

Infections with herpes simplex virus (HSV) occur frequently in persons with HIV and more than 95% of individuals with HIV test seropositive for either HSV-1 or HSV-2.[\[44\]](#) Infection with HSV is characterized by periodic reactivation, during which shedding from mucosal surfaces is increased. Shedding of HSV persists despite highly active antiretroviral therapy among persons coinfecting with HIV and HSV.[\[45\]](#)

Clinical Manifestations

Oral herpes is usually caused by infection with HSV-1, but HSV-2 can also cause oral lesions. In people with HIV, oral herpes most often manifests as lesions on the outer mouth region, inner lips, tongue, or palate; individuals with their first episode of oral HSV may have more severe and extensive lesions ([Figure 8](#)). From a clinical perspective, oral infection with HSV-1 is indistinguishable from HSV-2. Persons with recurrent oral herpes classically experience a sensory prodrome, followed by the evolution of the lesion(s) from papule to vesicle to crusting stage on the lips and ulcers in the intraoral tissues.[\[44\]](#) If untreated, symptoms persist 5 to 10 days; antiviral therapy initiated at onset of the prodrome can shorten the symptomatic period or even abort the outbreak. Patients with HIV infection and a CD4 count of less than 100 cells/mm³ may have deep, extensive, and non-healing ulcers and are more likely to develop acyclovir-resistant HSV.[\[44,46\]](#)

Diagnosis

The clinical diagnosis of oral HSV can be challenging since HSV lesions can mimic many other infections, particularly when present in the ulcerated form. Therefore, establishing the diagnosis via laboratory testing is recommended.[\[44\]](#) Performing HSV DNA PCR testing is the most sensitive method for diagnosis, but viral culture and antigen detection are also frequently used for diagnostic purposes.[\[44\]](#) Serotype-specific HSV serologic testing may have a diagnostic role in primary infection (by showing seroconversion) but has no role in recurrent episodes.

Treatment

The recommended therapy for oral HSV lesions in persons with HIV consists of a 5- to 10-day course of oral valacyclovir 1 g twice daily, famciclovir 500 mg twice daily, or acyclovir 400 mg three times daily; intravenous acyclovir 5 mg/kg every 8 hours may be required for severe mucocutaneous disease ([Table 2](#)).[\[44\]](#) Long-term suppressive therapy reduces the number of recurrences of mucocutaneous HSV disease in persons with HIV. For individuals who have severe outbreaks or who want to minimize the frequency of recurrences, suppressive therapy can be initiated using valacyclovir 500 mg twice daily, famciclovir 500 mg twice daily, or acyclovir 400 mg twice daily.[\[44\]](#)

Kaposi's Sarcoma

Background

Kaposi's sarcoma is a vascular tumor caused by human herpes virus-8 (HHV-8), also known as KS-associated herpes virus (KSHV). Kaposi's sarcoma remains the most frequent HIV-associated oral malignancy, with a peak incidence occurring among men who have sex with men aged 25 to 59 years. In the current era of the HIV epidemic, as patients are living longer, the overall frequency of non-AIDS malignancies has increased, while rates of Kaposi's sarcoma have dramatically decreased.[\[47\]](#) Research suggests a relationship between immunodeficiency and malignancy, possibly through a mechanism of decreased immune surveillance.

Clinical Manifestations

When Kaposi's sarcoma involves the mouth, lesions are usually located on the gingiva or hard palate and can appear macular, nodular, raised, or ulcerated, with color ranging from red to purple ([Figure 9](#)).[\[1\]](#) The gingival lesions caused by Kaposi's sarcoma can appear similar to drug-related gingival hyperplasia, bacillary angiomatosis, hemangiomas, and certain malignancies, such as leukemia and non-Hodgkin's lymphoma, that may have gingival lesions as part of the initial presentation. Individuals with Kaposi's sarcoma frequently present with both intraoral and cutaneous lesions. In addition, persons with HIV who have intraoral Kaposi's sarcoma may also have lesions in the lower gastrointestinal tract.

Diagnosis

The diagnosis of oral Kaposi's sarcoma is usually suspected based on characteristic clinical findings. When evaluating an individual with HIV who has gingival lesions, the differential diagnosis can include drug-related gingival hyperplasia, bacillary angiomatosis, hemangiomas, and malignancies, such as leukemia and non-Hodgkin's lymphoma, since these disorders may cause gingival masses as part of the initial presentation. Therefore, a definitive diagnosis requires a biopsy of the oral lesion(s). Classic findings on pathology include neovascularization with aberrant proliferation of small vessels, atypical spindle-shaped cells with leukocytic infiltration, and hemosiderin-laden macrophages.

Treatment

Combination antiretroviral therapy is recommended for all persons with HIV-related Kaposi's sarcoma, and these lesions often regress with antiretroviral therapy alone.[\[48\]](#) When lesions do not resolve or the initial manifestations are severe, additional treatment may involve a combination of radiation, intralesional chemotherapy, topical therapy, or surgical excision.[\[49\]](#) Systemic cytotoxic chemotherapy is generally reserved for treating disseminated disease beyond the oral cavity. The liposomal anthracyclines—either liposomal doxorubicin or liposomal daunorubicin—are typically used when systemic cytotoxic chemotherapy is required.[\[50\]](#)

Human Papillomavirus-Related Oral Warts and Oral Cancer

Background

Of the more than 200 human papillomavirus (HPV) genotypes identified, a small number of subtypes cause most clinical disease, particularly HPV-6 and 11 (responsible for most oral and anogenital warts) and HPV-16 and 18 (considered high-risk viruses connected to premalignant and malignant lesions in the anal, vaginal, cervical and oral mucosa). Transmission of HPV occurs through direct skin or mucosal contact.^[51] In one study of discordant couples, a per-person transmission probability of 20% was shown during a 6-month period with a trend towards higher rates of HPV-16.^[52] Despite the current widespread use of effective antiretroviral therapies for persons with HIV, HPV-associated oral lesions have increased in recent years.^[53] In a meta-analysis of publications focusing on men having sex with men (MSM), the pooled prevalence of HPV in the oral cavity was higher in persons with HIV (28.9%) than those without HIV (17.1%).^[54] Parallel with these findings, a recent analysis of pooled data from 17 prospective studies in the North American AIDS Cohort Collaboration on Research and Design (NA-ACCORD) between 1996 and 2009 found that HPV-related and HPV-unrelated head and neck squamous cell cancers are both elevated in individuals with HIV.^[55] It is not entirely clear if the increase in the incidence of head and neck cancers among individuals with HIV is related to immune dysregulation, long-term use of antiretroviral therapies, behavioral factors such as tobacco and alcohol use, other infectious agents, or a combination of all these factors.^[51,56] Although there are no clinical trial data to demonstrate the efficacy of HPV vaccination in reducing the rates of HPV-related oropharyngeal cancers, increasing evidence points to the positive impact of HPV vaccination in reducing the prevalence of high-risk HPV in the oral cavity that could be projected into a potential reduction in the incidence of oropharyngeal cancer.^[57,58,59,60]

Clinical Manifestations

Oral HPV-Associated Lesions

Oral HPV-related non-cancerous lesions can manifest as single or multiple cauliflower-like warts that are spiked (squamous papilloma), broad-based (condyloma), or raised on a flat surface (focal epithelial hyperplasia) (Figure 10).^[1] Lesions may be white, red, or the color of normal mucosa. Oral warts often arise at the base of the tongue, gums, or tonsillar region (where they can easily be missed on routine oral examination). Moreover, it is sometimes difficult to differentiate benign lesions from certain malignant lesions, such as verrucous carcinoma, based on visual examination alone.

Oral HPV-Associated Dysplasia

Oral HPV-associated dysplasia has a clinical presentation that ranges from white to red (or mixed in color) or ulcerated with a flat or nodular appearance; as lesions advance to squamous cell carcinoma, they exhibit poor margins with varying degrees of vascularity (Figure 11). Lesions are often nontender and indurated on palpation. The patient should be carefully examined for evidence of spread to the surrounding tissues and the regional lymph nodes.

Diagnosis

The diagnosis of HPV-related oral disease is often made on the basis of a typical clinical appearance; if needed, a biopsy can confirm the diagnosis. Due to the increased frequency of oral malignant lesions and in immunocompromised patients, clinicians should maintain a low threshold for performing a biopsy on any suspicious lesion. It should be emphasized that many of these lesions, including the malignant ones, may not be readily visible on a cursory oral examination and may remain asymptomatic until they are at later stages. Therefore, a careful clinical examination may be the best detection tool for many of the early dysplastic changes in the oral tissues.

Treatment

No clear standard for the treatment of HPV-related oral lesions has been established, but approaches to therapy may involve surgery, laser therapy, or cryotherapy. The specific treatment chosen is usually based on the location of the lesions, extent of disease, and whether the lesions are malignant. It should also be noted that preventive HPV vaccination among people with HIV should be promoted to reduce the malignancy burden in this population.

Mpox

Background

Monkeypox virus is a DNA orthopoxvirus that causes a clinical illness that is referred to as mpox. The monkeypox virus is in the same genus as variola virus (the cause of smallpox) and vaccinia virus (the virus used in the smallpox and mpox vaccines).[\[61,62,63\]](#) The mpox clinical illness typically includes involvement of the skin and mucous membranes, often resembling a milder form of smallpox.[\[64,65,66\]](#) Transmission of monkeypox virus can occur by contact with skin and mucous membranes and may occur via respiratory droplets.[\[66\]](#) Among cases involving the 2022 circulating monkeypox virus (Clade IIb) in the United States, more than 90% involved men who have sex with men, and approximately 40% of all cases involved people with HIV.[\[67,68\]](#)

Clinical Manifestations

Persons with mpox typically have an initial viral prodrome of fever, chills, and myalgias, followed by skin lesions consisting of macules, papules, vesicles, ulcerations, pustules, and crusts. The skin manifestations can occur anywhere on the body and often occur as penile, vulvar, perianal, and rectal lesions.[\[66,69,70\]](#) Oral involvement in people with mpox is a common manifestation of pox, and it can represent an early manifestation of the disease.[\[71,72,73\]](#) At times, oral mpox lesions are preceded by lesions in the perioral tissues. Any part of the mouth can be involved, and lesions may extend into the pharynx ([Figure 12](#)).[\[71,73\]](#) The lesions can be vesicular or ulcerated, and the number can correlate with the severity of the disease. In some instances, mucous membrane involvement is severe. Most lesions generate significant pain, and symptoms can be severe enough to lead to dysphagia. Occasional dissemination to other organs, including the eyes, lungs, heart, and central nervous system, can occur, but this has been uncommon in recent cases in the United States.[\[68,74\]](#)

Diagnosis

The recommended diagnostic test is a PCR test on material obtained directly from one or more lesions.[\[63,75\]](#) Specimens should be obtained by rubbing the swab on the lesion, with more vigorous rubbing needed if the lesion is not actively draining. Material should be sent dry and not in transport media.

Treatment

There is no FDA-approved treatment for mpox. In the United States, tecovirimat has been the primary medication used to treat mpox; this medication is FDA-approved for the treatment of smallpox, but when treating mpox it can be obtained through trials and via expanded access from the CDC.[\[76,77,78\]](#) Individuals with mpox who may be candidates for tecovirimat include those with severe disease, including any manifestation, such as severe pain, that requires hospitalization. Treatment with tecovirimat is often considered in persons with HIV, especially individuals with more advanced immunosuppression.[\[79\]](#) Tecovirimat is available in oral and intravenous formulations. For adults, the recommended oral dose is a 14-day course of 600 mg twice daily taken with a high-fat meal, which may prove challenging in persons with severe oral disease. Other mpox treatments that have been used include brincidofovir, cidofovir, and vaccinia immune globulin.[\[77,80\]](#)

Summary Points

- Individuals with HIV who are receiving antiretroviral therapy are at risk of xerostomia and dental caries and benefit from routine dental examination and preventive care.
- Periodontal disease can complicate the management of HIV, and routine dental care and hygiene are essential components of good oral health.
- Oral candidiasis remains a common opportunistic infection among individuals with HIV, and fluconazole-resistant candidiasis can complicate management, especially among individuals with advanced immunosuppression who receive repeated or prolonged courses of fluconazole.
- Oral candidiasis is generally a clinical diagnosis, and first-line therapy includes either oral fluconazole or topical azole therapy. Primary prophylaxis and chronic suppressive therapy are discouraged due to cost, low attributable morbidity, efficacy of acute therapy, and risk of promoting further drug resistance.
- Oral hairy leukoplakia (OHL) is strongly linked with Epstein-Barr virus and generally causes asymptomatic hyperkeratotic lesions on oral mucosal surfaces. Treatment of underlying HIV with effective antiretroviral therapy usually leads to resolution of OHL lesions.
- Antiretroviral therapy is the most important component for the treatment of recurrent aphthous stomatitis.
- Oral herpes is usually caused by HSV-1, but HSV-2 can also cause oral lesions. Treatment consists of acyclovir, valacyclovir, or famciclovir.
- Although the incidence of Kaposi's sarcoma has decreased significantly following the widespread use of antiretroviral therapy, it remains the most frequent HIV-associated oral malignancy and may regress with antiretroviral treatment alone.
- Oral HPV infection is very common among individuals with HIV; infection with HPV can cause both benign and malignant oral lesions.
- Mpox can cause painful oral lesions that may resemble herpes simplex and aphthous stomatitis. Tecovirimat is the preferred treatment for mpox.

Citations

1. Reznik DA. Oral manifestations of HIV disease. Top HIV Med. 2005 Dec-2006;13:143-8.
[PubMed Abstract] -
2. Ryder MI, Nittayananta W, Coogan M, Greenspan D, Greenspan JS. Periodontal disease in HIV/AIDS. Periodontol 2000. 2012;60:78-97.
[PubMed Abstract] -
3. Burger-Calderon R, Smith JS, Ramsey KJ, Webster-Cyriaque J. The Association between the History of HIV Diagnosis and Oral Health. J Dent Res. 2016;95:1366-1374.
[PubMed Abstract] -
4. Coulter ID, Heslin KC, Marcus M, et al. Associations of self-reported oral health with physical and mental health in a nationally representative sample of HIV persons receiving medical care. Qual Life Res. 2002;11:57-70.
[PubMed Abstract] -
5. Herrera D, Sanz M, Shapira L, et al. Association between periodontal diseases and cardiovascular diseases, diabetes and respiratory diseases: Consensus report of the Joint Workshop by the European Federation of Periodontology (EFP) and the European arm of the World Organization of Family Doctors (WONCA Europe). J Clin Periodontol. 2023;50:819-41.
[PubMed Abstract] -
6. Feller L, Lemmer J. Necrotizing periodontal diseases in HIV-seropositive subjects: pathogenic mechanisms. J Int Acad Periodontol. 2008;10:10-5.
[PubMed Abstract] -
7. Lamster IB, Grbic JT, Bucklan RS, Mitchell-Lewis D, Reynolds HS, Zambon JJ. Epidemiology and diagnosis of HIV-associated periodontal diseases. Oral Dis. 1997;3 Suppl 1:S141-8.
[PubMed Abstract] -
8. Mataftsi M, Skoura L, Sakellari D. HIV infection and periodontal diseases: an overview of the post-HAART era. Oral Dis. 2011;17:13-25.
[PubMed Abstract] -
9. Souza AJ, Gomes-Filho IS, Silva CALD, et al. Factors associated with dental caries, periodontitis and intra-oral lesions in individuals with HIV / AIDS. AIDS Care. 2018;30:578-85.
[PubMed Abstract] -
10. Meer S. Human immunodeficiency virus and salivary gland pathology: an update. Oral Surg Oral Med Oral Pathol Oral Radiol. 2019;128:52-9.
[PubMed Abstract] -
11. Younai FS, Marcus M, Freed JR, et al. Self-reported oral dryness and HIV disease in a national sample of patients receiving medical care. Oral Surg Oral Med Oral Pathol Oral Radiol Endod. 2001;92:629-36.
[PubMed Abstract] -
12. Jeffers L, Webster-Cyriaque JY. Viruses and salivary gland disease (SGD): lessons from HIV SGD. Adv Dent Res. 2011;23:79-83.
[PubMed Abstract] -
13. Bonacini M, Young T, Laine L. The causes of esophageal symptoms in human immunodeficiency virus

infection. A prospective study of 110 patients. Arch Intern Med. 1991;151:1567-72.

[\[PubMed Abstract\]](#) -

14. Klein RS, Harris CA, Small CB, Moll B, Lesser M, Friedland GH. Oral candidiasis in high-risk patients as the initial manifestation of the acquired immunodeficiency syndrome. N Engl J Med. 1984;311:354-8.
[\[PubMed Abstract\]](#) -
15. Thompson GR 3rd, Patel PK, Kirkpatrick WR, et al. Oropharyngeal candidiasis in the era of antiretroviral therapy. Oral Surg Oral Med Oral Pathol Oral Radiol Endod. 2010;109:488-95.
[\[PubMed Abstract\]](#) -
16. Panel on Opportunistic Infections in Adults and Adolescents with HIV. Guidelines for the prevention and treatment of opportunistic infections in adults and adolescents with HIV: recommendations from the Centers for Disease Control and Prevention, the National Institutes of Health, and the HIV Medicine Association of the Infectious Diseases Society of America. Candidiasis (mucocutaneous). September 16, 2024.
[\[HIV.gov\]](#) -
17. Rex JH, Rinaldi MG, Pfaller MA. Resistance of *Candida* species to fluconazole. Antimicrob Agents Chemother. 1995;39:1-8.
[\[PubMed Abstract\]](#) -
18. Maenza JR, Keruly JC, Moore RD, Chaisson RE, Gallant JE. Risk factors for fluconazole-resistant candidiasis in HIV-infected patients. J Infect Dis 1996;173:219-25.
[\[PubMed Abstract\]](#) -
19. Ben-Ami R, Berman J, Novikov A, et al. Multidrug-Resistant *Candida haemulonii* and *C. auris*, Tel Aviv, Israel. Emerg Infect Dis. 2017;23:195-203.
[\[PubMed Abstract\]](#) -
20. Chowdhary A, Sharma C, Duggal S, et al. New clonal strain of *Candida auris*, Delhi, India. Emerg Infect Dis. 2013;19:1670-3.
[\[PubMed Abstract\]](#) -
21. Satoh K, Makimura K, Hasumi Y, Nishiyama Y, Uchida K, Yamaguchi H. *Candida auris* sp. nov., a novel ascomycetous yeast isolated from the external ear canal of an inpatient in a Japanese hospital. Microbiol Immunol. 2009;53:41-4.
[\[PubMed Abstract\]](#) -
22. Pathirana RU, Friedman J, Norris HL, et al. Fluconazole-Resistant *Candida auris* Is Susceptible to Salivary Histatin 5 Killing and to Intrinsic Host Defenses. Antimicrob Agents Chemother. 2018;62:e01872-17.
[\[PubMed Abstract\]](#) -
23. Tappuni AR. The global changing pattern of the oral manifestations of HIV. Oral Dis. 2020;26 Suppl 1:22-27.
[\[PubMed Abstract\]](#) -
24. Mabruk MJ, Antonio M, Flint SR, et al. A simple and rapid technique for the detection of Epstein-Barr virus DNA in HIV-associated oral hairy leukoplakia biopsies. J Oral Pathol Med. 2000;29:118-22.
[\[PubMed Abstract\]](#) -
25. Tugizov S, Herrera R, Veluppillai P, Greenspan J, Greenspan D, Palefsky JM. Epstein-Barr virus (EBV)-infected monocytes facilitate dissemination of EBV within the oral mucosal epithelium. J Virol.

2007;81:5484-96.

[\[PubMed Abstract\]](#) -

26. Triantos D, Porter SR, Scully C, Teo CG. Oral hairy leukoplakia: clinicopathologic features, pathogenesis, diagnosis, and clinical significance. Clin Infect Dis. 1997;25:1392-6.
[\[PubMed Abstract\]](#) -
27. Ficarra G, Gaglioti D, Di Pietro M, Adler-Storthz K. Oral hairy leukoplakia: clinical aspects, histologic morphology and differential diagnosis. Head Neck. 1991;13:514-21.
[\[PubMed Abstract\]](#) -
28. Ficarra G, Romagnoli P, Piluso S, Milo D, Adler-Storthz K. Hairy leukoplakia with involvement of the buccal mucosa. J Am Acad Dermatol. 1992;27:855-8.
[\[PubMed Abstract\]](#) -
29. Kabani S, Greenspan D, deSouza Y, Greenspan JS, Cataldo E. Oral hairy leukoplakia with extensive oral mucosal involvement. Report of two cases. Oral Surg Oral Med Oral Pathol. 1989;67:411-5
[\[PubMed Abstract\]](#) -
30. Dias EP, Rocha ML, Silva Junior A, et al. Oral hairy leukoplakia. Histopathologic and cytopathologic features of a subclinical phase. Am J Clin Pathol. 2000;114:395-401.
[\[PubMed Abstract\]](#) -
31. Moura MD, Haddad JP, Senna MI, Ferreira E, Ferreira E, Mesquita RA. A new topical treatment protocol for oral hairy leukoplakia. Oral Surg Oral Med Oral Pathol Oral Radiol Endod. 2010;110:611-7.
[\[PubMed Abstract\]](#) -
32. Walling DM, Flaitz CM, Nichols CM. Epstein-Barr virus replication in oral hairy leukoplakia: response, persistence, and resistance to treatment with valacyclovir. J Infect Dis. 2003;188:883-90.
[\[PubMed Abstract\]](#) -
33. Smith MH, Mintline M. Acute Immune-Mediated Lesions of the Oral Cavity. Oral Maxillofac Surg Clin North Am. 2023;35:247-59.
[\[PubMed Abstract\]](#) -
34. Barrons RW. Treatment strategies for recurrent oral aphthous ulcers. Am J Health Syst Pharm. 2001;58:41-50; quiz 51-3.
[\[PubMed Abstract\]](#) -
35. Kerr AR, Ship JA. Management strategies for HIV-associated aphthous stomatitis. Am J Clin Dermatol. 2003;4:669-80.
[\[PubMed Abstract\]](#) -
36. Shiboski CH, Patton LL, Webster-Cyriaque JY, et al. The Oral HIV/AIDS Research Alliance: updated case definitions of oral disease endpoints. J Oral Pathol Med. 2009;38:481-8.
[\[PubMed Abstract\]](#) -
37. Greenspan D, Greenspan JS. HIV-related oral disease. Lancet. 1996;348:729-33.
[\[PubMed Abstract\]](#) -
38. Alegre M, Dalmau J, Domingo P, Roé E, Alomar A. Successful treatment of major oral aphthous ulcers in HIV-1 infection after highly active antiretroviral therapy. Int J Infect Dis. 2007;11:278-9.
[\[PubMed Abstract\]](#) -

39. Jacobson JM, Greenspan JS, Spritzler J, et al. Thalidomide for the treatment of oral aphthous ulcers in patients with human immunodeficiency virus infection. National Institute of Allergy and Infectious Diseases AIDS Clinical Trials Group. N Engl J Med. 1997;336:1487-93.
[[PubMed Abstract](#)] -
40. Baccaglini L, Lalla RV, Bruce AJ, et al. Urban legends: recurrent aphthous stomatitis. Oral Dis. 2011;17:755-70.
[[PubMed Abstract](#)] -
41. Brocklehurst P, Tickle M, Glenny AM, et al. Systemic interventions for recurrent aphthous stomatitis (mouth ulcers). Cochrane Database Syst Rev. 2012;9:CD005411.
[[PubMed Abstract](#)] -
42. Liu C, Zhou Z, Liu G, et al. Efficacy and safety of dexamethasone ointment on recurrent aphthous ulceration. Am J Med. 2012;125:292-301.
[[PubMed Abstract](#)] -
43. John G, Ollo D, Meyer P, Samer CF, Calmy A. Pulmonary embolism and iatrogenic Cushing's syndrome after co-administration of injected-triamcinolone and ritonavir. AIDS. 2013;27:2827-8.
[[PubMed Abstract](#)] -
44. Panel on Opportunistic Infections in Adults and Adolescents with HIV. Guidelines for the prevention and treatment of opportunistic infections in adults and adolescents with HIV: recommendations from the Centers for Disease Control and Prevention, the National Institutes of Health, and the HIV Medicine Association of the Infectious Diseases Society of America. Herpes simplex virus. Last updated: May 26, 2020.
[[HIV.gov](#)] -
45. Tan DH, Raboud JM, Kaul R, Walmsley SL. Antiretroviral therapy is not associated with reduced herpes simplex virus shedding in HIV coinfecting adults: an observational cohort study. BMJ Open. 2014;4:e004210.
[[PubMed Abstract](#)] -
46. Strick LB, Wald A, Celum C. Management of herpes simplex virus type 2 infection in HIV type 1-infected persons. Clin Infect Dis. 2006;43:347-56.
[[PubMed Abstract](#)] -
47. Silverberg MJ, Neuhaus J, Bower M, et al. Risk of cancers during interrupted antiretroviral therapy in the SMART study. AIDS. 2007;21:1957-63.
[[PubMed Abstract](#)] -
48. Sullivan SG, Hirsch HH, Franceschi S, et al. Kaposi sarcoma herpes virus antibody response and viremia following highly active antiretroviral therapy in the Swiss HIV Cohort study. AIDS. 2010;24:2245-52.
[[PubMed Abstract](#)] -
49. Di Lorenzo G, Konstantinopoulos PA, Pantanowitz L, Di Trollo R, De Placido S, Dezube BJ. Management of AIDS-related Kaposi's sarcoma. Lancet Oncol. 2007;8:167-76.
[[PubMed Abstract](#)] -
50. Cesarman E, Damania B, Krown SE, Martin J, Bower M, Whitby D. Kaposi sarcoma. Nat Rev Dis Primers. 2019;5:9.
[[PubMed Abstract](#)] -

51. Younai FS. Current Trends in the Incidence and Presentation of Oropharyngeal Cancer. J Calif Dent Assoc. 2016;44:93-100.
[[PubMed Abstract](#)] -
52. Burchell AN, Coutlée F, Tellier PP, Hanley J, Franco EL. Genital transmission of human papillomavirus in recently formed heterosexual couples. J Infect Dis. 2011;204:1723-9.
[[PubMed Abstract](#)] -
53. Mooij SH, Boot HJ, Speksnijder AG, et al. Oral human papillomavirus infection in HIV-negative and HIV-infected MSM. AIDS. 2013;27:2117-28.
[[PubMed Abstract](#)] -
54. Beachler DC, Sugar EA, Margolick JB, et al. Risk factors for acquisition and clearance of oral human papillomavirus infection among HIV-infected and HIV-uninfected adults. Am J Epidemiol. 2015;181:40-53.
[[PubMed Abstract](#)] -
55. Beachler DC, Abraham AG, Silverberg MJ, et al. Incidence and risk factors of HPV-related and HPV-unrelated Head and Neck Squamous Cell Carcinoma in HIV-infected individuals. Oral Oncol. 2014;pii: S1368-8375(14)00272-3.
[[PubMed Abstract](#)] -
56. Cameron JE, Hagensee M. HPV-Associated Oropharyngeal Cancer in the HIV/AIDS Patient. Cancer Treat Res. 2019;177:131-81.
[[PubMed Abstract](#)] -
57. Betz SJ. HPV-Related Papillary Lesions of the Oral Mucosa: A Review. Head Neck Pathol. 2019;13:80-90.
[[PubMed Abstract](#)] -
58. Chaturvedi AK, Graubard BI, Broutian T, et al. Effect of Prophylactic Human Papillomavirus (HPV) Vaccination on Oral HPV Infections Among Young Adults in the United States. J Clin Oncol. 2018;36:262-7.
[[PubMed Abstract](#)] -
59. Kaczmarczyk KH, Yusuf H. The impact of HPV vaccination on the prevention of oropharyngeal cancer: A scoping review. Community Dent Health. 2022;39:14-21.
[[PubMed Abstract](#)] -
60. Wilkin TJ, Chen H, Cespedes MS, et al. A Randomized, Placebo-Controlled Trial of the Quadrivalent Human Papillomavirus Vaccine in Human Immunodeficiency Virus-Infected Adults Aged 27 Years or Older: AIDS Clinical Trials Group Protocol A5298. Clin Infect Dis. 2018;67:1339-46.
[[PubMed Abstract](#)] -
61. Ulaeto D, Agafonov A, Burchfield J, et al. New nomenclature for mpox (monkeypox) and monkeypox virus clades. Lancet Infect Dis. 2023;23:273-5.
[[PubMed Abstract](#)] -
62. Lansiaux E, Jain N, Laivacuma S, Reinis A. The virology of human monkeypox virus (hMPXV): A brief overview. Virus Res. 2022 Dec;322:198932.
[[PubMed Abstract](#)] -
63. Mitjà O, Ogoina D, Titanji BK, et al. Monkeypox. Lancet. 2023;401:60-74.
[[PubMed Abstract](#)] -

64. Farrar JL, Lewis NM, Houck K, et al. Demographic and Clinical Characteristics of Mpox in Persons Who Had Previously Received 1 Dose of JYNNEOS Vaccine and in Unvaccinated Persons - 29 U.S. Jurisdictions, May 22-September 3, 2022. *MMWR Morb Mortal Wkly Rep.* 2022;71:1610-15.
[[PubMed Abstract](#)] -
65. Huhn GD, Bauer AM, Yorita K, et al. Clinical characteristics of human monkeypox, and risk factors for severe disease. *Clin Infect Dis.* 2005;41:1742-51.
[[PubMed Abstract](#)] -
66. Liu Q, Fu L, Wang B, et al. Clinical Characteristics of Human Mpox (Monkeypox) in 2022: A Systematic Review and Meta-Analysis. *Pathogens.* 2023;12:146.
[[PubMed Abstract](#)] -
67. Curran KG, Eberly K, Russell OO, et al. HIV and Sexually Transmitted Infections Among Persons with Monkeypox - Eight U.S. Jurisdictions, May 17-July 22, 2022. *MMWR Morb Mortal Wkly Rep.* 2022;71:1141-7.
[[CDC](#)] -
68. Philpott D, Hughes CM, Alroy KA, et al. Epidemiologic and Clinical Characteristics of Monkeypox Cases - United States, May 17-July 22, 2022. *MMWR Morb Mortal Wkly Rep.* 2022;71:1018-22.
[[PubMed Abstract](#)] -
69. Maldonado-Barrueco A, Sanz-González C, Gutiérrez-Arroyo A, et al. Sexually transmitted infections and clinical features in monkeypox (mpox) patients in Madrid, Spain. *Travel Med Infect Dis.* 2023;52:102544.
[[PubMed Abstract](#)] -
70. Mazzotta V, Scorzolini L, Falasca L, et al. Lymphofollicular lesions associated with monkeypox (Mpox) virus proctitis. *Int J Infect Dis.* 2023;130:48-51.
[[PubMed Abstract](#)] -
71. Sah R, Siddiq A, Reda A, et al. Oral manifestations of mpox: A common presentation? *J Am Dent Assoc.* 2023;154:279-82.
[[PubMed Abstract](#)] -
72. Gandhi P A, Patro SK, Sandeep M, et al. Oral manifestation of the monkeypox virus: a systematic review and meta-analysis. *EClinicalMedicine.* 2023;56:101817.
[[PubMed Abstract](#)] -
73. Shah J, Saak TM, Desai AN, et al. Otolaryngologic manifestations among MPOX patients: A systematic review and meta-analysis. *Am J Otolaryngol.* 2023;44:103991.
[[PubMed Abstract](#)] -
74. Rao AK, Schrodtt CA, Minhaj FS, et al. Interim Clinical Treatment Considerations for Severe Manifestations of Mpox - United States, February 2023. *MMWR Morb Mortal Wkly Rep.* 2023;72:232-43.
[[PubMed Abstract](#)] -
75. Mills MG, Juergens KB, Gov JP, et al. Evaluation and clinical validation of monkeypox (mpox) virus real-time PCR assays. *J Clin Virol.* 2023;159:105373.
[[PubMed Abstract](#)] -
76. Centers for Disease Control and Prevention (CDC). Tecovirimat (TPOXX) IND Information. Updated July

6, 2023.

[[CDC](#)] -

77. Grosenbach DW, Russo AT, Blum ED, Hruby DE. Emerging pharmacological strategies for treating and preventing mpox. *Expert Rev Clin Pharmacol*. 2023;16:843-54.
[[PubMed Abstract](#)] -
78. Sherwat A, Brooks JT, Birnkrant D, Kim P. Tecovirimat and the Treatment of Monkeypox - Past, Present, and Future Considerations. *N Engl J Med*. 2022;387:579-81.
[[PubMed Abstract](#)] -
79. Philpott DC, Bonacci RA, Weidle PJ, et al. Low CD4 Count or Being Out of Care Increases the Risk for Mpox Hospitalization Among People with HIV and Mpox. *Clin Infect Dis*. 2023 Aug 17. Online ahead of print.
[[PubMed Abstract](#)] -
80. Siegrist EA, Sassine J. Antivirals With Activity Against Mpox: A Clinically Oriented Review. *Clin Infect Dis*. 2023;76:155-64.
[[PubMed Abstract](#)] -

References

- Beeson A, Styczynski A, Hutson CL, et al. Mpox respiratory transmission: the state of the evidence. *Lancet Microbe*. 2023;4:e277-e283.
[[PubMed Abstract](#)] -
- Gillison ML, Broutian T, Pickard RK, et al. Prevalence of oral HPV infection in the United States, 2009-2010. *JAMA*. 2012;307:693-703.
[[PubMed Abstract](#)] -
- Greenspan D, Canchola AJ, MacPhail LA, Cheikh B, Greenspan JS. Effect of highly active antiretroviral therapy on frequency of oral warts. *Lancet*. 2001;357(9266):1411-2.
[[PubMed Abstract](#)] -
- Greseth MD, Traktman P. The life cycle of the vaccinia virus genome. *Annu Rev Virol*. 2022;9:239-59.
[[PubMed Abstract](#)] -
- Herrero R, Quint W, Hildesheim A, et al. Reduced prevalence of oral human papillomavirus (HPV) 4 years after bivalent HPV vaccination in a randomized clinical trial in Costa Rica. *PLoS One*. 2013;8:e68329.
[[PubMed Abstract](#)] -
- Husak R, Garbe C, Orfanos CE. Oral hairy leukoplakia in 71 HIV-seropositive patients: clinical symptoms, relation to immunologic status, and prognostic significance. *J Am Acad Dermatol*. 1996;35:928-34.
[[PubMed Abstract](#)] -
- Leng CY, Low HC, Chua LL, et al. Human papillomavirus 16 (HPV16) and HPV52 E6-specific immunity in HIV-infected adults on combination antiretroviral therapy. *HIV Med*. 2017;18:321-331.
[[PubMed Abstract](#)] -
- Lyman M, Forsberg K, Sexton DJ, et al. Worsening Spread of *Candida auris* in the United States, 2019 to 2021. *Ann Intern Med*. 2023;176:489-95.

[\[PubMed Abstract\]](#) -

- Sonawane K, Suk R, Chiao EY, et al. Oral Human Papillomavirus Infection: Differences in Prevalence Between Sexes and Concordance With Genital Human Papillomavirus Infection, NHANES 2011 to 2014. Ann Intern Med. 2017;167:714-24.

[\[PubMed Abstract\]](#) -

Figures

Figure 1 (Image Series) - Periodontal Disease in Persons with HIV (Image Series) - Figure 1 (Image Series) - Periodontal Disease in Persons with HIV
Image 1A: Linear Gingival Erythema

Photograph from Mark Nichols, DDS, Dental Director, South Central AETC

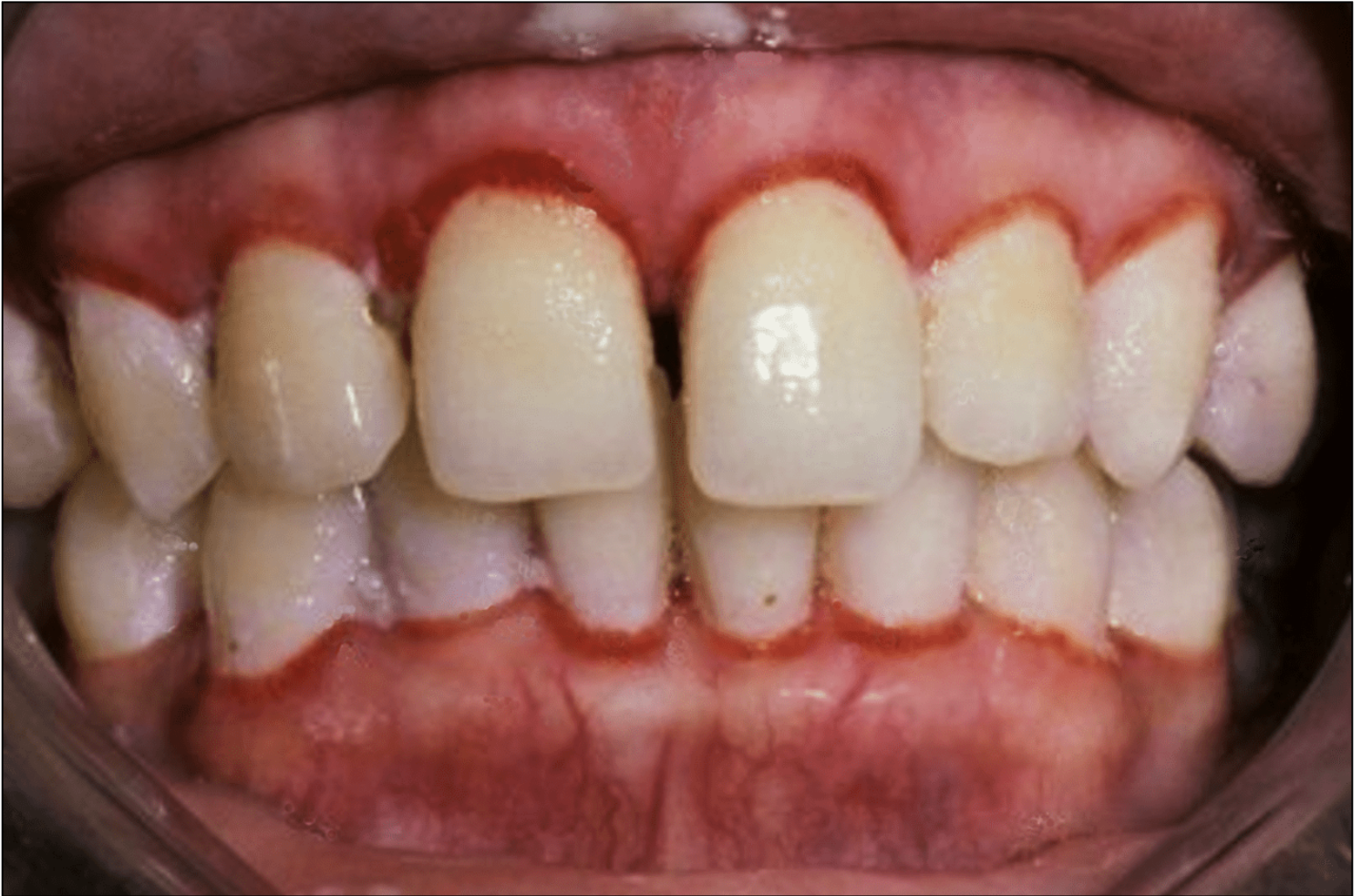

Figure 1 (Image Series) - Periodontal Disease in Persons with HIV
Image 1B: Necrotizing Ulcerative Gingivitis

Photograph from Mark Nichols, DDS, Dental Director, South Central AETC

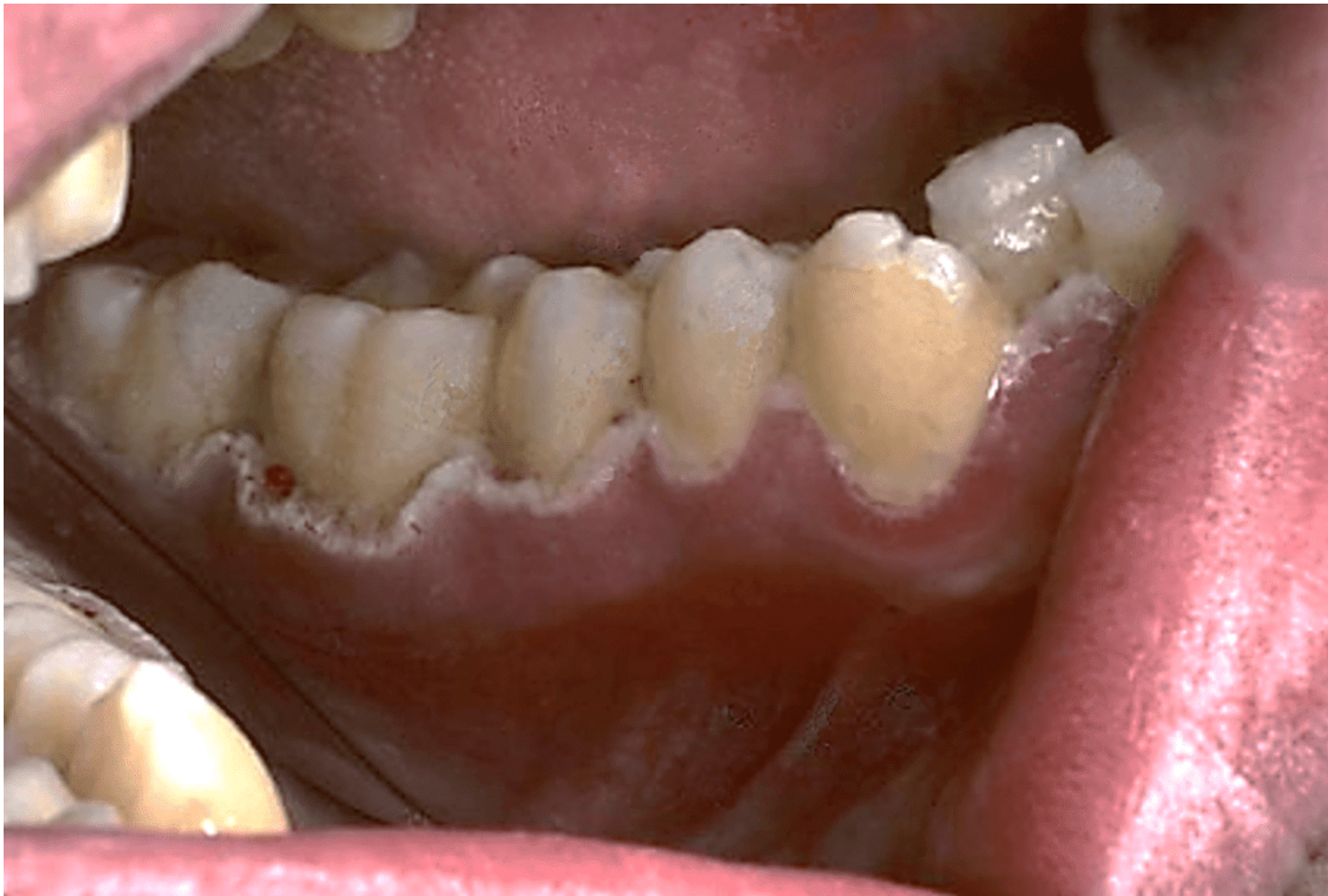

Figure 1 (Image Series) - Periodontal Disease in Persons with HIV
Image 1C: Necrotizing Ulcerative Periodontitis

PPhotograph from Mark Nichols, DDS, Dental Director, South Central AETC

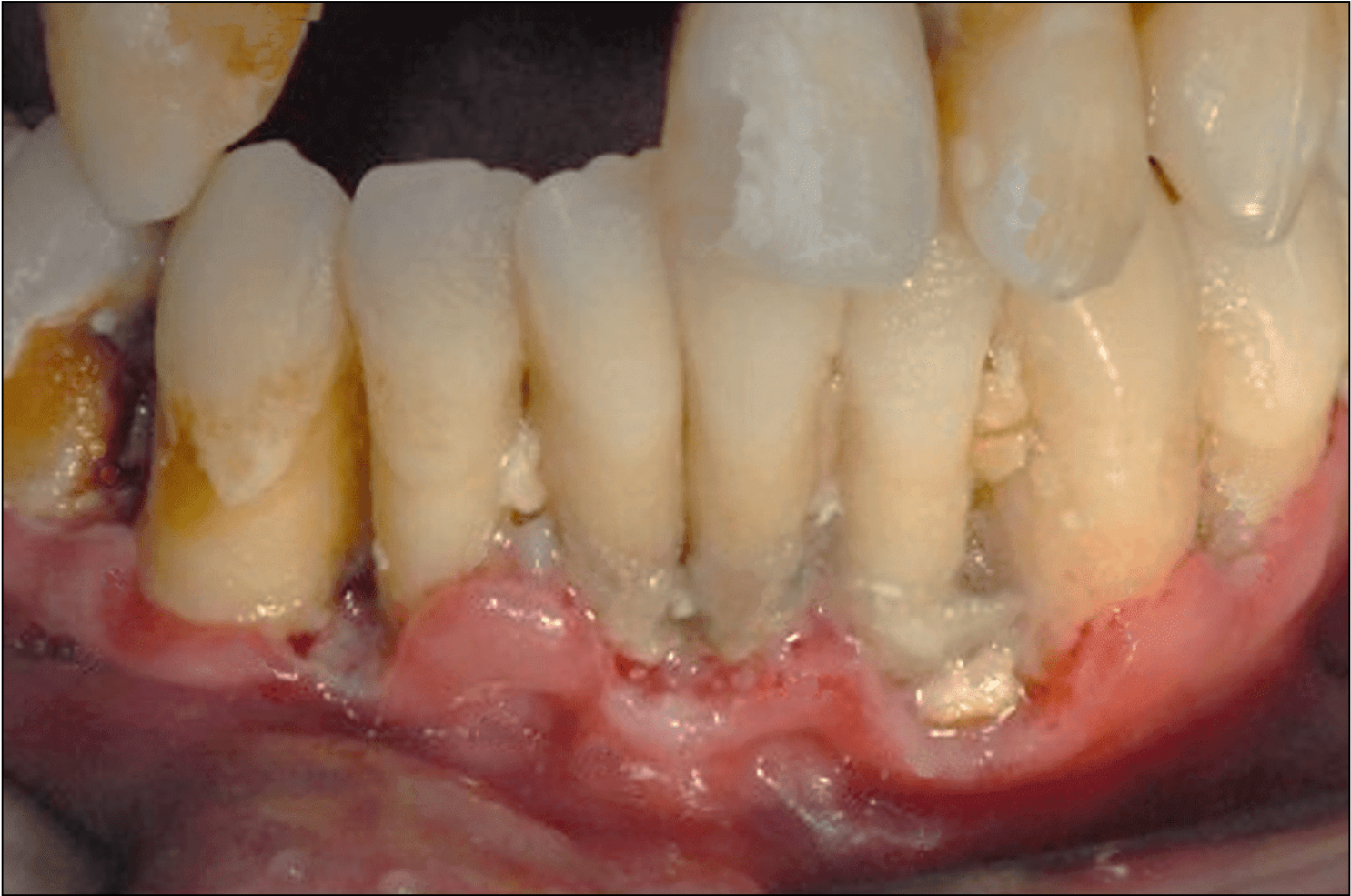

Figure 2 (Image Series) - Pseudomembranous Candidiasis (Image Series) - Figure 2 (Image Series) - Pseudomembranous Candidiasis

Image 2A: Pseudomembranous Candidiasis on Palate

Photograph from David H. Spach, MD

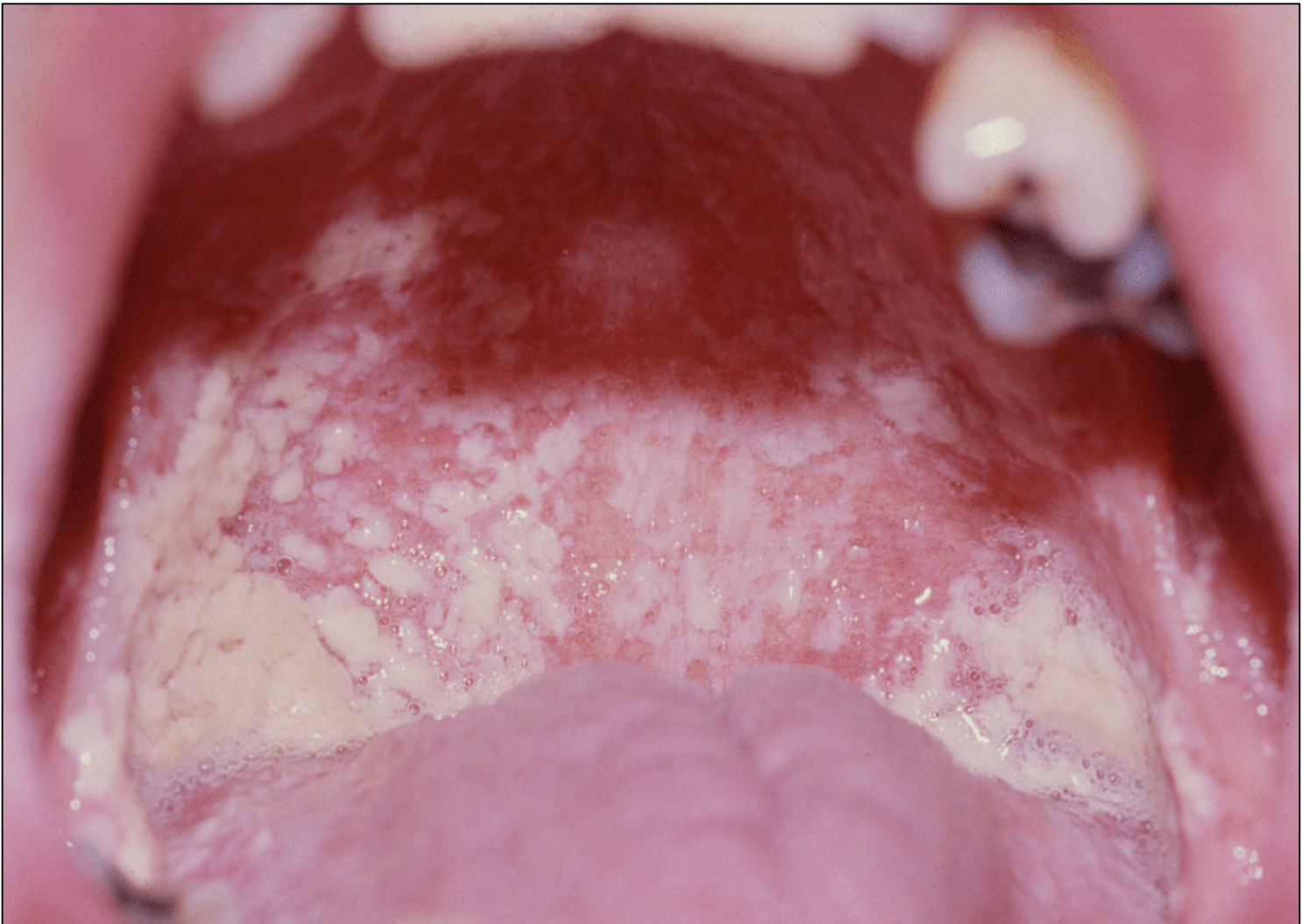


Figure 2 (Image Series) - Pseudomembranous Candidiasis
Image 2B: Pseudomembranous Candidiasis on Buccal Mucosa

Photograph from Mark Nichols, DDS, Dental Director, South Central AETC

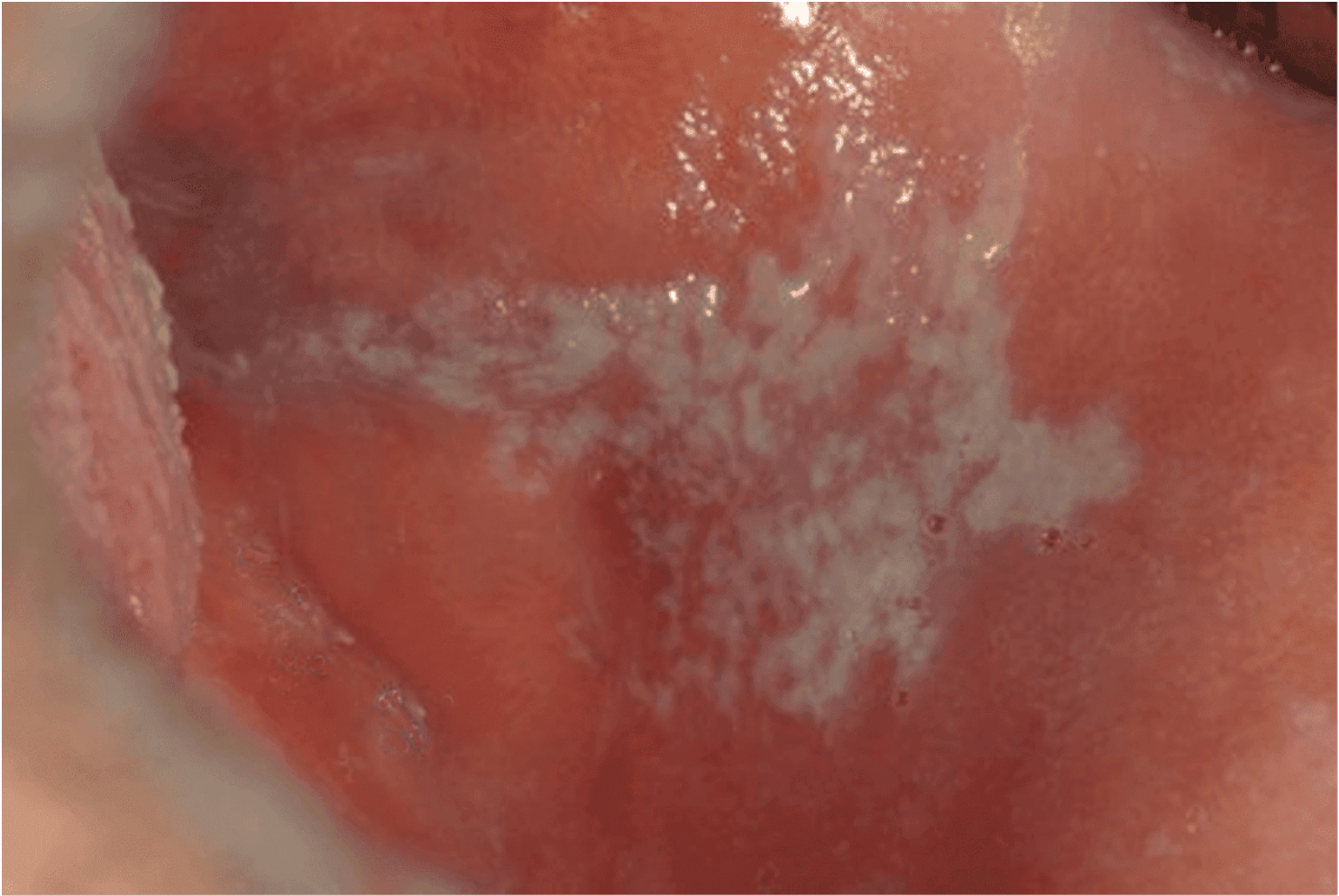


Figure 2 (Image Series) - Pseudomembranous Candidiasis
Image 2C: Pseudomembranous Candidiasis on Gingiva (Gums) and Lips

Photograph from David H. Spach, MD

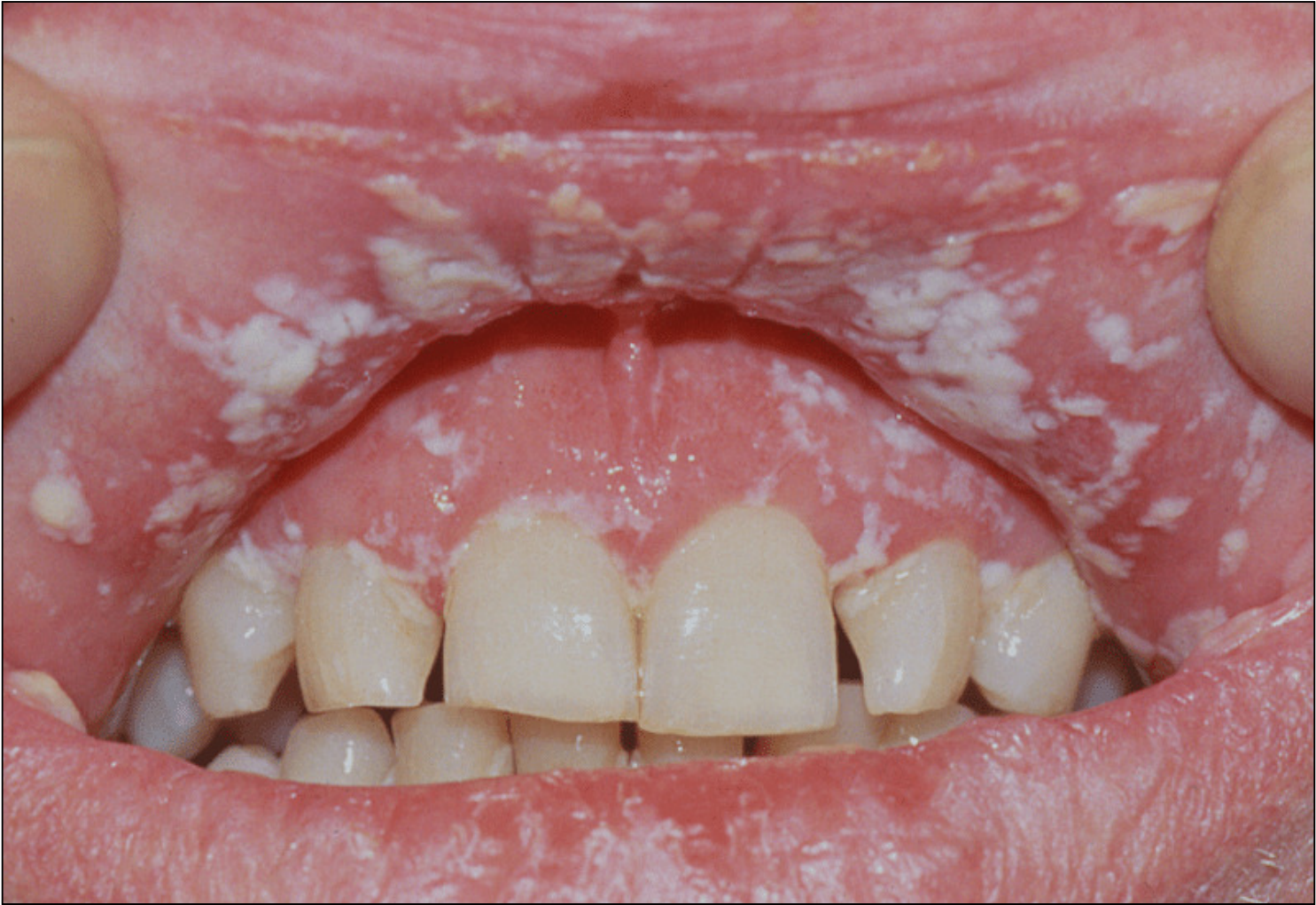

Figure 2 (Image Series) - Pseudomembranous Candidiasis
Image 2D: Pseudomembranous Candidiasis on Tongue

Photograph from David H. Spach, MD

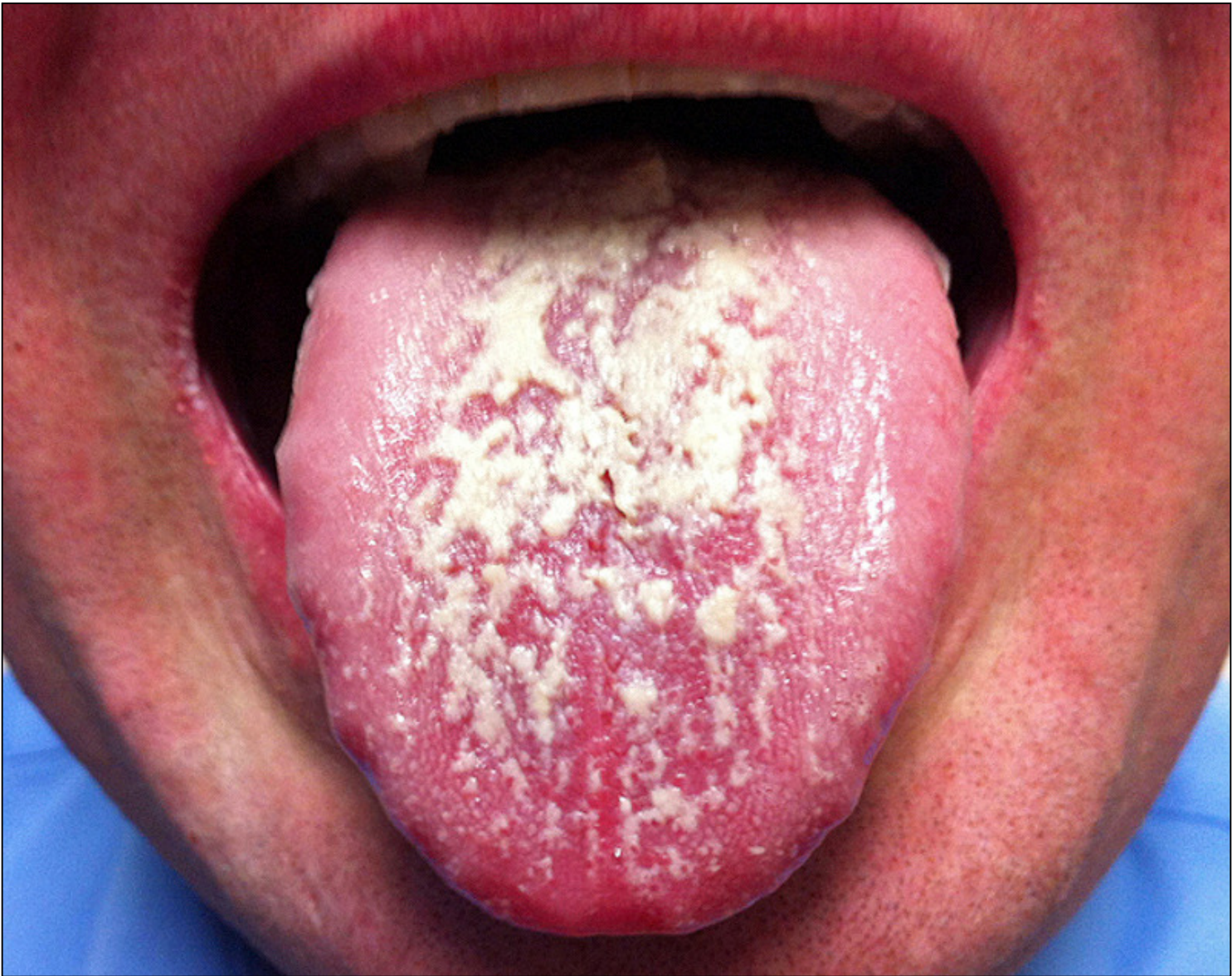

Figure 3 (Image Series) - Erythematous Candidiasis (Image Series) - Figure 3 (Image Series) - Erythematous Candidiasis
Image 3A: Erythematous Candidiasis on Palate

Photograph from Fariba S. Younai, DDS, Dental Director, Pacific AETC

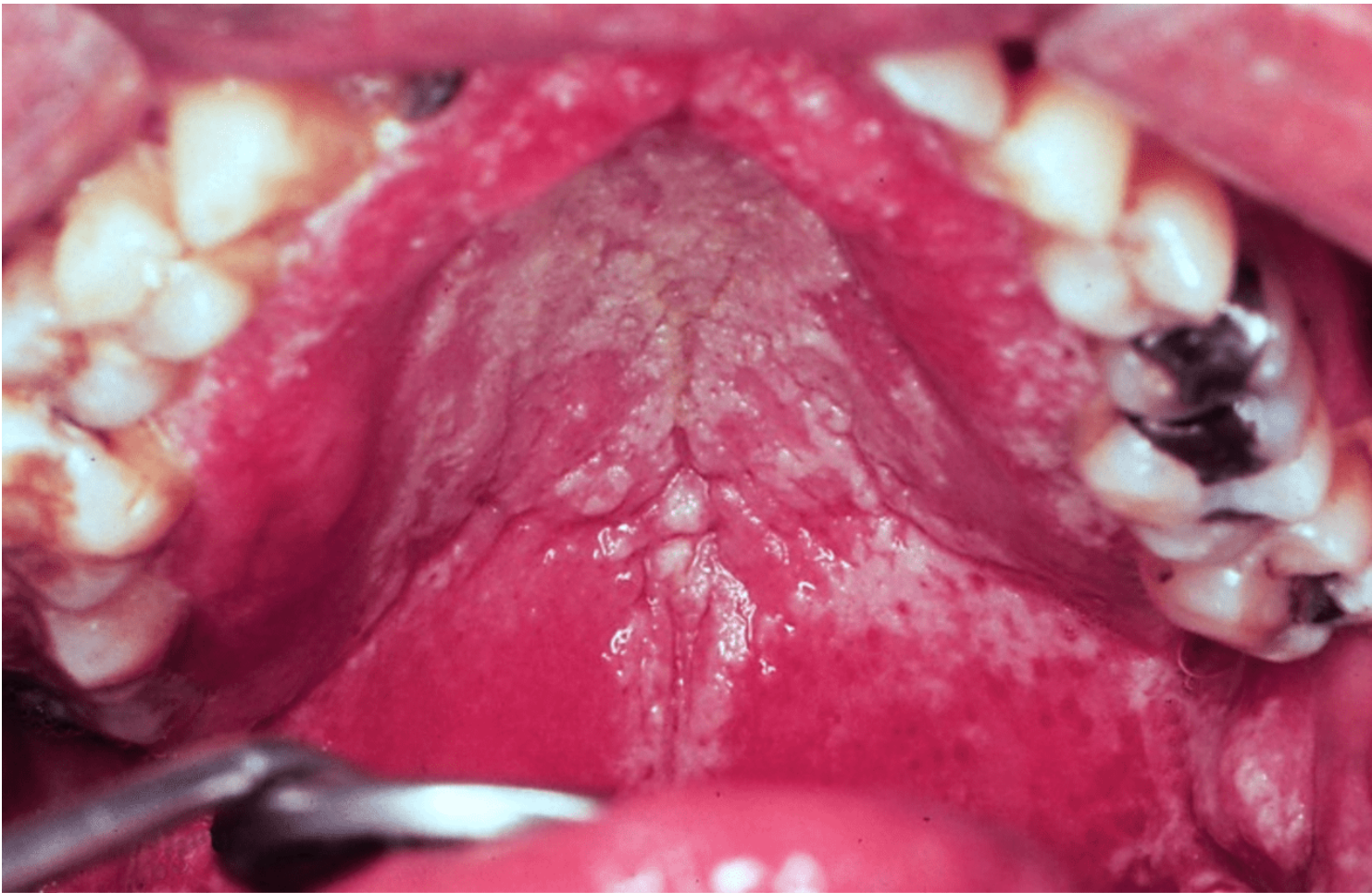

Figure 3 (Image Series) - Erythematous Candidiasis
Image 3B: Erythematous Candidiasis on Tongue

Photograph from David H. Spach, MD

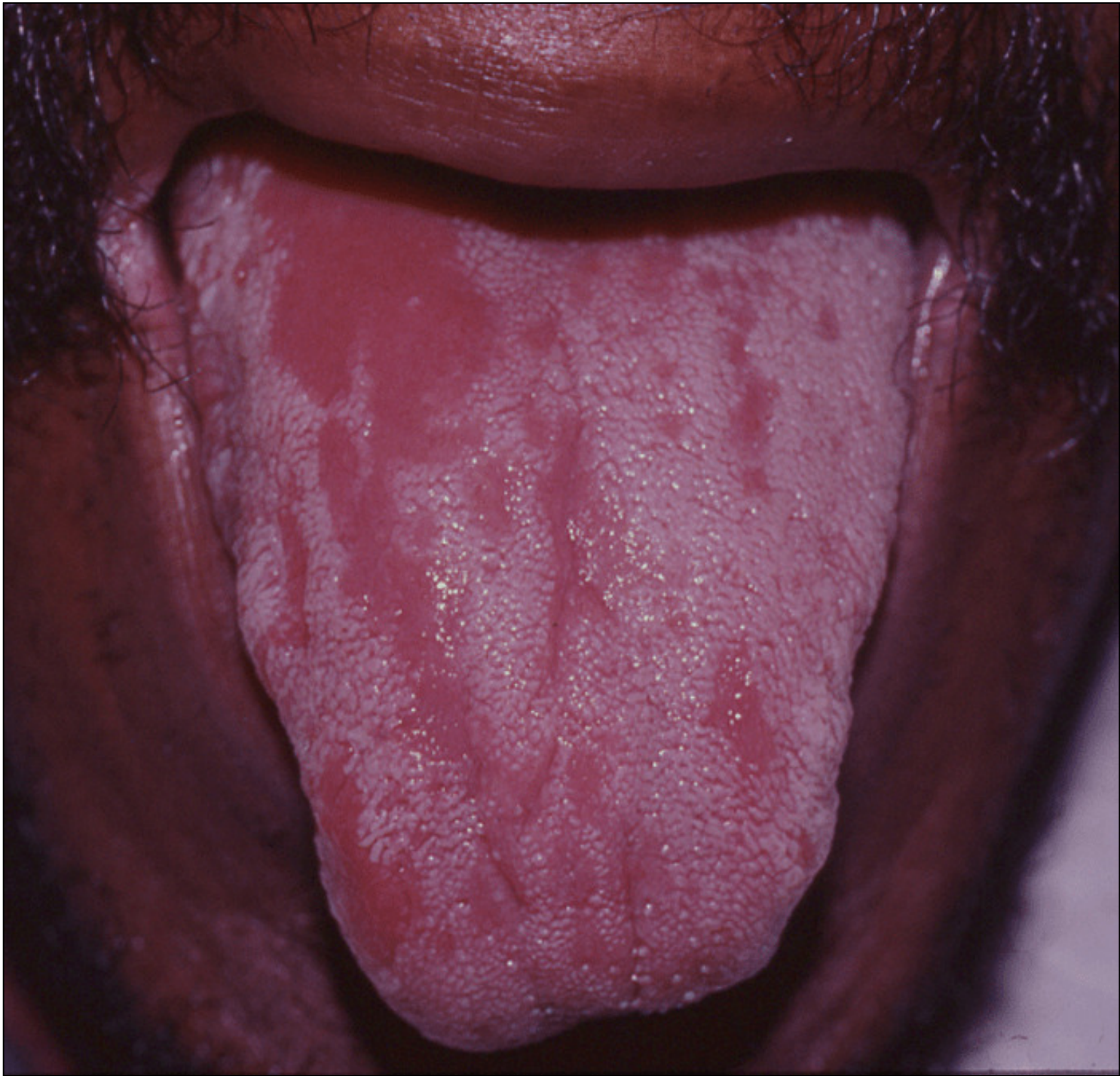

Figure 3 (Image Series) - Erythematous Candidiasis
Image 3C: Erythematous Candidiasis on Tongue with Fissuring

Photograph from Mark Nichols, DDS, Dental Director, South Central AETC

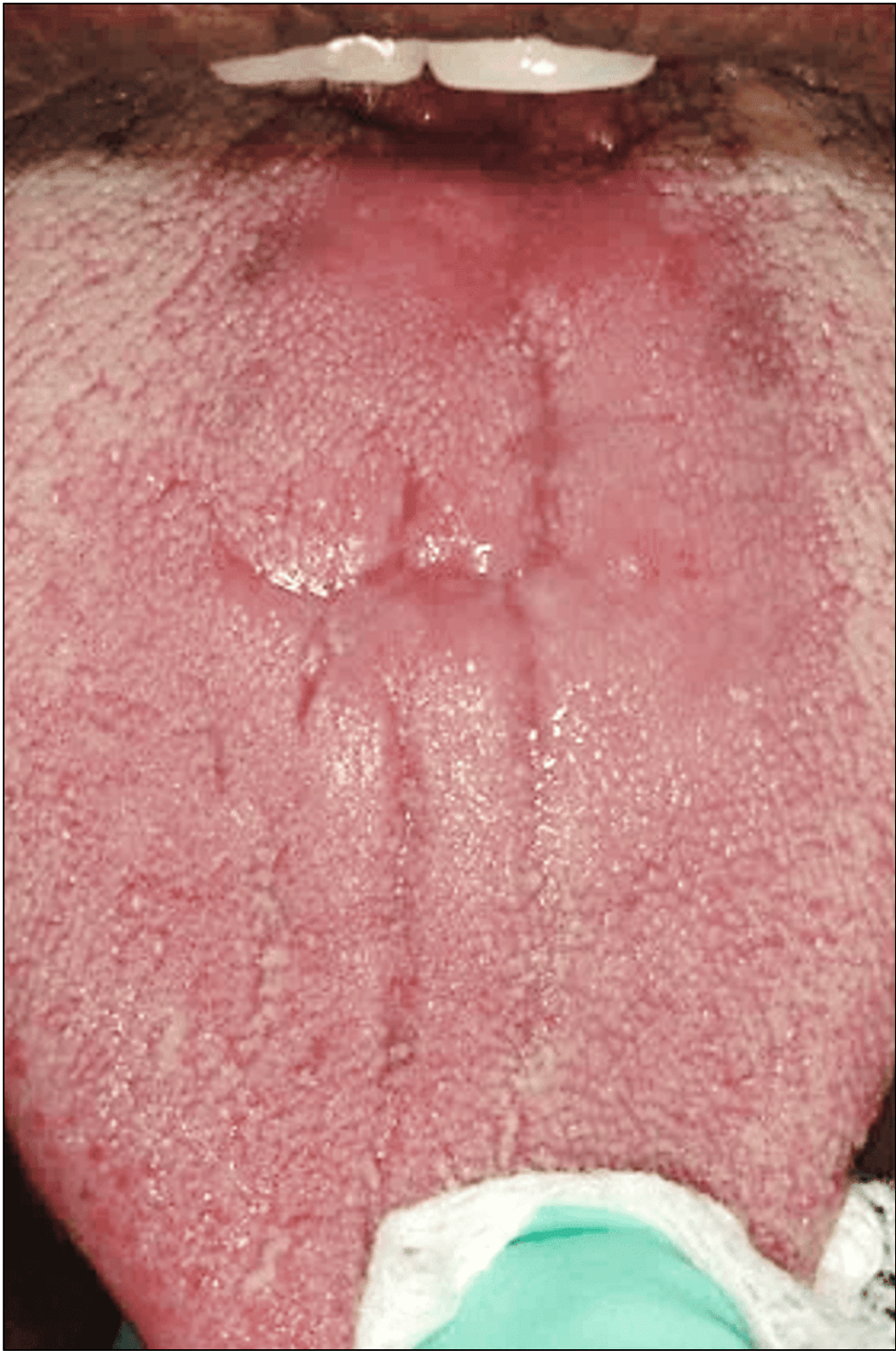

Figure 4 Hyperplastic Candidiasis on Buccal Mucosa

Photograph from Mark Nichols, DDS, Dental Director, South Central AETC

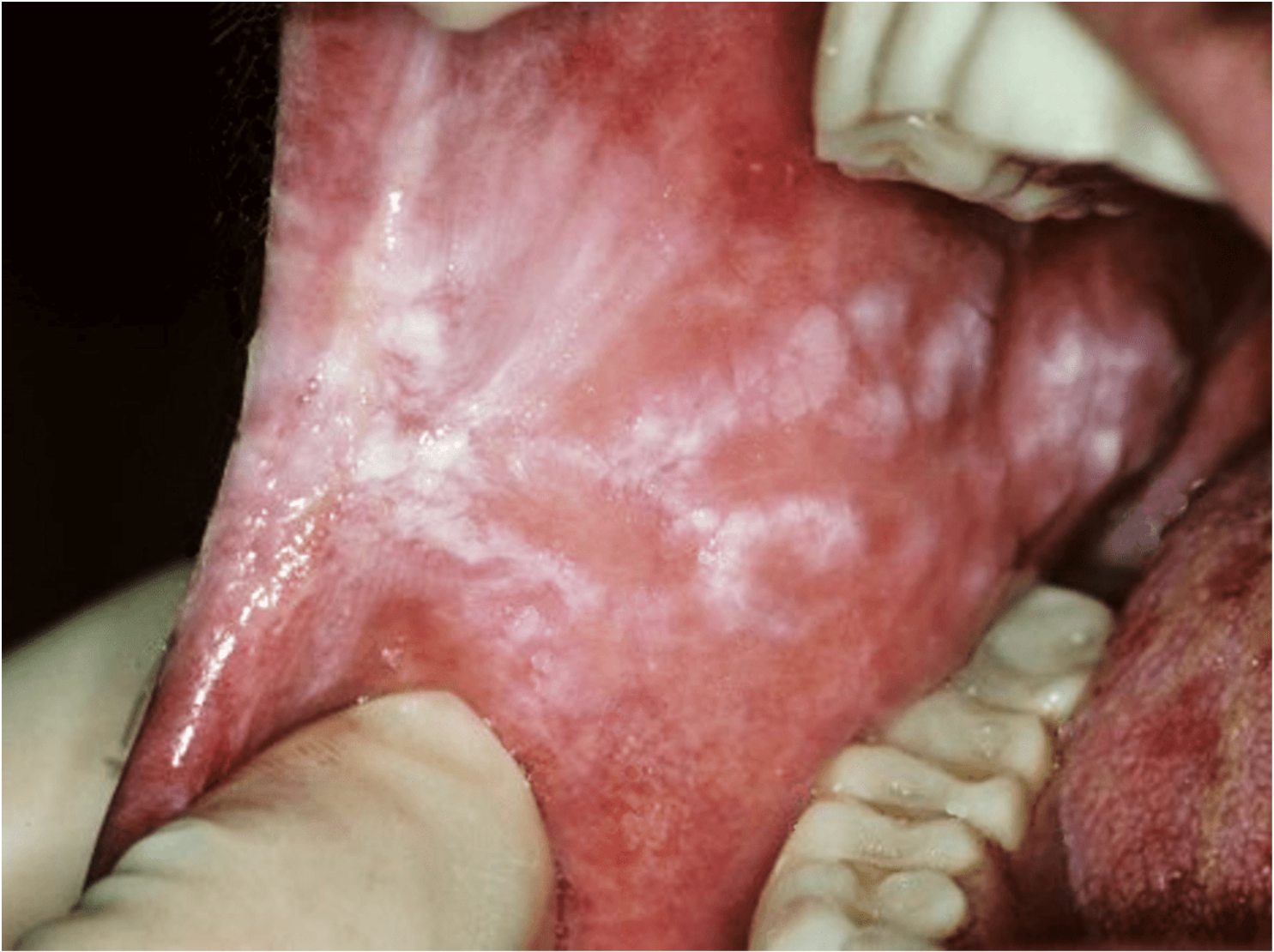


Figure 5 Angular Cheilitis

Photograph from David H. Spach, MD

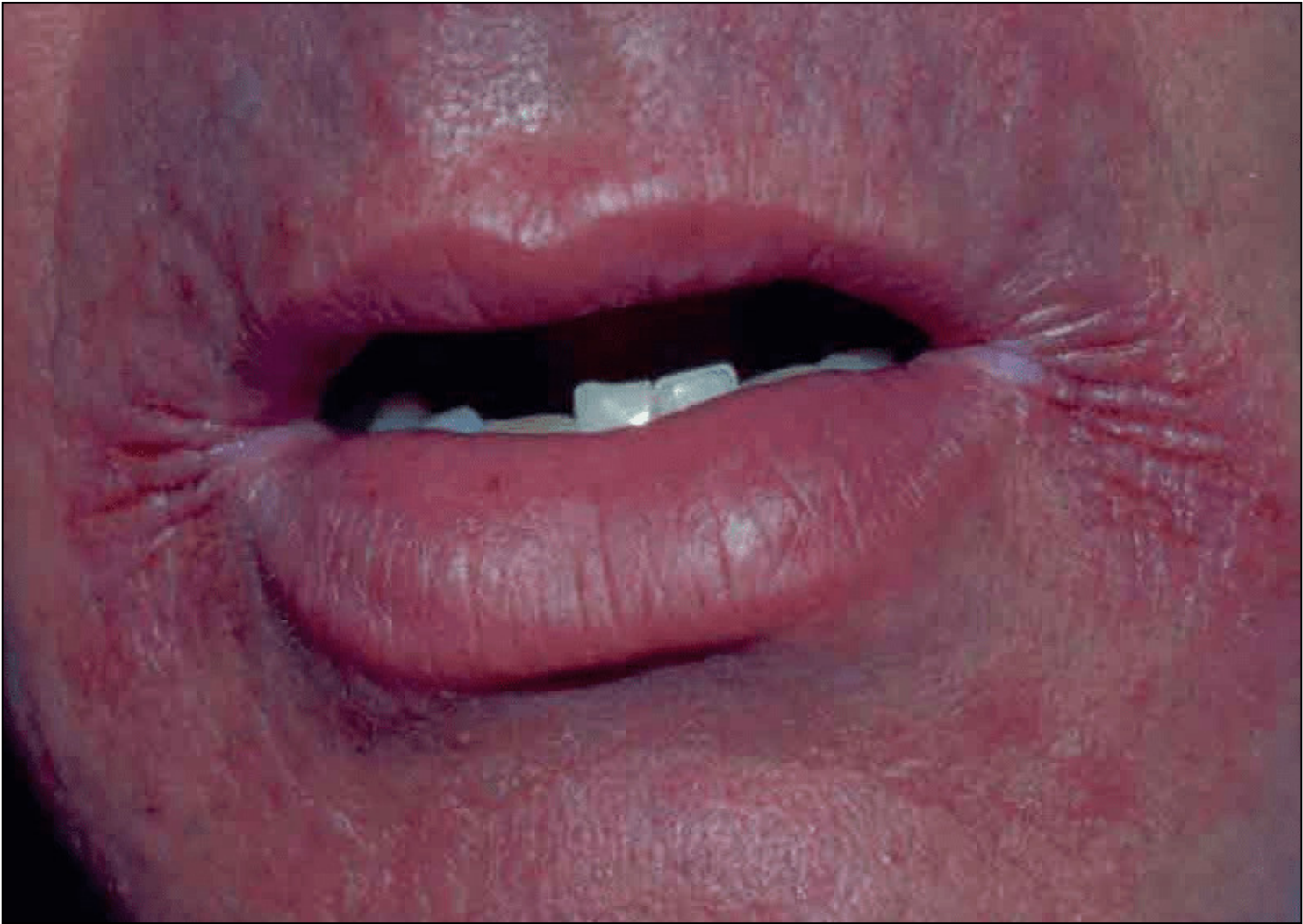

Figure 6 (Image Series) - Oral Hairy Leukoplakia (Image Series) - Figure 6 (Image Series) - Oral Hairy Leukoplakia
Image 6A: Oral Hairy Leukoplakia with Diffuse Tongue Involvement (Lateral View)

Photograph from Mark Nichols, DDS, Dental Director, South Central AETC

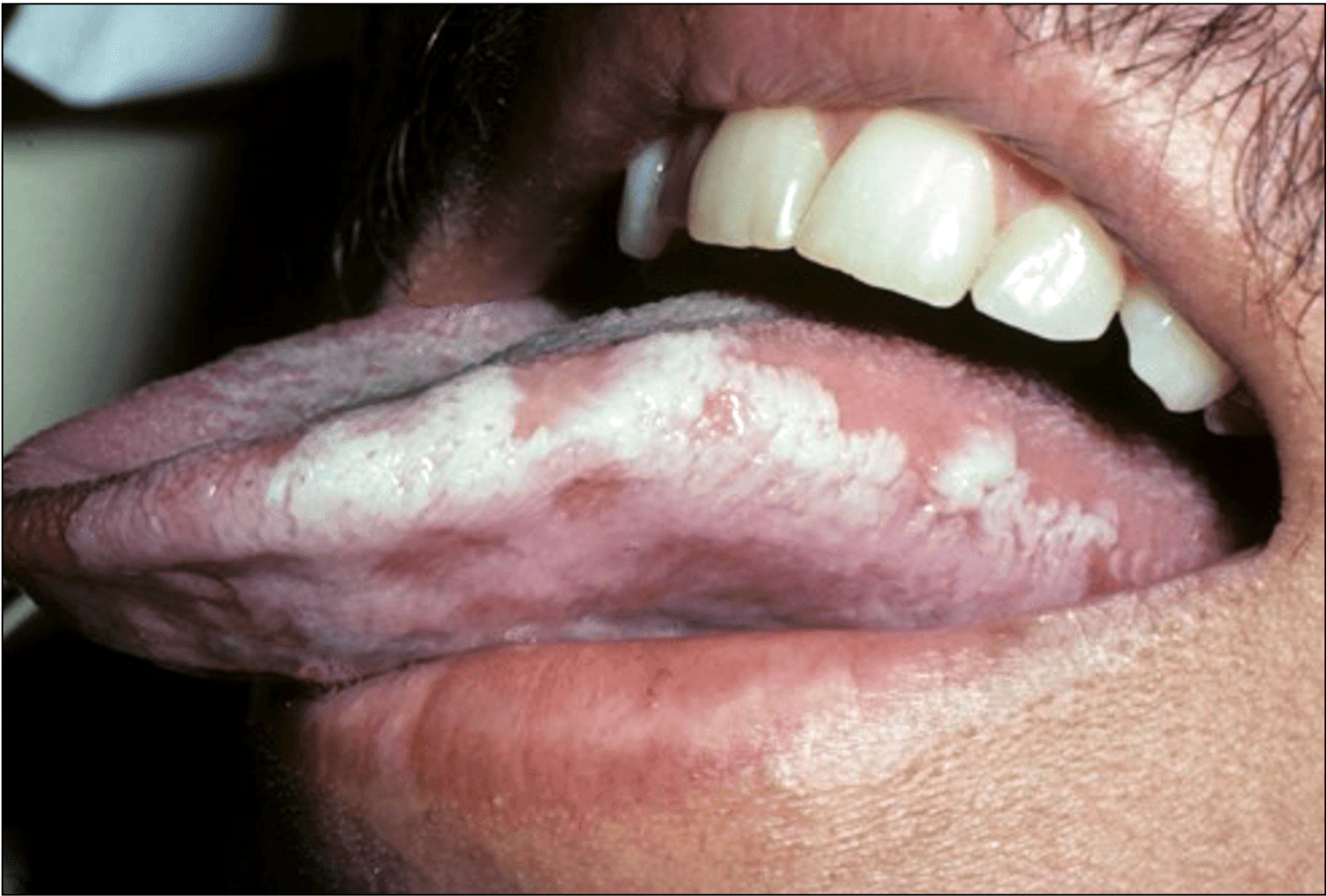

Figure 6 (Image Series) - Oral Hairy Leukoplakia
Image 6B: Oral Hairy Leukoplakia on Posterior Lateral Tongue

Photograph from Mark Nichols, DDS, Dental Director, South Central AETC

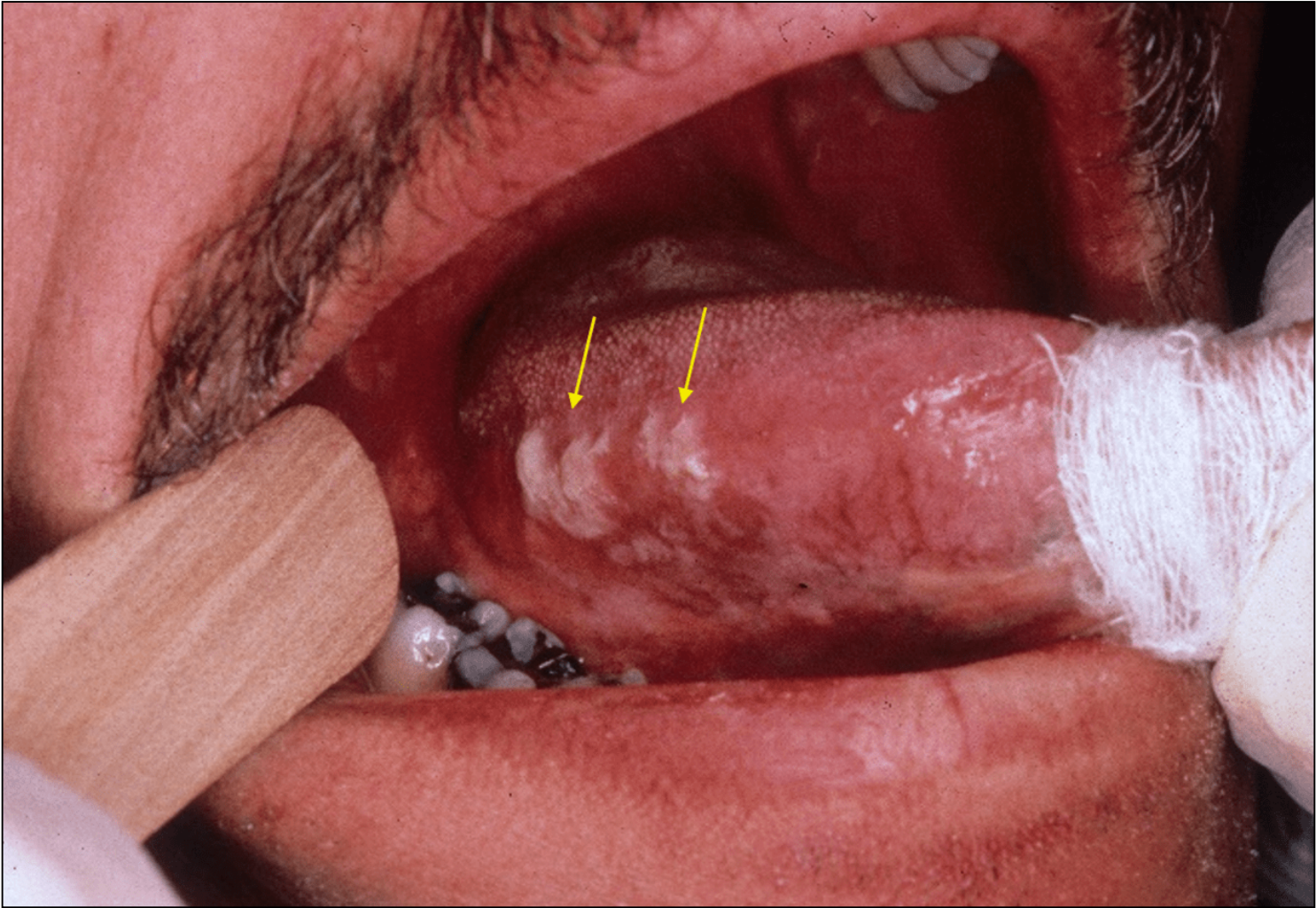


Figure 6 (Image Series) - Oral Hairy Leukoplakia
Image 6C: Oral Hairy Leukoplakia on Dorsal Ventral and Lateral Tongue Region

Photograph from David H. Spach, MD

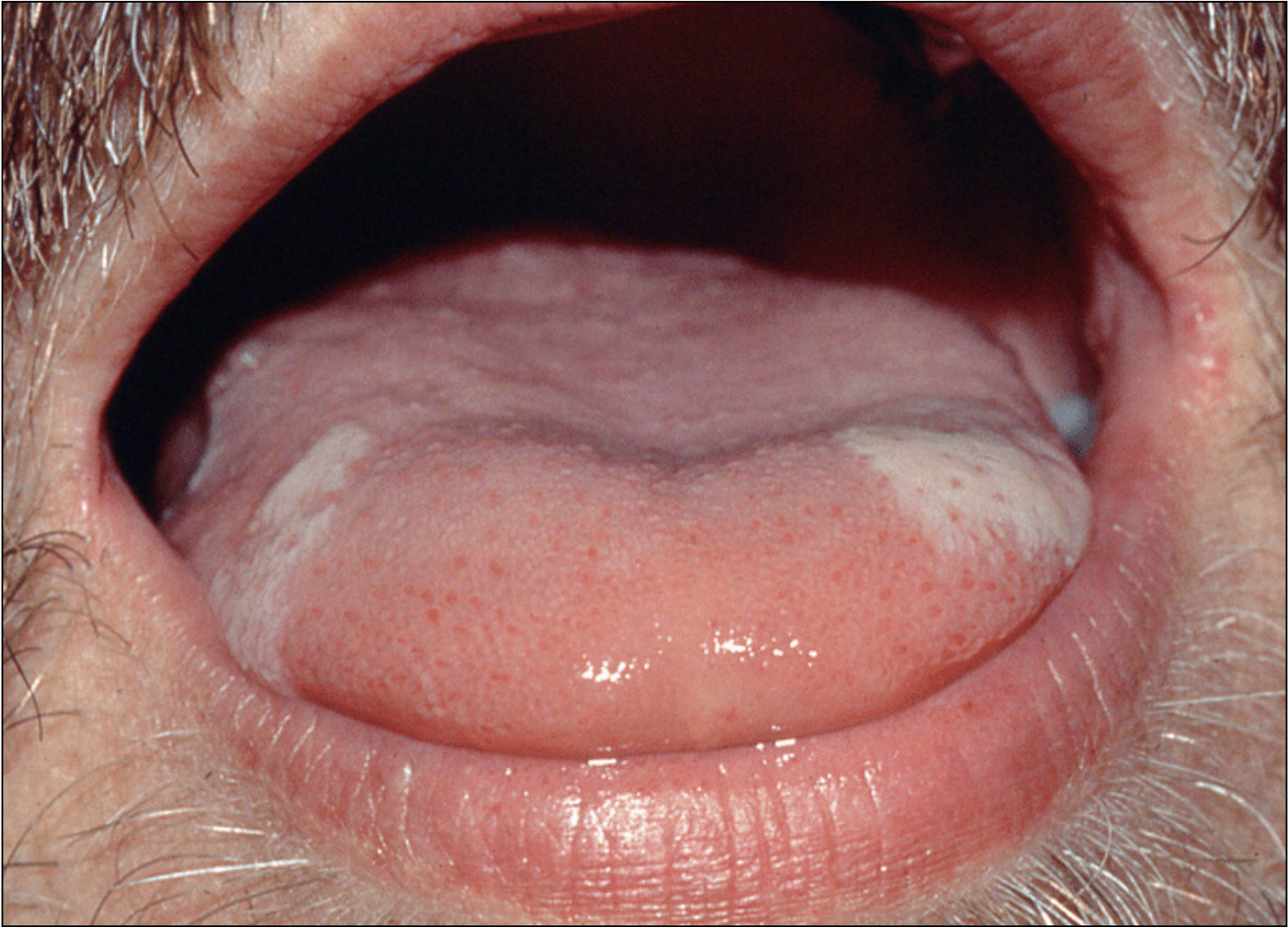

Figure 6 (Image Series) - Oral Hairy Leukoplakia
Image 6D: Oral Hairy Leukoplakia on Buccal Mucosa

Photograph from David H. Spach, MD

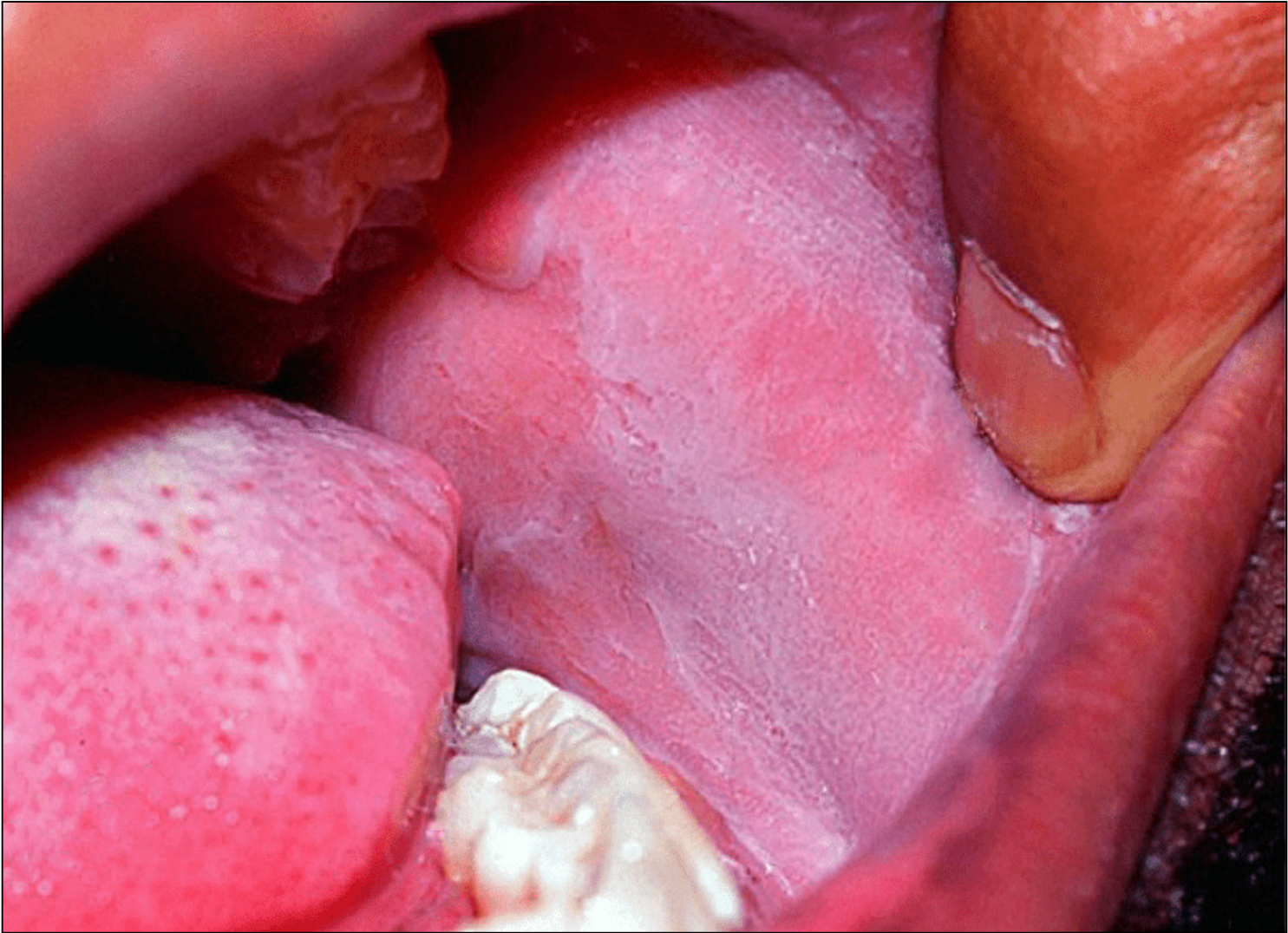


Figure 7 (Image Series) - Aphthous Stomatitis Lesions (Image Series) - Figure 7 (Image Series) - Aphthous Stomatitis Lesions
Image 7A: Aphthous Stomatitis on Lip

The black arrow points to a large aphthous lesion on the lip.

Photograph from David H. Spach, MD

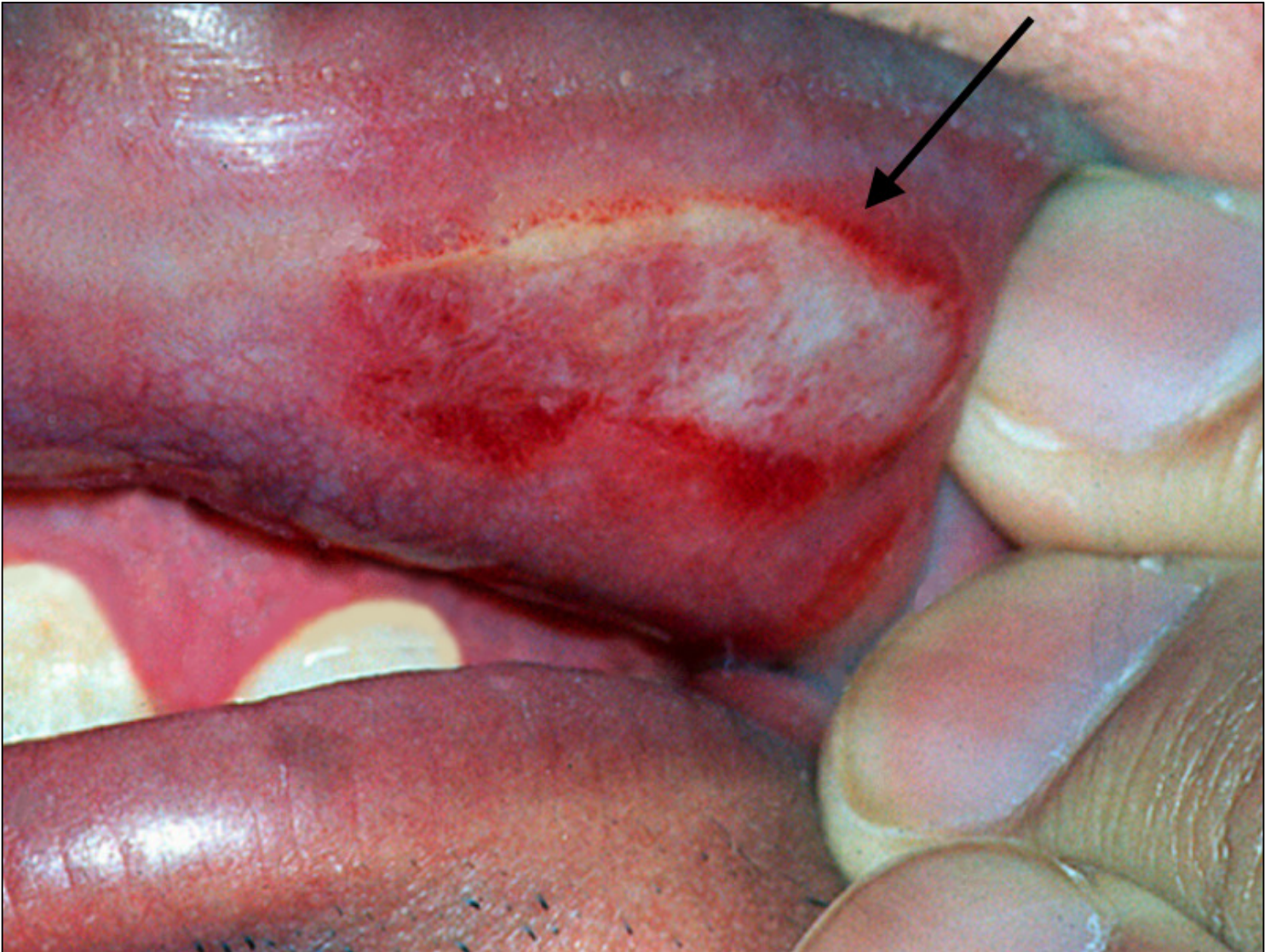


Figure 7 (Image Series) - Aphthous Stomatitis Lesions
Image 7B: Aphthous Lesion on Tongue

The black arrow points to large aphthous lesion on lateral tongue.

Photograph from David H. Spach, MD

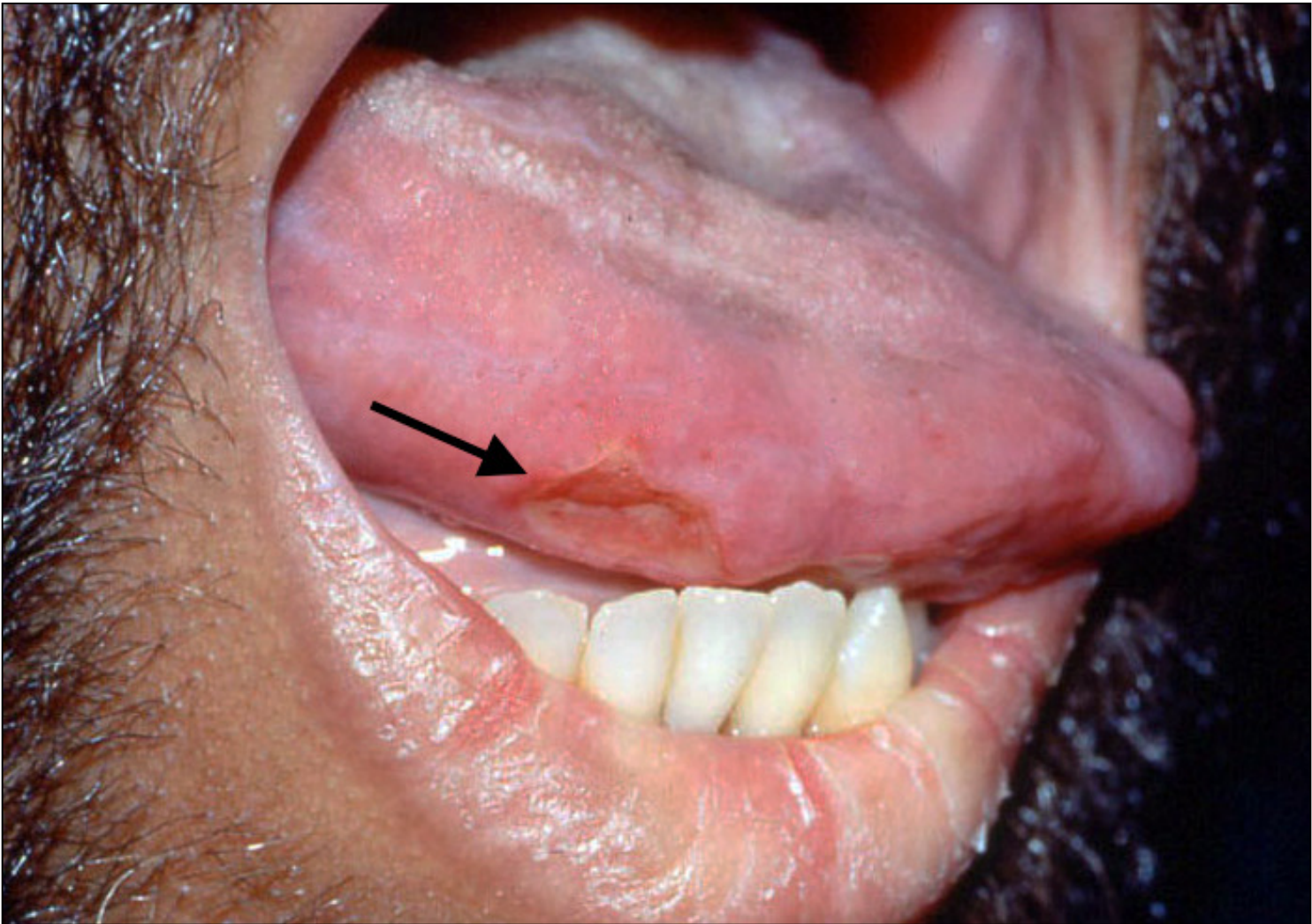


Figure 7 (Image Series) - Aphthous Stomatitis Lesions
Image 7C: Aphthous Minor Lesion

The yellow arrow denotes a small (minor) aphthous lesion on the lateral area of the tongue.

Photograph courtesy of Fariba S. Younai, DDS, Dental Director, Pacific AETC

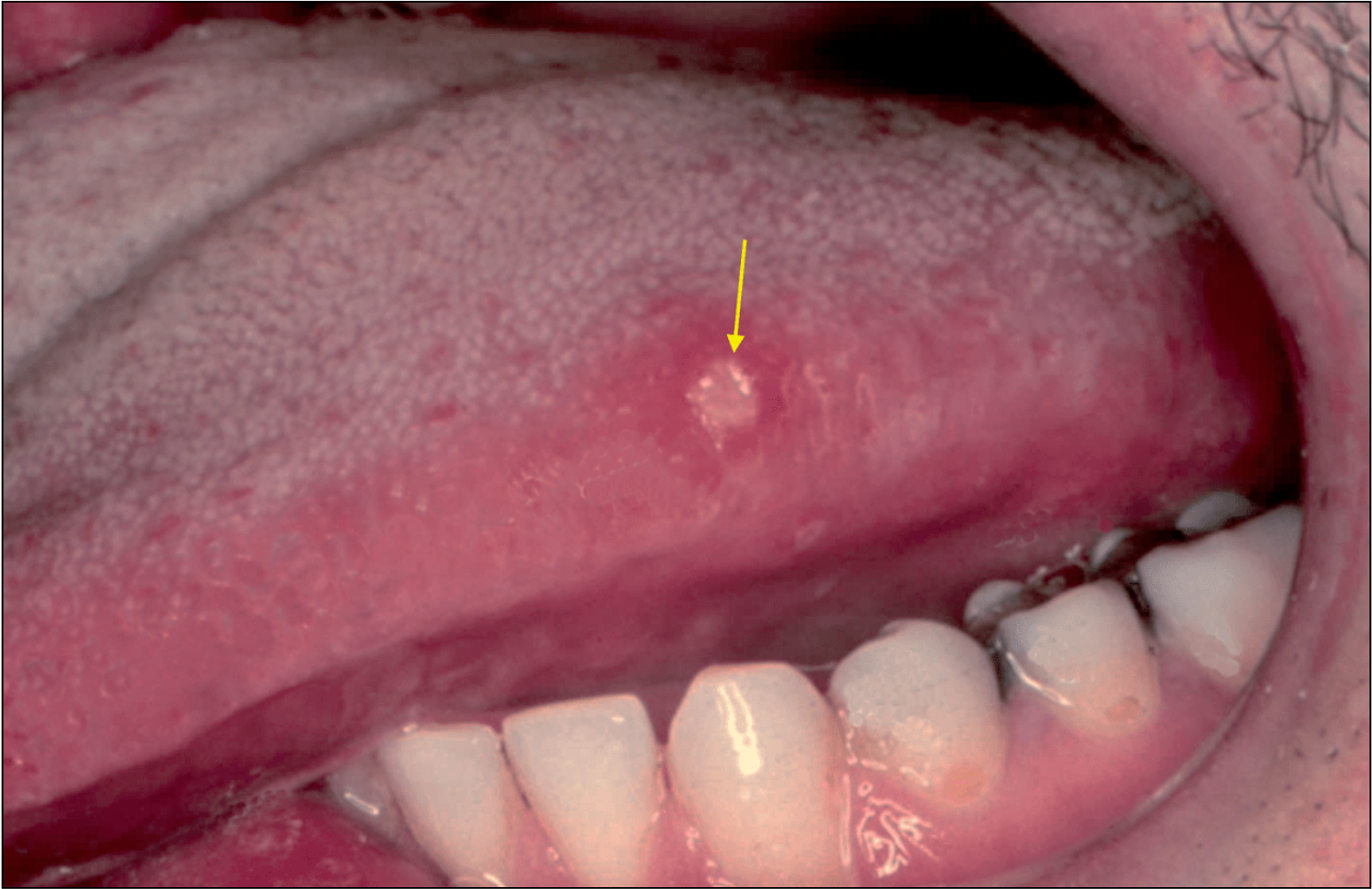

Figure 7 (Image Series) - Aphthous Stomatitis Lesions
Image 7D: Aphthous Major Lesion

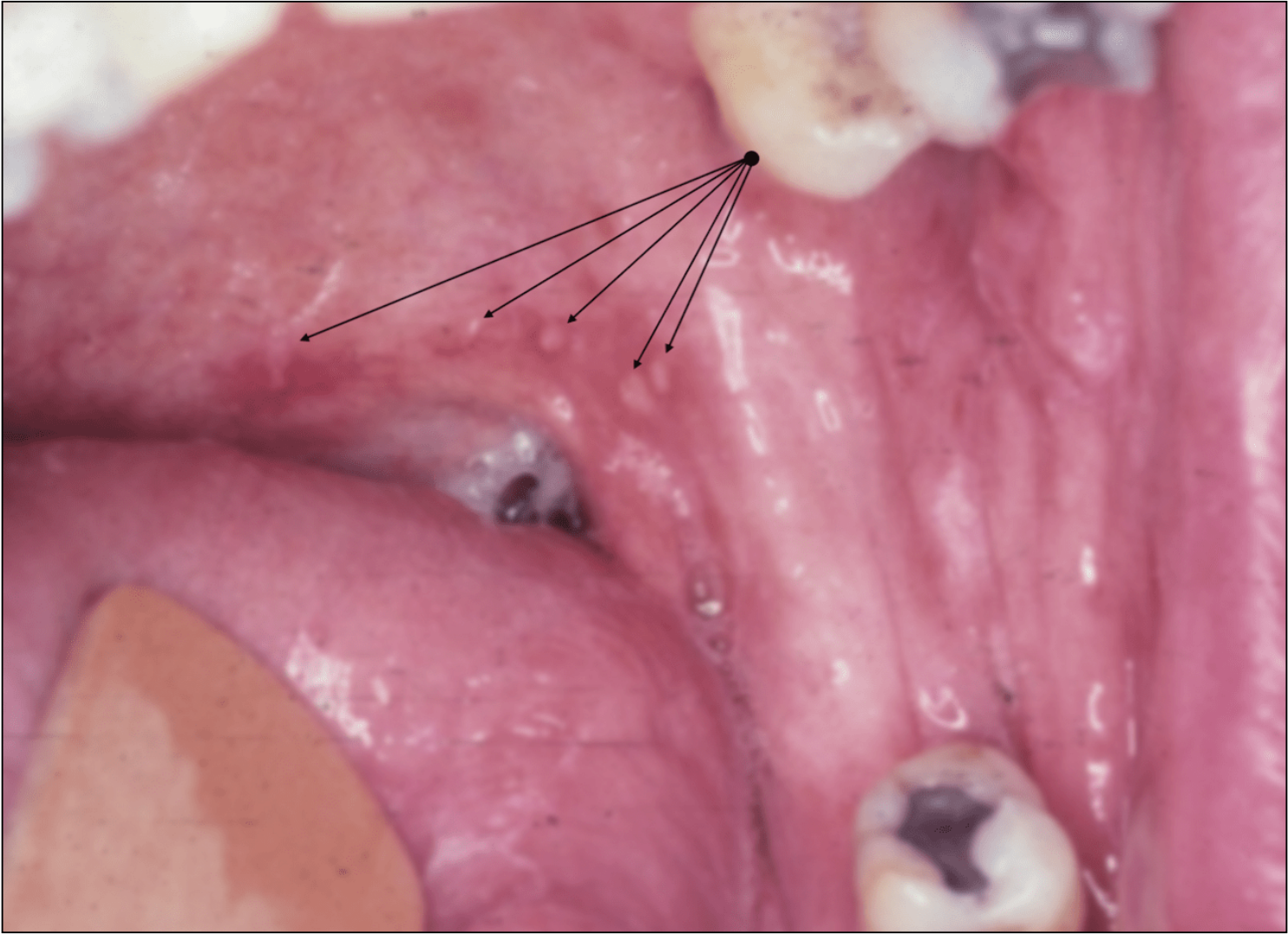
Photograph courtesy of Mark Nichols, DDS, Dental Director, South Central AETC

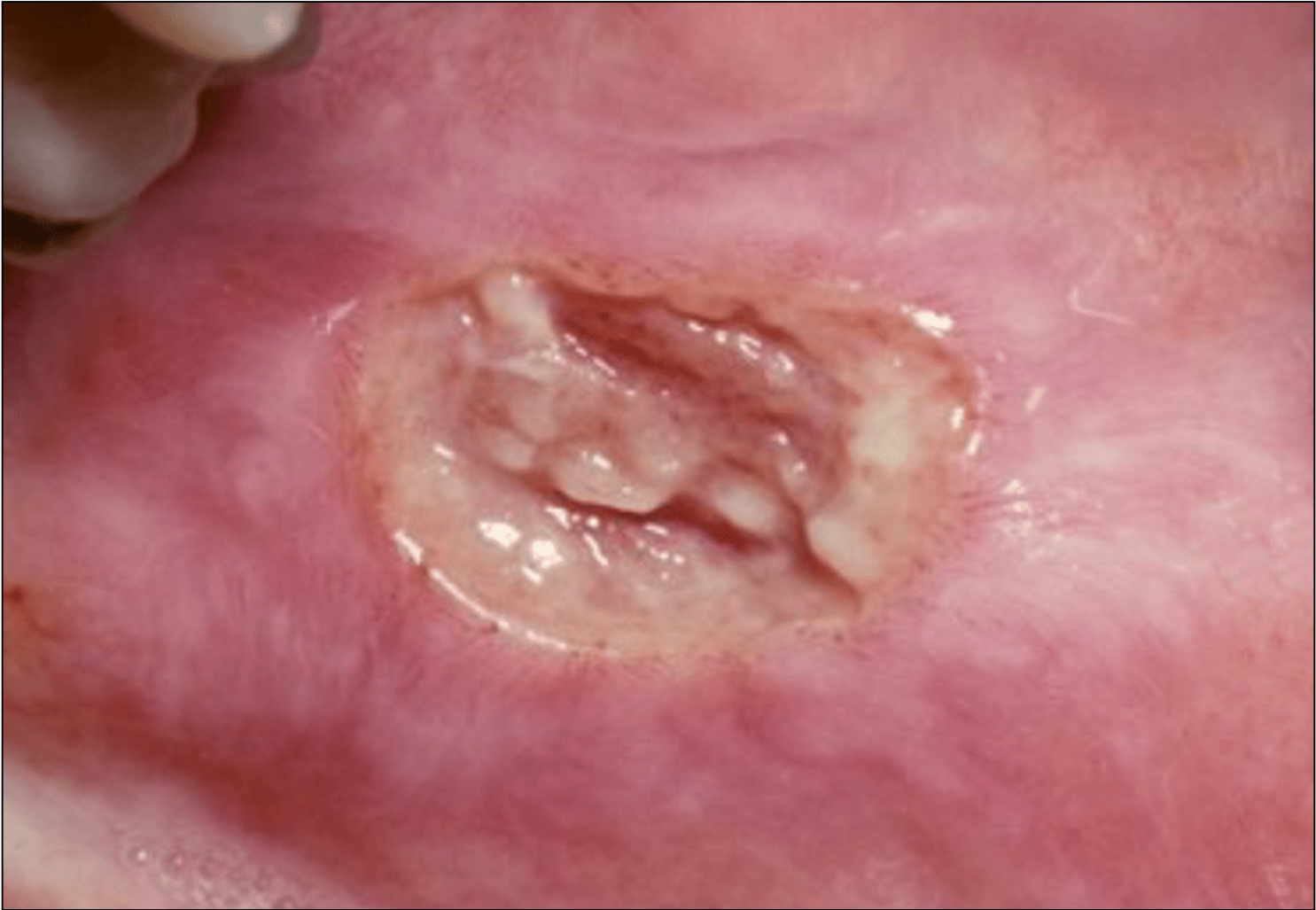

Figure 7 (Image Series) - Aphthous Stomatitis Lesions
Image 7E: Aphthous Herpetiform Lesions

The black arrows denote the multiple (herpetiform) aphthous lesions on the buccal mucosa.

Photograph courtesy of Fariba S. Younai, DDS, Dental Director, Pacific AETC



**Figure 8 (Image Series) - Oral Herpes Simplex Infection (Image Series) - Figure 8 (Image Series)
- Oral Herpes Simplex Infection**

Image 8A: Focal HSV Lesions on Lower Lip and Face

Characteristic focal cluster of vesicular lesions with a surrounding erythematous base.

Photograph from David H. Spach, MD

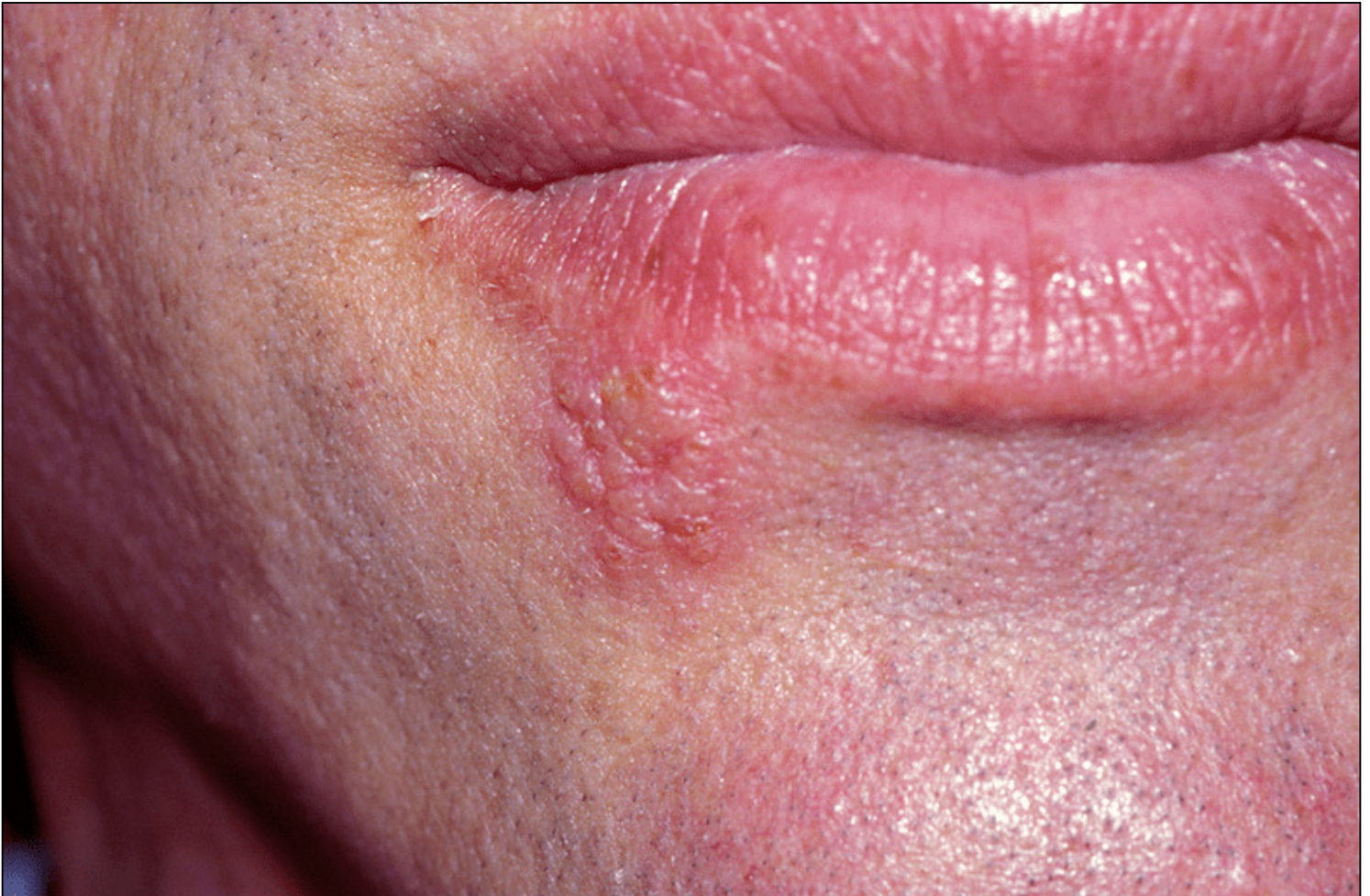

Figure 8 (Image Series) - Oral Herpes Simplex Infection
Image 8B: Oral HSV Lesion on Inner Lip

Photograph courtesy of David H. Spach, MD

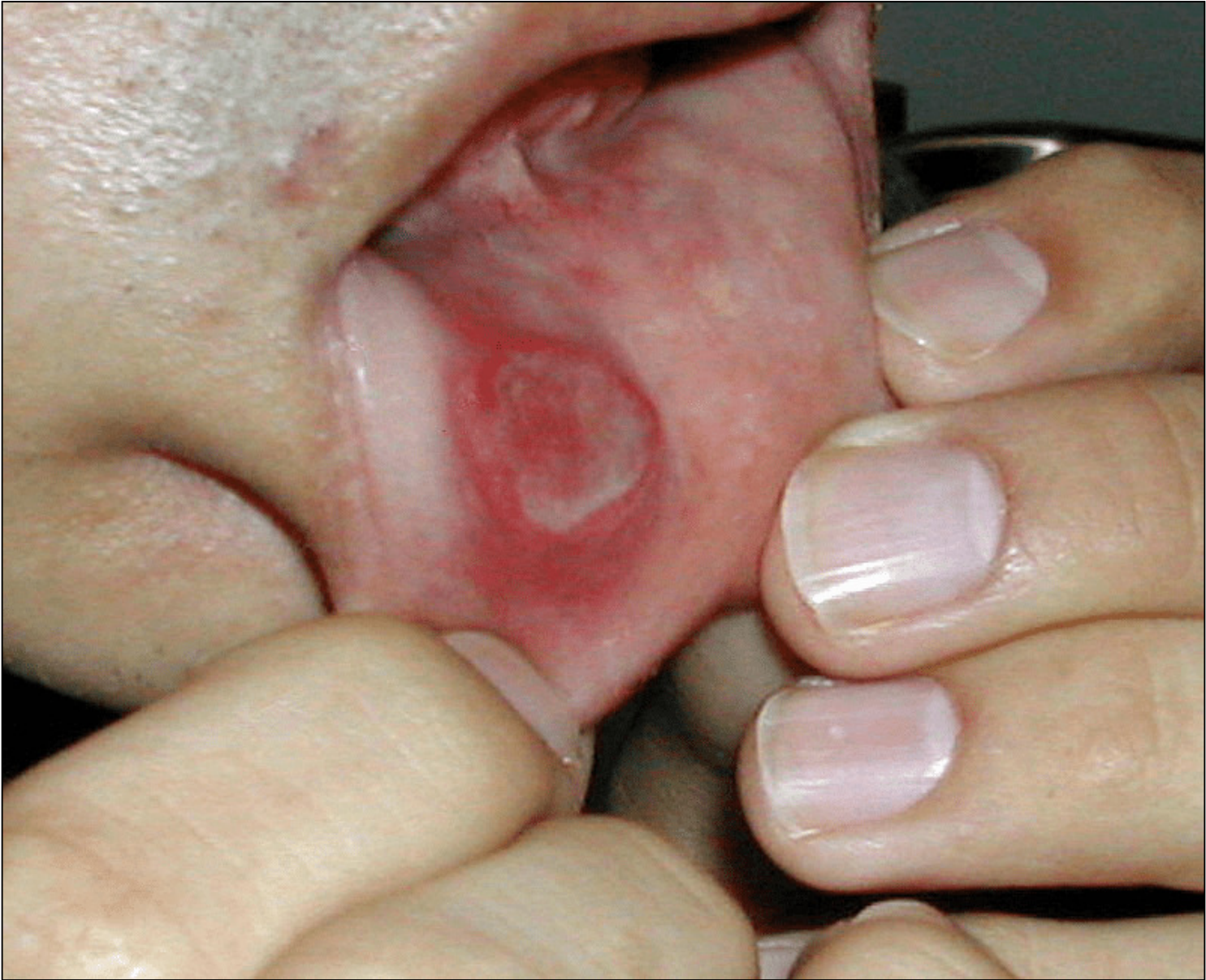

Figure 8 (Image Series) - Oral Herpes Simplex Infection
Image 8C: HSV Lesion on Tongue and Outer Lip

Photograph courtesy of David H. Spach, MD

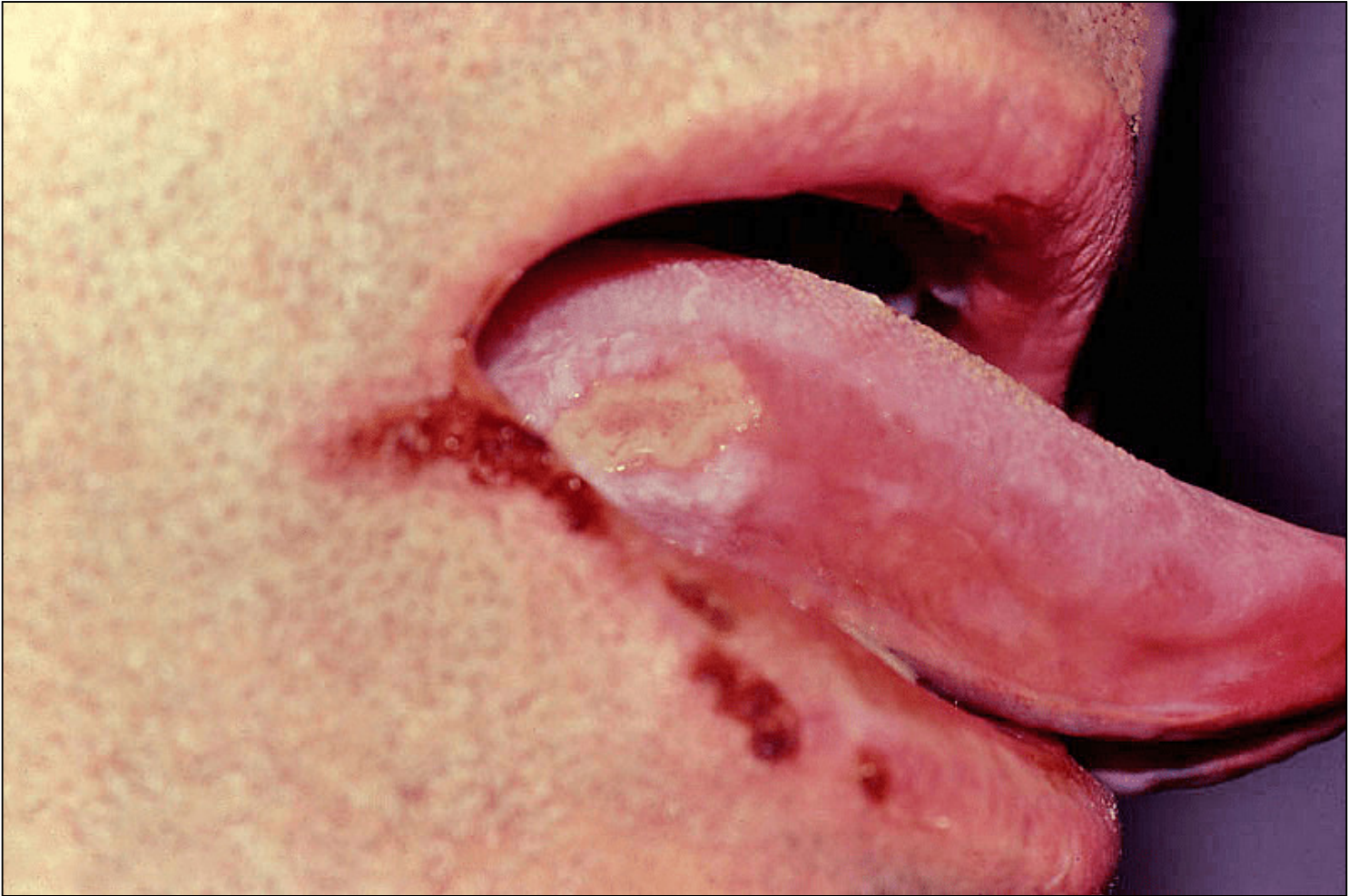

Figure 8 (Image Series) - Oral Herpes Simplex Infection
Image 8D: HSV Oral Lesion Involving Palate

Photograph courtesy of Mark Nichols, DDS, Dental Director, South Central AETC

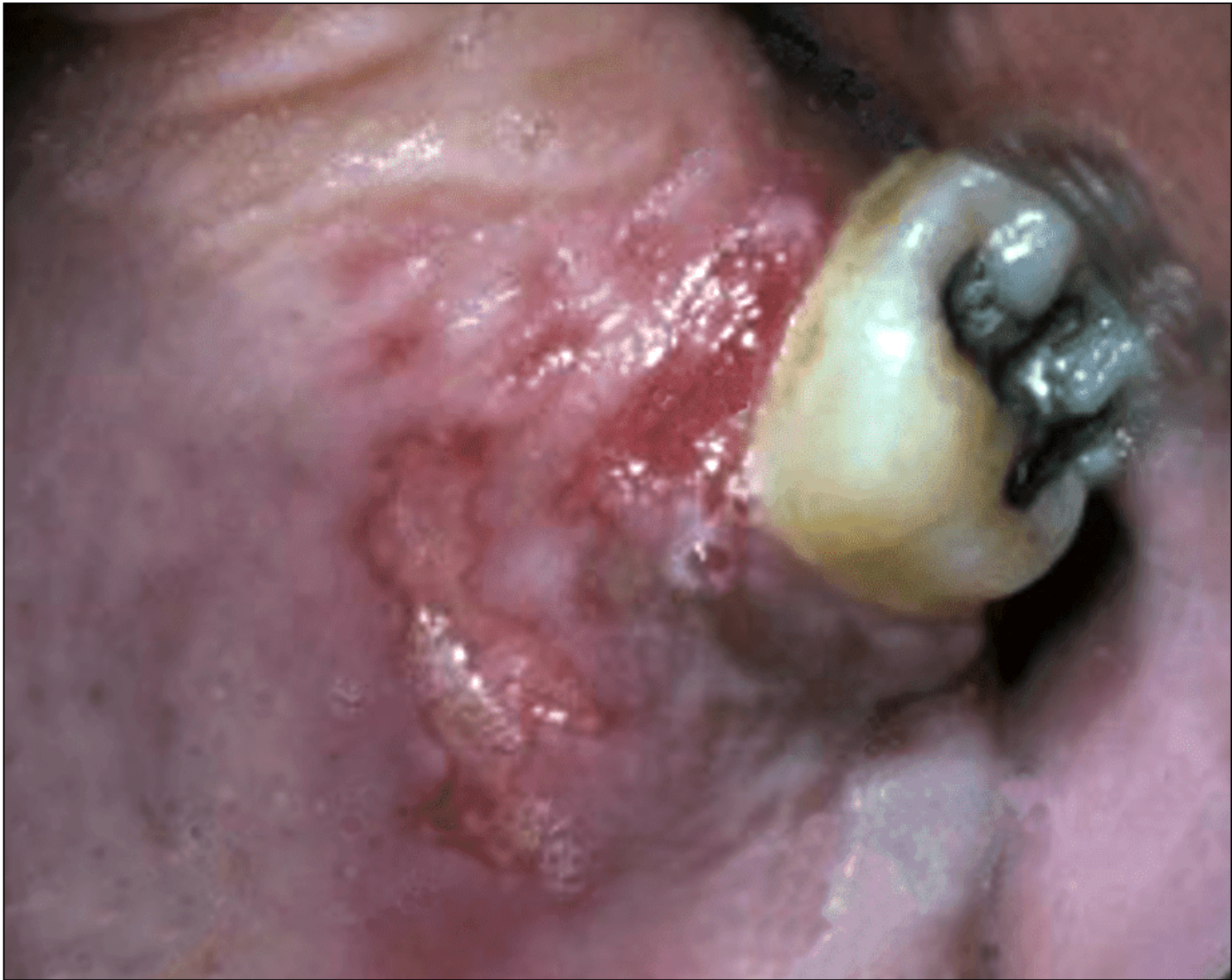

Figure 8 (Image Series) - Oral Herpes Simplex Infection
Image 8E: First Episode of Oral HSV

Photograph courtesy of David H. Spach, MD

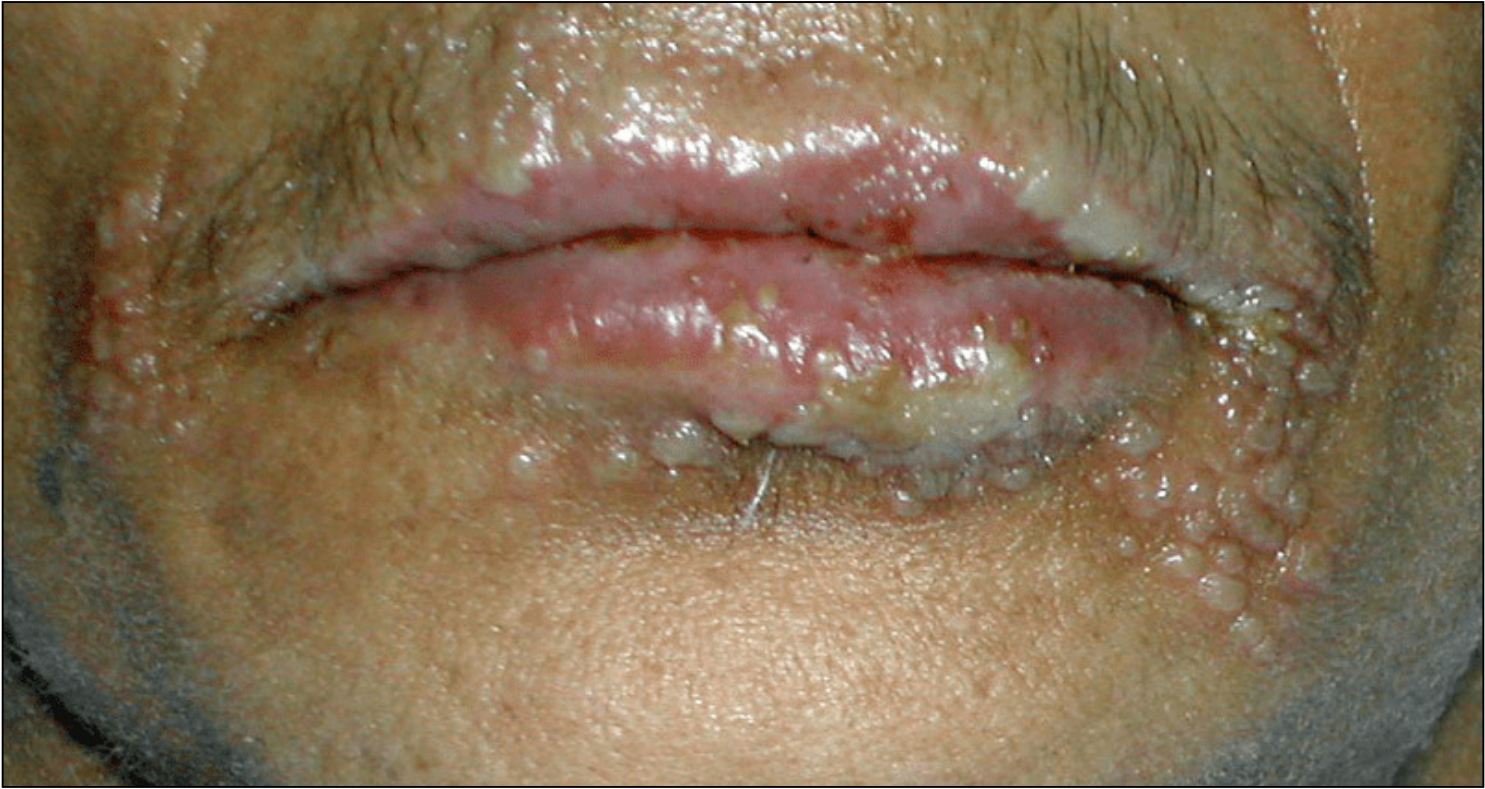

Figure 9 (Image Series) - Oral Kaposi's Sarcoma (Image Series) - Figure 9 (Image Series) - Oral Kaposi's Sarcoma
Image 9A: Oral Kaposi's Sarcoma on Maxillary Gingiva

Photograph courtesy of Mark Nichols, DDS, Dental Director, South Central AETC

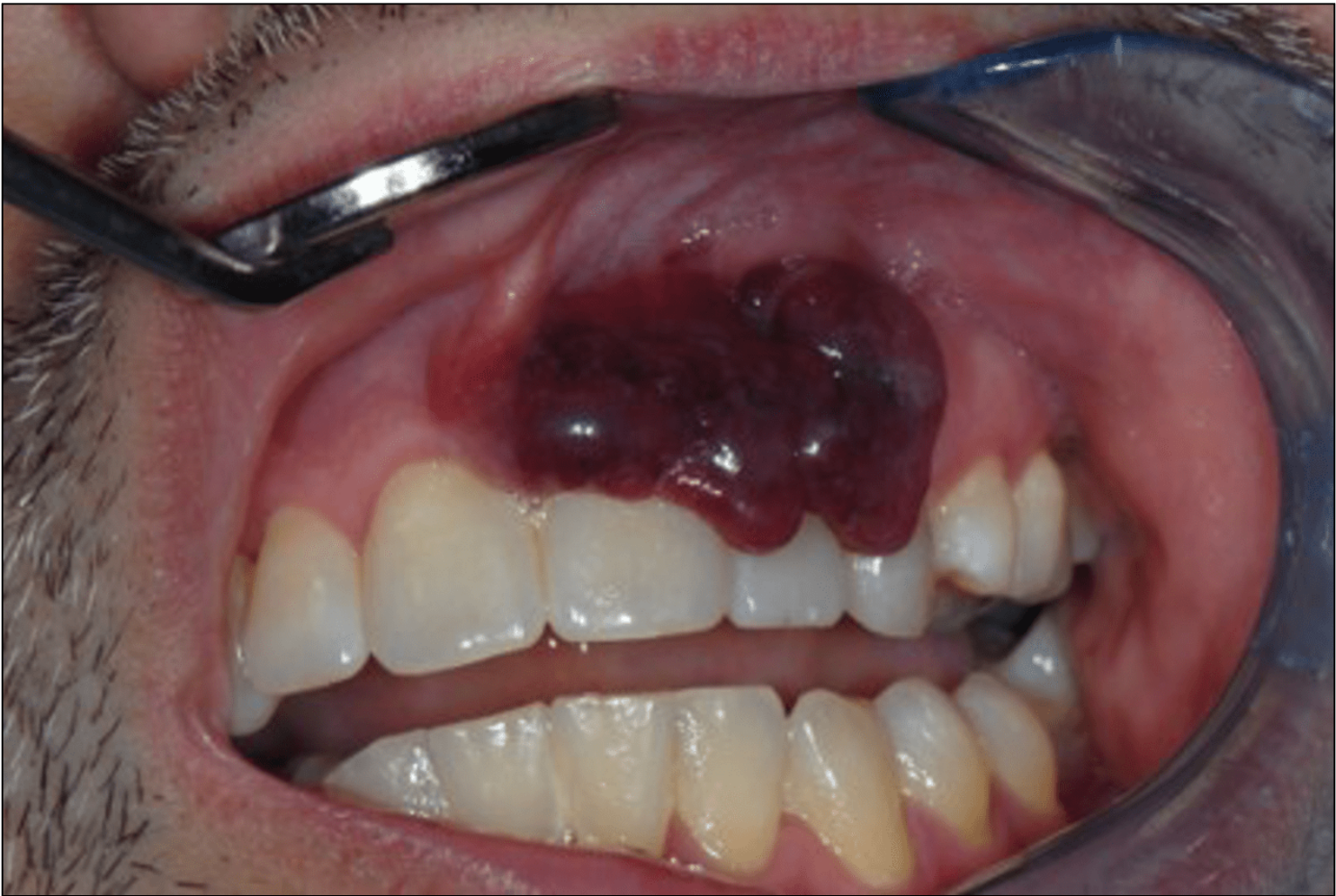

Figure 9 (Image Series) - Oral Kaposi's Sarcoma
Image 9B: Multiple Oral Kaposi's Sarcoma Lesions on Palate

Photograph courtesy of Deborah A. Stimpson, PA

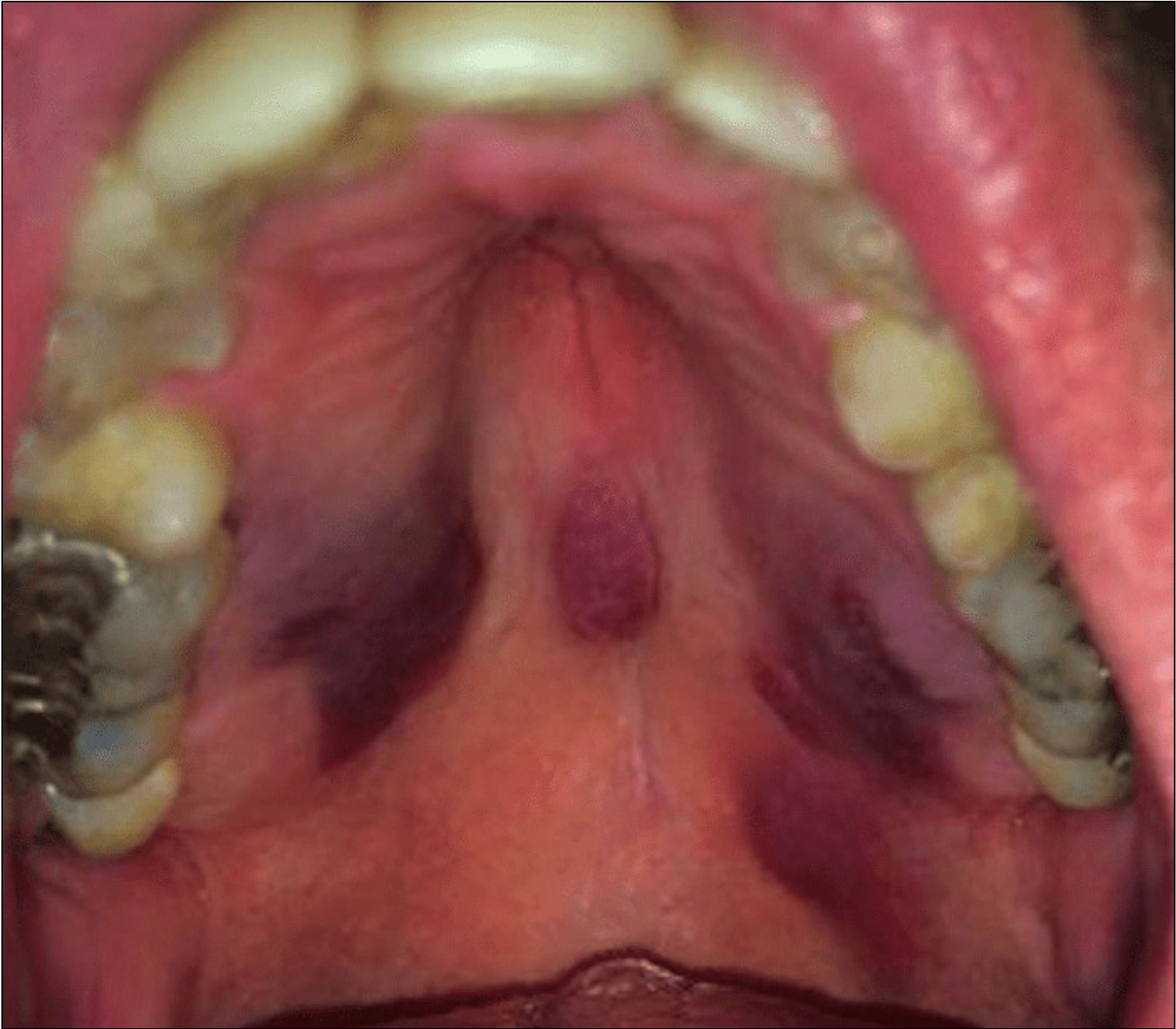

Figure 9 (Image Series) - Oral Kaposi's Sarcoma
Image 9C: Extensive Nodular Oral Kaposi's Sarcoma on Palate

Photograph courtesy of Brian R. Wood, MD

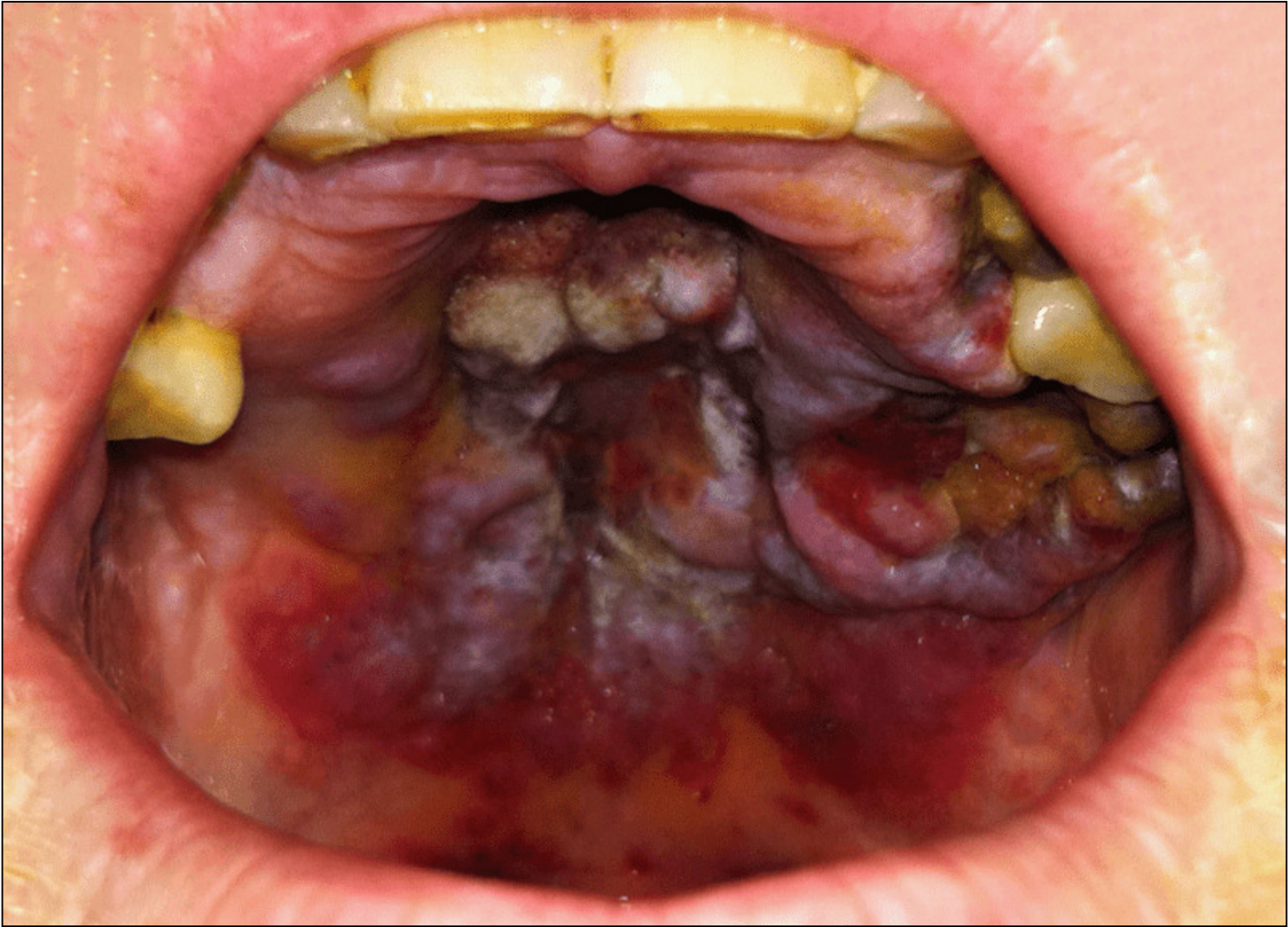

Figure 10 (Image Series) - HPV-Associated Oral Non-Cancerous Lesions (Image Series) - Figure 10 (Image Series) - HPV-Associated Oral Non-Cancerous Lesions
Image 10A: HPV-Associated Oral Squamous Papilloma

Photograph courtesy of Fariba S. Younai, DDS, Dental Director, Pacific AETC

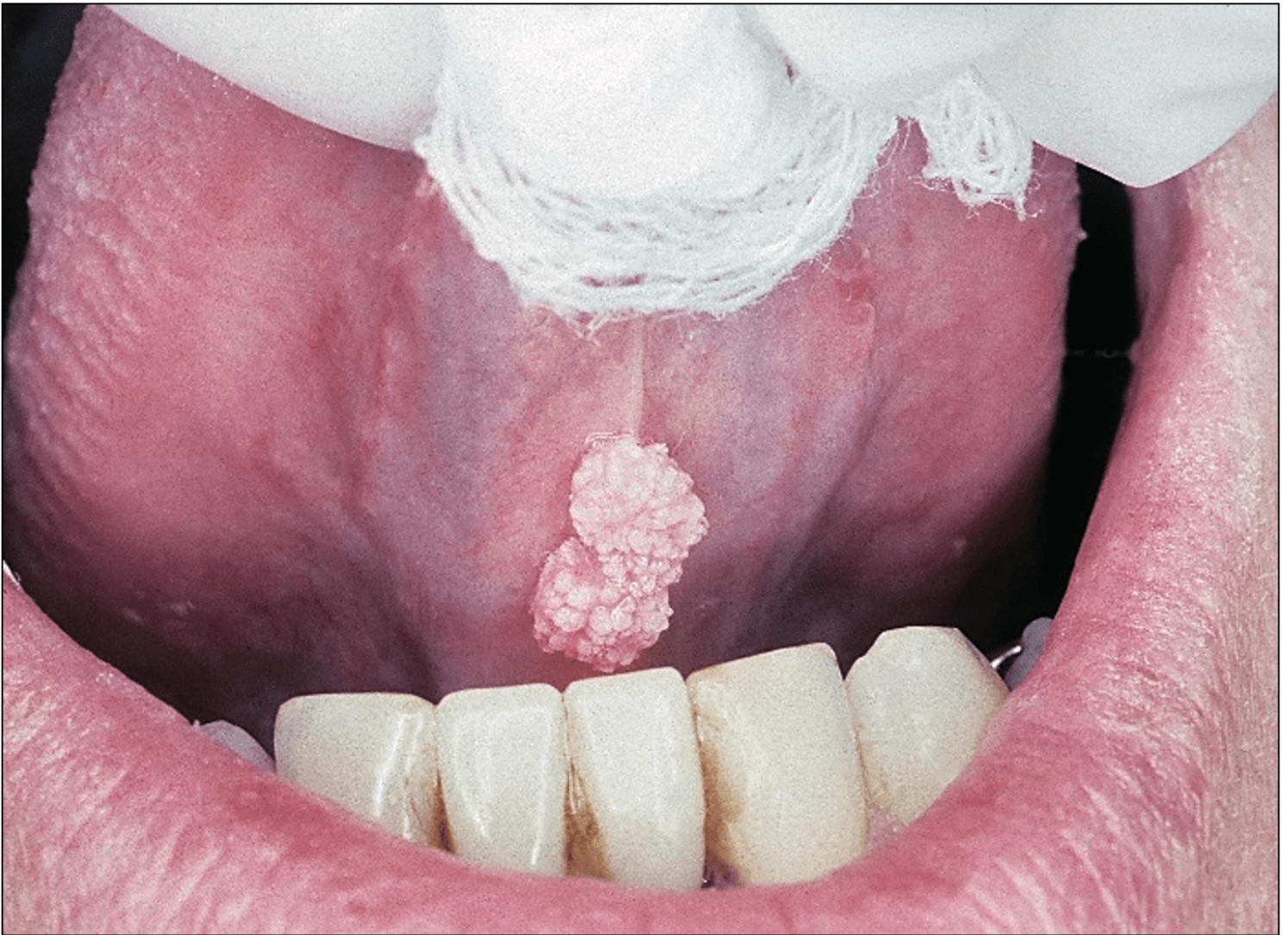

Figure 10 (Image Series) - HPV-Associated Oral Non-Cancerous Lesions
Image 10B: HPV-Associated Oral Condyloma

Photograph courtesy of Mark Nichols, DDS, Dental Director, South Central AETC

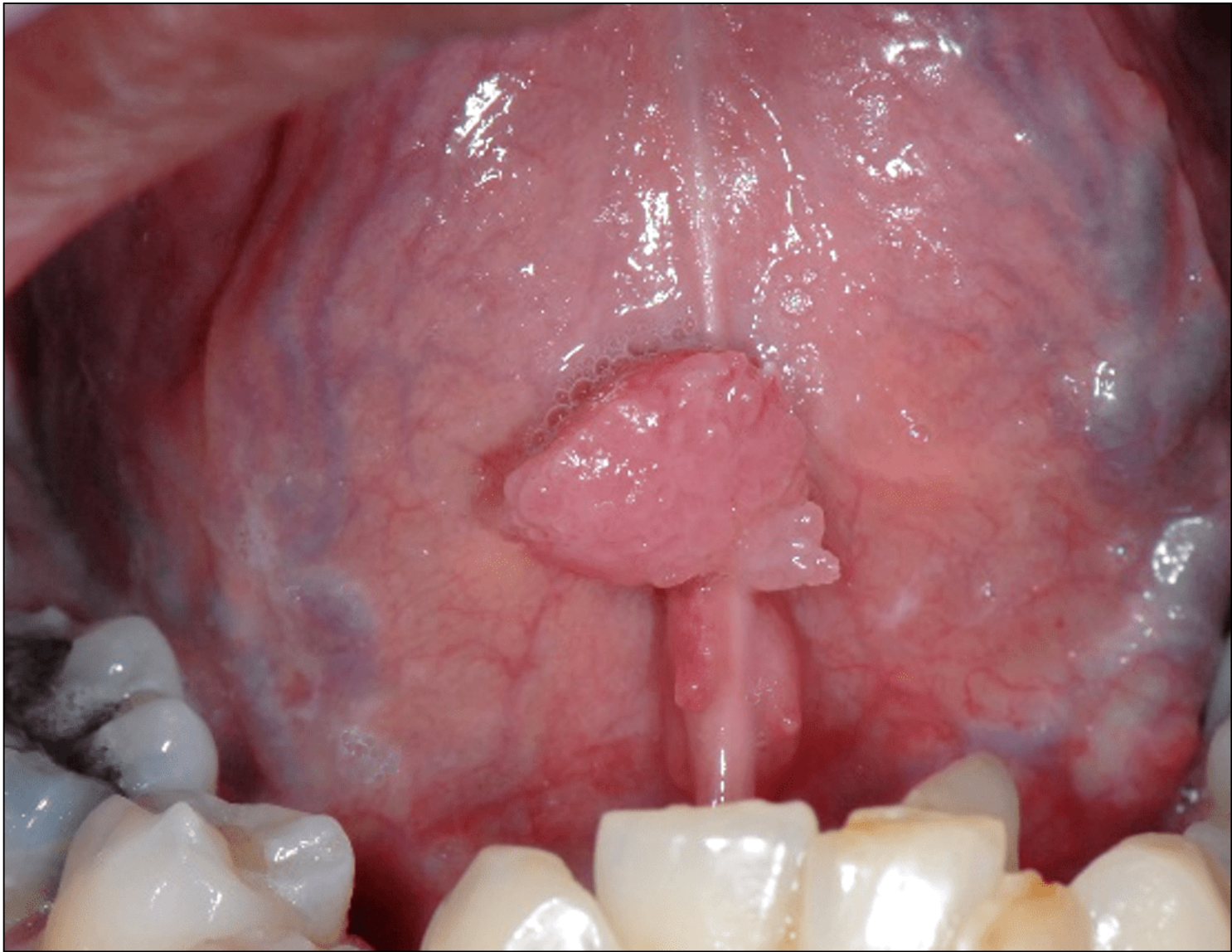

Figure 10 (Image Series) - HPV-Associated Oral Non-Cancerous Lesions
Image 10C: HPV-Associated Oral Focal Epithelial Hyperplasia in Labial Mucosa

Photograph courtesy of Mark Nichols, DDS, Dental Director, South Central AETC

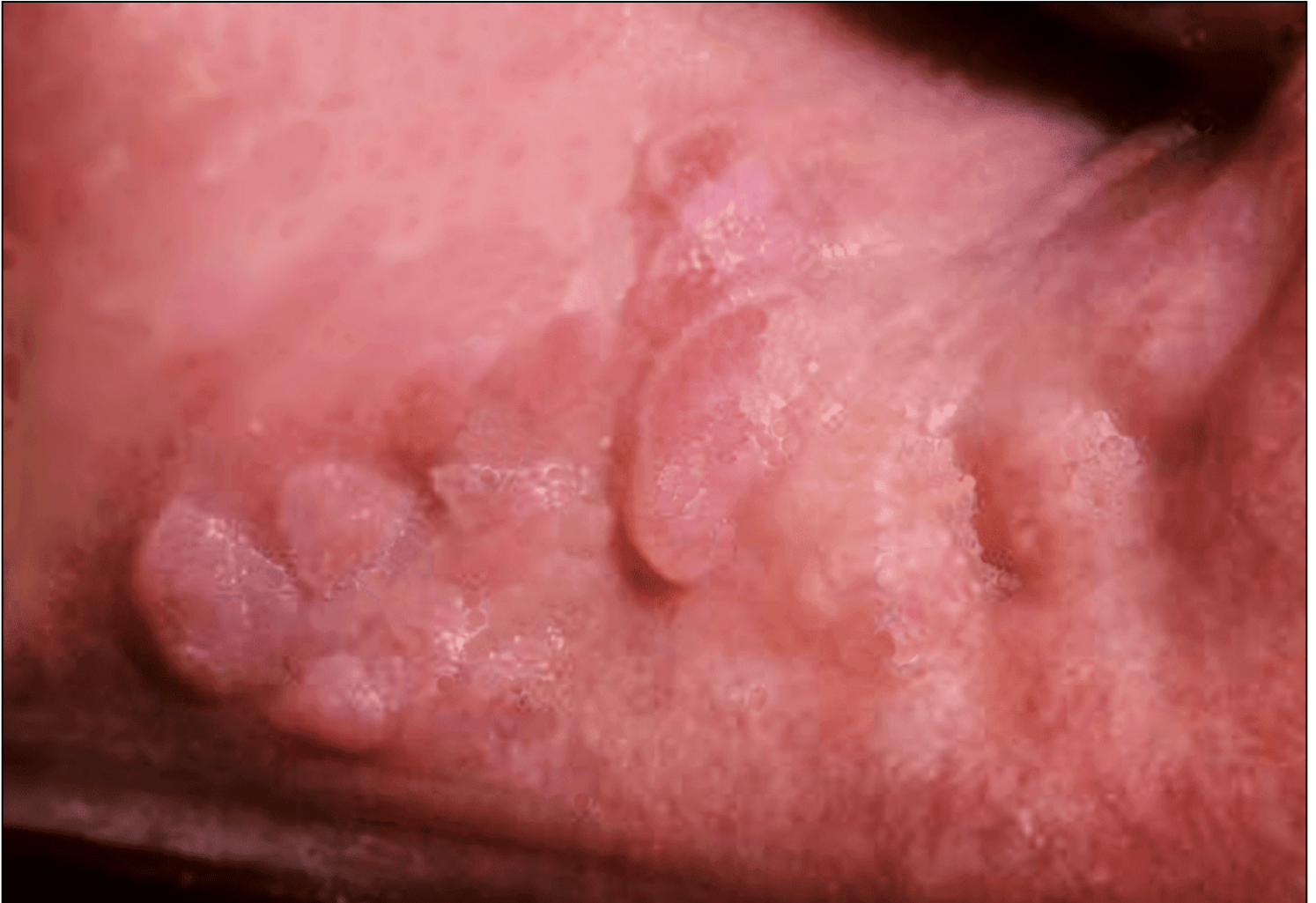

Figure 10 (Image Series) - HPV-Associated Oral Non-Cancerous Lesions
Image 10D: Oral Warts on Upper Gingiva

Photograph from Michael A. Siegel, DDS, MS

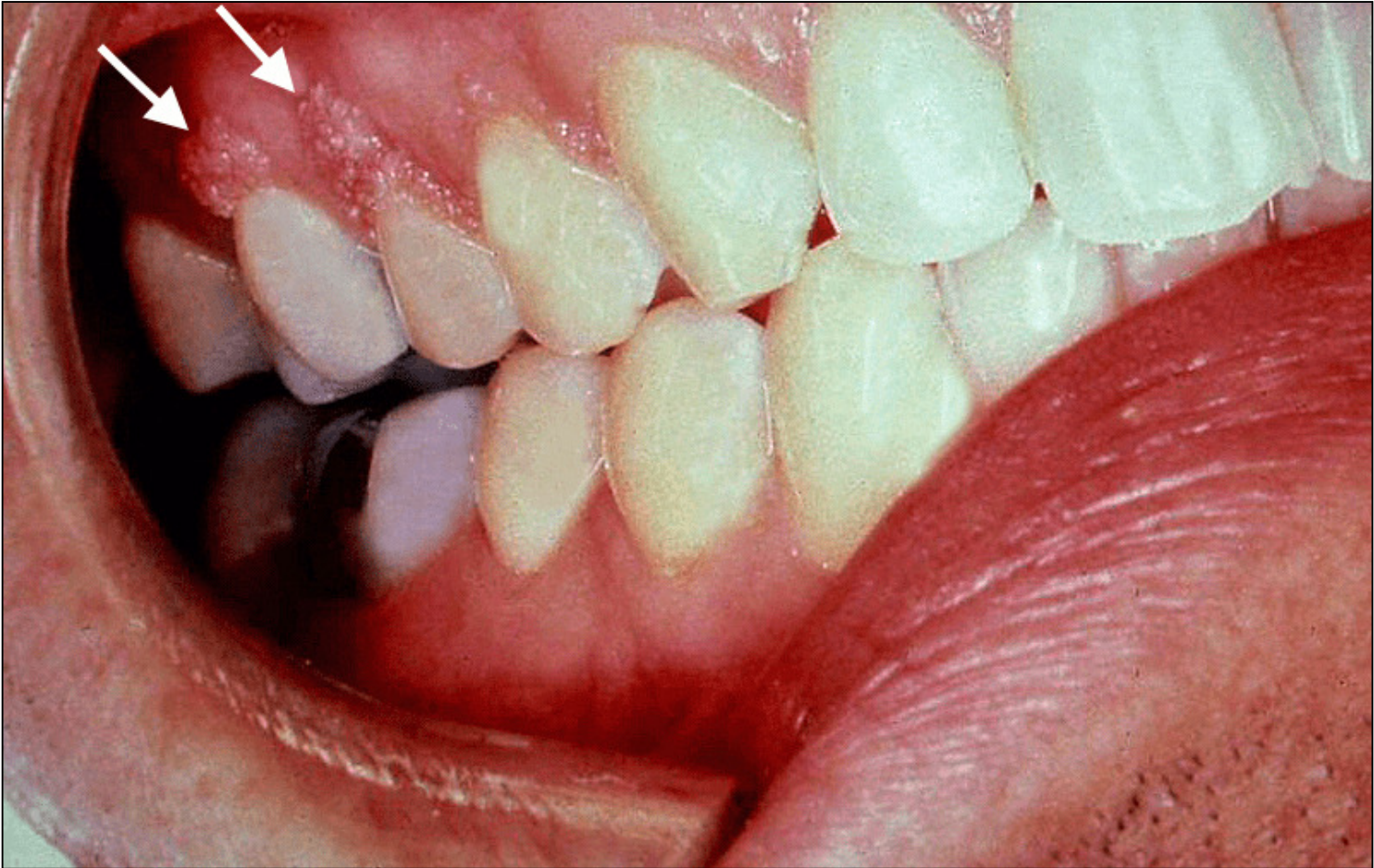


Figure 11 (Image Series) - Oral Dysplasia and Cancer (Image Series) - Figure 11 (Image Series) - Oral Dysplasia and Cancer

Image 11A: Focal Moderate Dysplasia in Lower Gingiva

Photograph courtesy of Fariba S. Younai, DDS, Dental Director, Pacific AETC

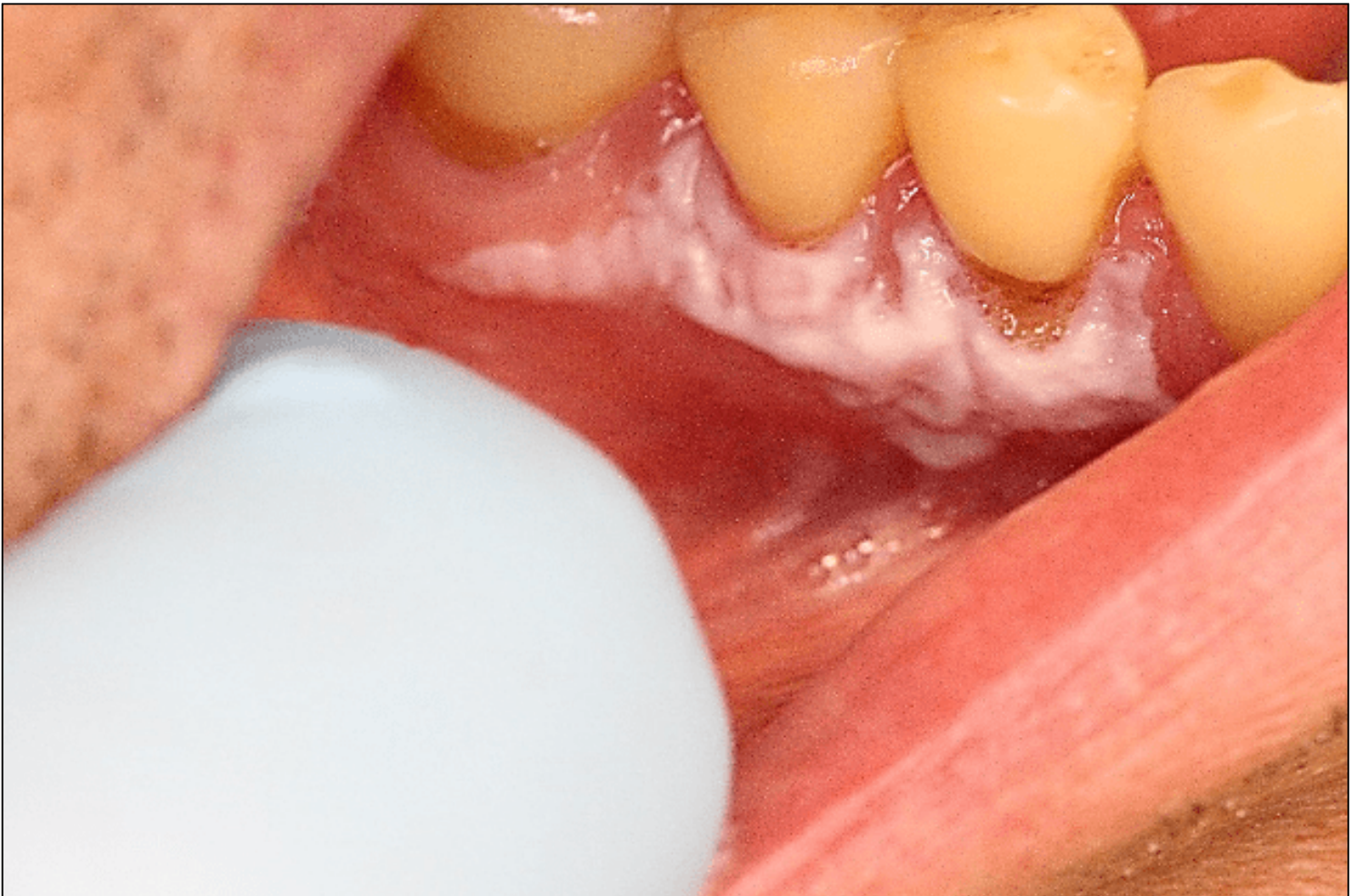

Figure 11 (Image Series) - Oral Dysplasia and Cancer
Image 11B: Diffuse Epithelial Hyperplasia with Mild Dysplasia in Gingiva

Photograph courtesy of Fariba S. Younai, DDS, Dental Director, Pacific AETC

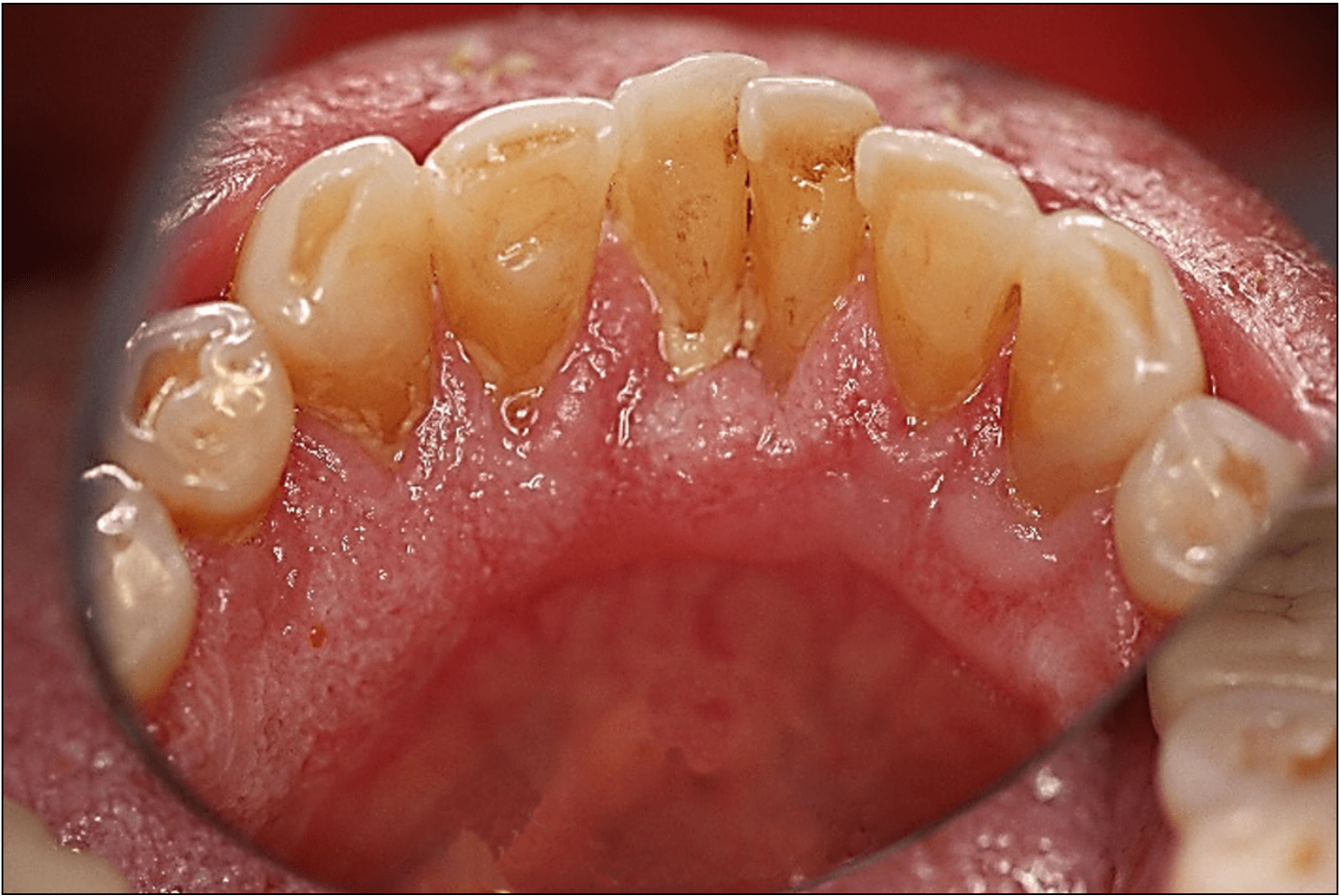

Figure 11 (Image Series) - Oral Dysplasia and Cancer
Image 11C: Focal Severely Dysplastic Lesion in Gingiva

Photograph courtesy of Fariba S. Younai, DDS, Dental Director, Pacific AETC

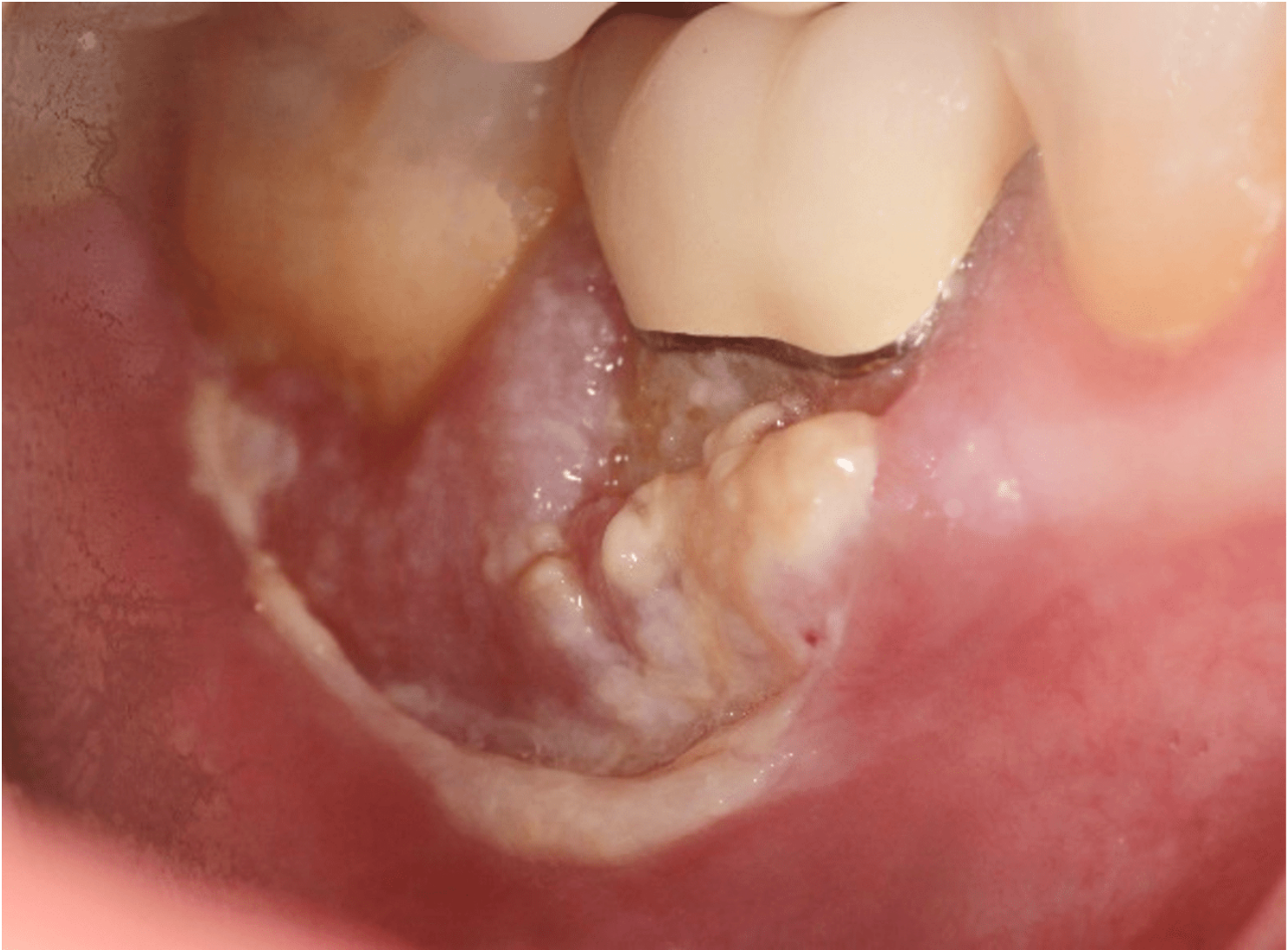


Figure 11 (Image Series) - Oral Dysplasia and Cancer
Image 11D: Oral Squamous Cell Cancer

Photograph courtesy of Mark Nichols, DDS, Dental Director, South Central AETC

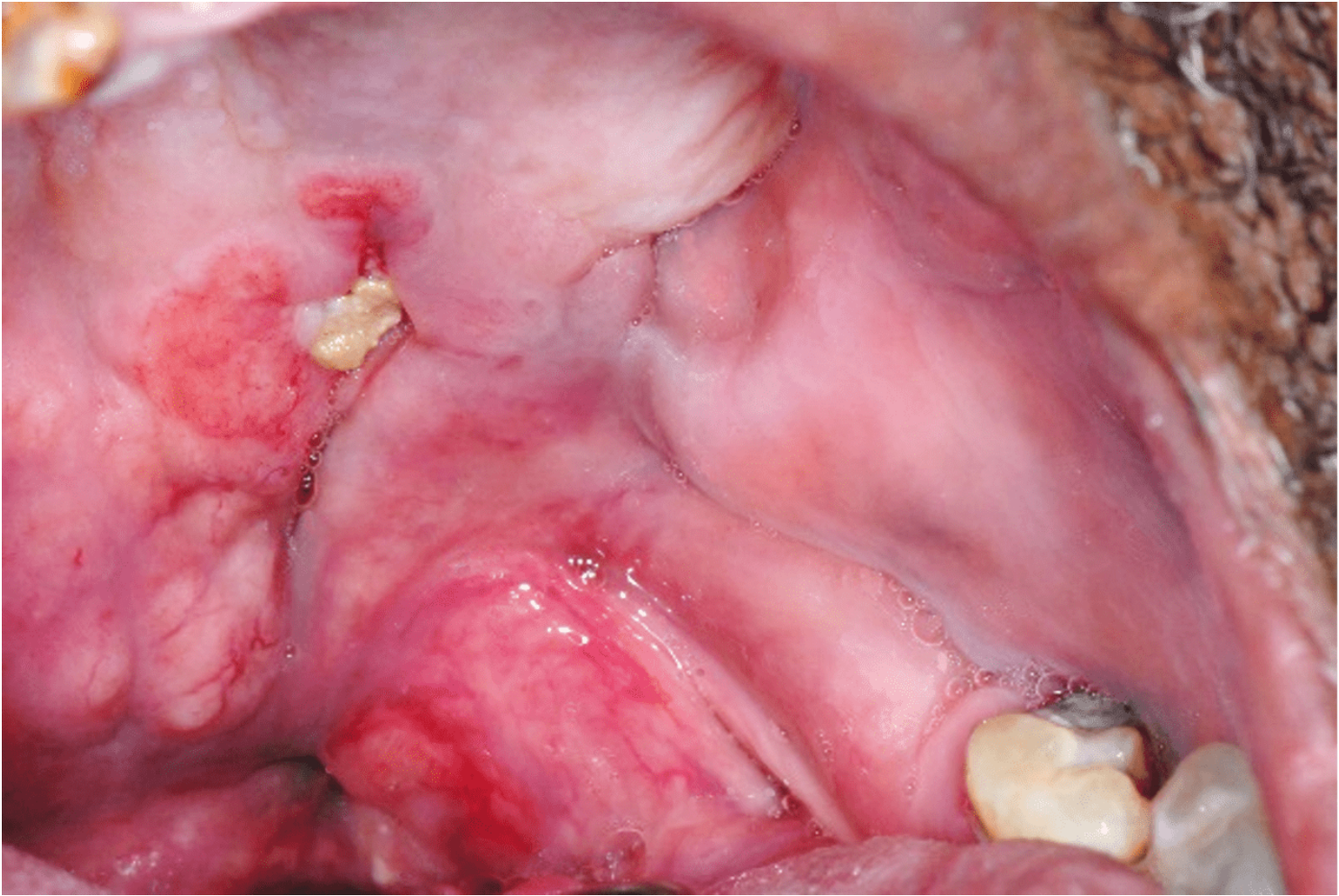


Figure 12 (Image Series) - Oral Mpox Manifestations (Image Series) - Figure 12 (Image Series) - Oral Mpox Manifestations
Image 12A: Oral Mpox with Severe Lip Ulcerations

Photograph from Negusse Ocbamichael, PA-C

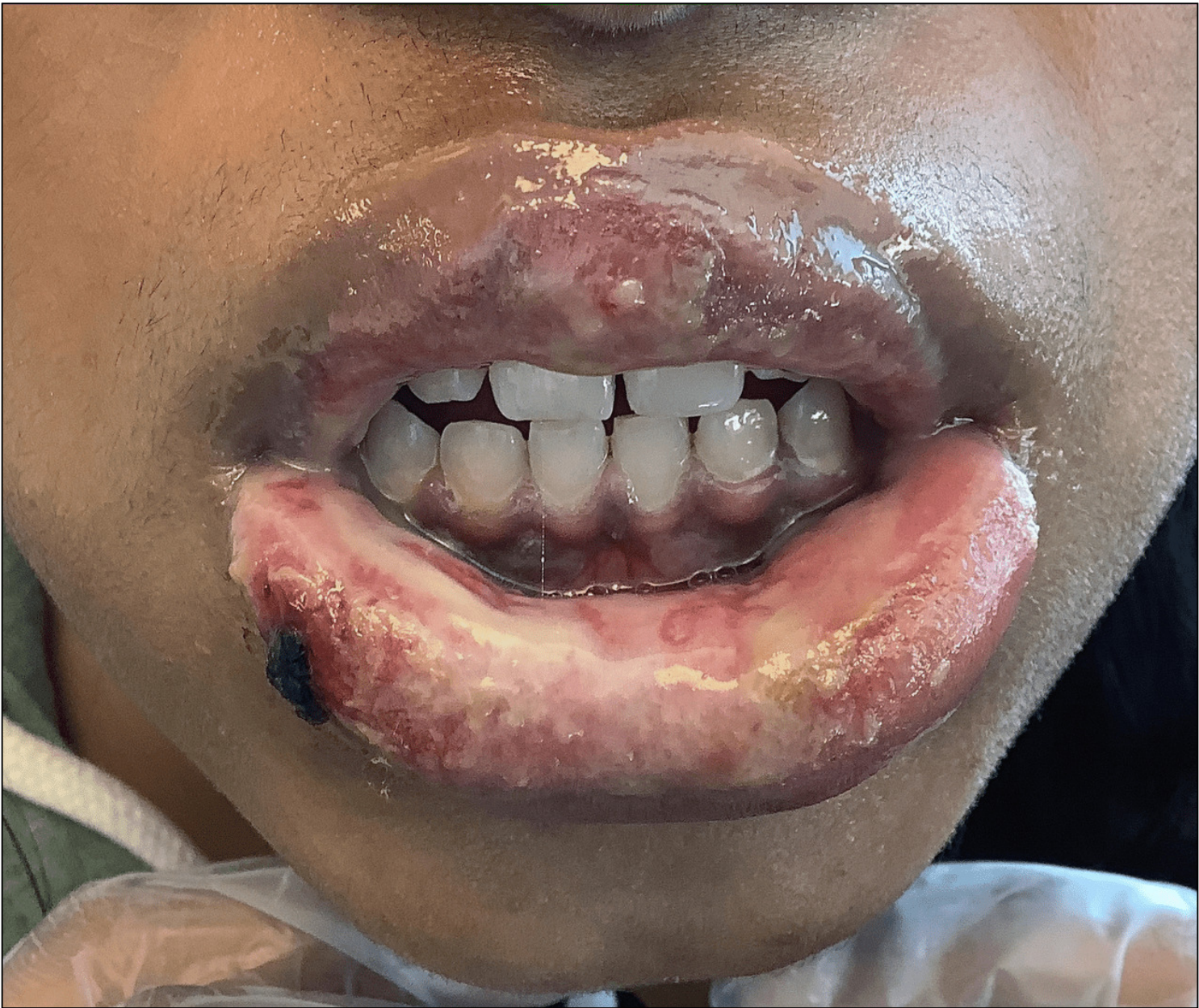

Figure 12 (Image Series) - Oral Mpox Manifestations
Image 12B: Oral Mpox with Ulcer on Palate

Photograph from Negusse Ocbamichael, PA-C

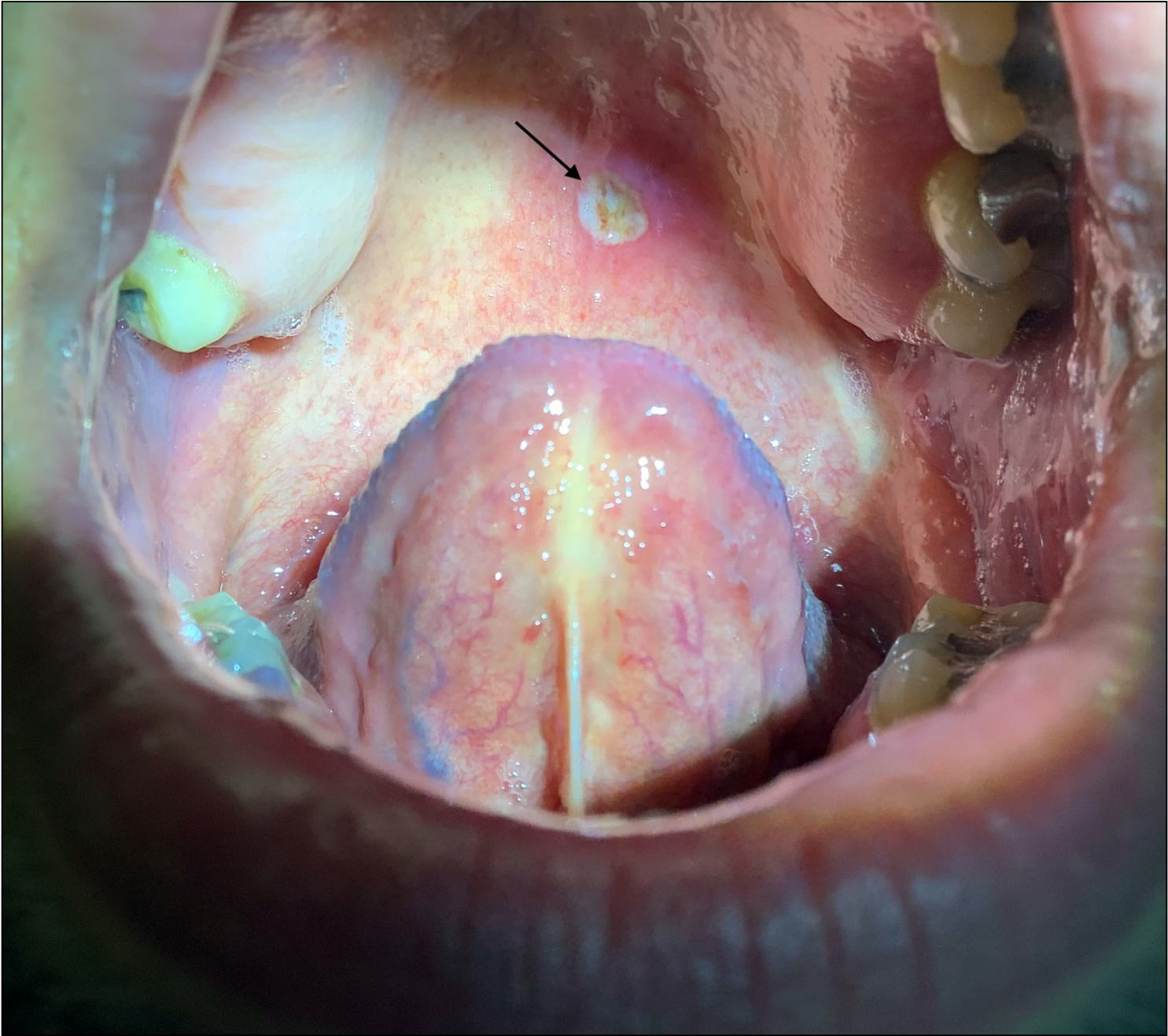
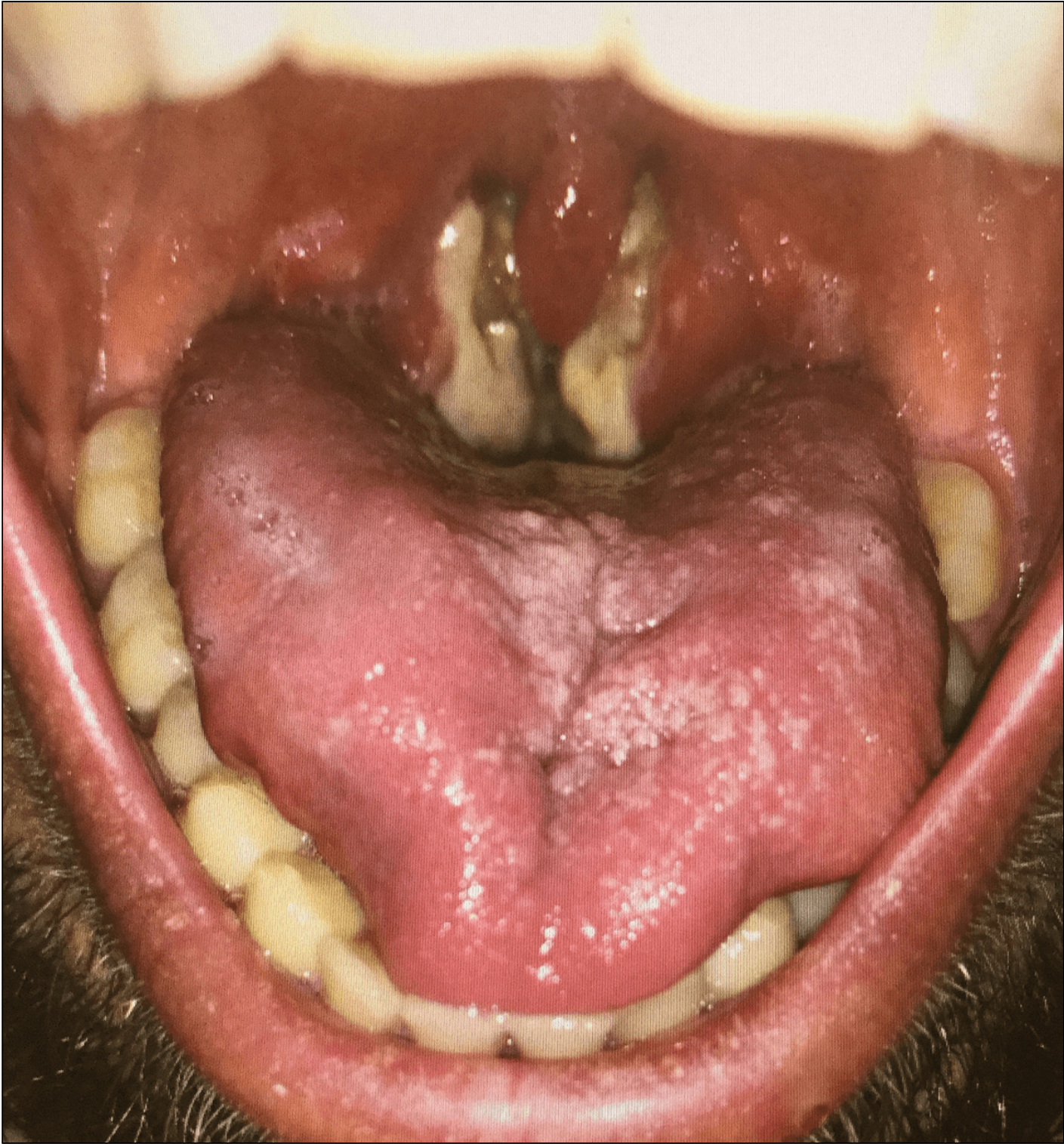

Figure 12 (Image Series) - Oral Mpox Manifestations
Image 12C: Oral Mpox with Tonsillar Edema and Exudate

Photograph from Negusse Ocbamichael, PA-C



<p>Table 1. Guidelines for the Prevention and Treatment of Opportunistic Infections in Adults and Adolescents with HIV</p>
<p>Treatment of Oropharyngeal Candidiasis: Initial Episodes</p>
<p>Preferred Therapy (Duration: 7-14 Days)</p> <ul style="list-style-type: none">• Fluconazole 200 mg load, followed by 100-200 mg PO once daily (AI)
<p>Alternative Therapy</p> <ul style="list-style-type: none">• One miconazole 50-mg mucoadhesive buccal tablet once daily. Apply to mucosal surface over the canine fossa (do not swallow, chew, or crush tablet). Refer to product label for more detailed application instructions (BI), <i>or</i>• One clotrimazole 10-mg troche PO 5 times daily (BI), <i>or</i>• Nystatin suspension 4-6 mL PO 4 times daily (BII), <i>or</i>• Itraconazole oral solution 200 mg PO daily (BI), <i>or</i>• Posaconazole oral suspension 400 mg (10 mL) PO twice daily for 1 day, then 400 mg daily (BI), <i>or</i>• Posaconazole tablet 300 mg PO twice daily for 1 day, then 300 mg daily (BI)
<p>Rating of Recommendations: A = Strong; B = Moderate; C = Optional</p> <p>Rating of Evidence: I = Data from randomized controlled trials; II = Data from well-designed nonrandomized trials, observational cohort studies with long-term clinical outcomes, relative bioavailability/bioequivalence studies, or regimen comparisons from randomized switch studies; III = Expert opinion</p>

Source:

- Panel on Opportunistic Infections in Adults and Adolescents with HIV. Guidelines for the prevention and treatment of opportunistic infections in adults and adolescents with HIV: recommendations from the Centers for Disease Control and Prevention, the National Institutes of Health, and the HIV Medicine Association of the Infectious Diseases Society of America. Candidiasis (mucocutaneous). September 16, 2024. [[HIV.gov](https://www.hiv.gov)]

Table 2. Guidelines for the Prevention and Treatment of Opportunistic Infections in Adults and Adolescents with HIV

Recommendations for Treating Orolabial Herpes Simplex Virus (HSV) Infections

Treating Orolabial Lesions (Duration: 5–10 Days)

- Valacyclovir 1 g PO twice daily (AIII), *or*
- Famciclovir 500 mg PO twice daily (AIII), *or*
- Acyclovir 400 mg PO three times daily (AIII)

Treating Severe Mucocutaneous HSV Infections (AIII)

- Initial therapy acyclovir 5 mg/kg IV every 8 hours
- After lesions begin to regress, change to oral therapy as above.
- Continue treatment until lesions have completely healed.

Chronic Suppressive Therapy

Indications:

- For patients with severe recurrences (AI), including pregnant women, *or*
- Patients who want to minimize the frequency of recurrences (AI), *or*
- To reduce the risk of genital ulcer disease in patients with CD4 cell counts <250 cells/mm³ who are starting antiretroviral therapy (BI)

Treatment:

- Valacyclovir 500 mg PO twice daily (AI), *or*
- Famciclovir 500 mg PO twice daily (AI), *or*
- Acyclovir 400 mg PO twice daily (AI)
- Evaluate ongoing need for suppressive therapy annually

Rating of Recommendations: A = Strong; B = Moderate; C = Optional

Rating of Evidence: I = Data from randomized controlled trials; II = Data from well-designed nonrandomized trials, observational cohort studies with long-term clinical outcomes, relative bioavailability/bioequivalence studies, or regimen comparisons from randomized switch studies; III = Expert opinion

Source:

- Panel on Opportunistic Infections in Adults and Adolescents with HIV. Guidelines for the prevention and treatment of opportunistic infections in adults and adolescents with HIV: recommendations from the Centers for Disease Control and Prevention, the National Institutes of Health, and the HIV Medicine Association of the Infectious Diseases Society of America. Herpes simplex virus. Last updated: May 26, 2020. [[HIV.gov](https://www.hiv.gov)]

